

INSTITUTO BARRAQUER DE AMERICA

Vol. 11 - No. 2

1976

ARCHIVOS  
DE LA  
SOCIEDAD AMERICANA  
DE  
OFTALMOLOGIA Y OPTOMETRIA

SUMARIO

SECUNDUM FORUM OPHTHALMOLOGICUM  
SEGUNDA PARTE

	Página
TECHNICAL ADVANCES IN CORNEAL SURGERY	
J. DRAEGER, M. D. ....	75
CORNEAL TRANSPLANTATION IN HERPETIC KERATITIS	
N. S. C. RICE, M. D. ....	89
COMBINED KERATOPLASTY AND CATARACT EXTRACTION	
ARNOLD I. TURTZ, M. D. ....	93
QUERATOPLASTIA EN CASOS COMPLICADOS	
JOAQUIN BARRAQUER, M. D. ....	99

## A LOS COLABORADORES

Los artículos para publicación, crítica de libros, peticiones de intercambio y otras comunicaciones deben enviarse a: "Redacción Archivos de Sociedad Americana de Oftalmología y Optometría", Apartado Aéreo 0911 Bogotá, 8, Colombia.

Los trabajos originales deben ir acompañados de una nota indicando que no han sido publicados y que en caso de ser aceptados no serán ofrecidos a otras revistas sin consentimiento de la Redacción de la S. A. O. Deben estar escritos a máquina, a doble espacio, en una sola cara, en el tamaño corriente, con un margen de 5 centímetros e ir acompañados de una copia en carbón.

El nombre del autor debe ir seguido de su mayor grado académico colocado a continuación del título del artículo. La dirección completa debe figurar al final del trabajo.

Las ilustraciones deben ir separadas del escrito, numeradas en orden con las leyendas en hojas aparte. El nombre del autor debe ir escrito el reverso de las láminas y en el extremo superior la palabra "Arriba". Los gráficos y esquemas deben ir dibujados con tinta china. Las microfotografías deben indicar el grado de aumento. Las radiografías pueden enviarse en original. Las fotografías de personas reconocibles deben acompañadas de la notificación de poseer autorización del sujeto, si es adulto, o de los parientes si es menor.

La bibliografía debe limitarse a la consultada por el autor para preparación del artículo, ir ordenada y alfabéticamente por el sistema Harvard y abreviada de acuerdo con el World List of Scientific Publication (el volumen en números arábigos subrayado, y la primera página números arábigos):

v. g. SCHEPENS, C. L., (1955) Amer. J. Ophthal., 38,8.

Cuando se cita un libro debe indicarse el nombre completo, editor, lugar y año de la publicación, edición y número de la página:

v. g. RYCROFT, B. W., (1955) "Corneal Grafts" p. 9. Butterworth. London.

Los autores recibirán pruebas de sus artículos para su corrección, y que alteren el contenido del texto serán a su cargo. Los autores recibirán gratuitamente 50 apartes de su artículo. Los apartes adicionales se ministrarán a precio de costo.

Para anuncios comerciales dirigirse a:

Casa Heller, Ltda. Apartado Aéreo 4966. Bogotá - Colombia.

Suscripción para un año:

Colombia:	\$ 150.00
Extranjero:	U.S.\$ 10.00

ARCHIVOS DE LA SOCIEDAD  
AMERICANA DE OFTALMOLOGIA  
Y OPTOMETRIA



INSTITUTO BARRAQUER DE AMERICA

ARCHIVOS  
DE LA  
SOCIEDAD AMERICANA  
DE  
OFTALMOLOGIA Y OPTOMETRIA

---

---

Vol. 11

1976

No. 2

---

---



SECRETARIO GENERAL:  
FRANCISCO BARRAQUER C., M. D.

SECRETARIO DE REDACCION:  
SALOMON REINOSO A., M. D.

APARTADO AEREO 091019  
BOGOTA. (8) - COLOMBIA

## SECUNDUM FORUM OPHTHALMOLOGICUM

Lunes 17 a viernes 21 de marzo de 1975  
Bogotá — Colombia

**PRESIDENTE DE HONOR:**

PROF. JULES FRANCOIS  
GANTE, BELGICA

**INVITADO DE HONOR:**

PROF. RAUL RODRIGUEZ BARRIOS  
MONTEVIDEO, URUGUAY

**JUNTA LOCAL**

**DIRECTOR EJECUTIVO:**

Dr. JOSE I. BARRAQUER

**SECRETARIO EJECUTIVO:**

Dr. ZOILO CUELLAR-MONTOYA

**SECRETARIO DE PUBLICACIONES:**

Dr. SALOMON REINOSO

**TESORERO:**

Dr. Carlos Téllez

**SESIONES CIENTIFICAS:**

Dr. FRANCISCO BARRAQUER

**T. V. Y PROYECCIONES:**

Dr. IGNACIO BARRAQUER  
Dr. FEDERICO SERRANO  
Dr. ALEJANDRO ARCINIEGAS

Dra. OLGA WINZ DE WILDE  
Dra. MONSERRAT CARULLA DE LONDOÑO  
Dr. HUGO MERINO  
Sr. FRANCISCO MUNERA

SECUNDUM FORUM OPHTHALMOLOGICUM

SESIONES QUIRURGICAS:

Dr. ANGEL HERNANDEZ  
Dra. CARMEN BARRAQUER  
Dr. JOSE MARIA SILVA

INSCRIPCIONES:

Dr. HERNANDO HENAO  
Dr. HARTMUT WEBER  
Dra. MARTA PACHON  
Dr. ORLANDO ANGULO  
Dr. PEDRO GAMARRA

RECEPCION:

Dr. HARTMUT WEBER  
Dr. LUIS F. RESTREPO CUARTAS  
Dr. FABIAN MARTINEZ  
Dr. CLAUDIO JUCHEM  
Dr. RENE JIMENEZ  
Dr. JOSE MIGUEL VARAS TORRES  
Dr. JULIO ROJAS  
Dr. CONSTANTINO GARCIA  
Dr. LUIS FERNANDO DA SILVEIRA  
Dr. EDUARDO LUJAN  
Dr. FULGENCIO ALEMAN

RELACIONES PUBLICAS:

Dr. JAIME TELLEZ  
Dr. ALVARO CALDERON  
Dr. IGNACIO BARRAQUER  
Dr. DANIEL GAMBOA

EVENTOS SOCIALES:

Dr. ENRIQUE ARIZA  
Dr. JOSE MARIA SILVA  
Dr. FRANCISCO MONTOYA  
Dr. HERNANDO CAMACHO

PROTOCOLO:

Dr. JAIME TELLEZ  
Dr. ADOLFO DE FRANCISCO  
Dr. JORGE MARTINEZ

EXPOSICION COMERCIAL:

Sr. RAFAEL ALVAREZ  
Sr. FRANCISCO VIDALLER

JUNTA DE SEÑORAS:

Sra. MARGARITA COLL DE BARRAQUER

ALOJAMIENTO Y TRANSPORTE:

EXPRINTER  
Cra. 6ª N° 14-64.  
Bogotá, Colombia.

## SECUNDUM FORUM OPHTHALMOLOGICUM

### SEGUNDA PARTE

#### TECHNICAL ADVANCES IN CORNEAL SURGERY

**Prof. Dr. J. DRAEGER**

**(Bremen)**

A long while ago use of the microscope was adopted for suturing in corneal surgery. There is no doubt that our surgical technique was improved a great deal by better optical control. In corneal graft the incision is the most delicate procedure, most important for the later result of the operation. Nevertheless so long the microscope was not used for this difficult and dangerous phase of the operation. So long there was not appropriate technical solution to allow optical control of the trephination. The usual manual trephine could not be used under the microscope. Due to its shape there was no good optical control of the cornea or the anterior chamber while the incision was performed. Even when observing in an oblique direction less than half of the blade or of the diameter of the incision is visible (Fig. 1).

**Fig. 1:** Manual trephine, oblique observation, only partial optical control.

Therefore our intention was to construct a new instrument which could be used under the microscope with perfect optical control. (Fig. 2).

**Fig. 2:** Rotor trephine, cross section.

A very low tube with a very thin wall of only 0,8 mm. thickness allows to overlook more than 90% of the cornea through the microscope while the incision is performed. Also illumination is no problem. To keep the hands off the surgical field remote control and electric drive were indispensable. The whole instrument is handsome and compact. (Fig. 3).

**Fig. 3:** Rotor trephine with handle.

Trephine, handle and even the cable can be sterilized. (Fig. 4).

**Fig. 4:** Rotor trephine, handle, motor, gear and trephine.

The blade easily can be exchanged for sharpening. All sizes from 1 to 11 mm. diameter are available (Fig. 5).

**J. DRAEGER**

**Fig. 5:** Rotor trephine, blade disconnected.

By means of a flexible cable the instrument is connected to the swivel arm of the microsurgical unit. (Fig. 6).

**Fig. 6:** Cable connection to microsurgical unit.

The speed easily can be controlled from the panel of the unit like all other electrical functions. (Fig. 7).

**Fig. 7:** Electrical control for RPM.

By use of different gears the torque can be adapted to different demands. The gear ratio can be changed from 1:11, 1:41 or even to 1:141.

Remote control by foot pedal helps to avoid vibration. (Fig. 8).

**Fig. 8:** Foot control.

The surgeons hand is relieved from cutting. It only has to guide the instrument under permanent optical control. (Fig. 9).

**Fig. 9:** Rotor trephine, cutting under the microscope.

**Fig. 10:** Rotor trephine, cutting recipient's eye cornea.

Small holes in the lateral wall of the trephine centrifuge the aqueous from the corneal surface after having entered the anterior chamber, (fig. 11).

**Fig. 11:** Rotor trephine, drainage holes.

So that the incision in many cases can be completed without stopping the blade around the whole circumference (fig 12).

**Fig. 12:** Vertical wound edges.

This leads to a perfect shape of the wound edges which are straight and vertical. Due to the same shape in donor and recipient coaptation is no longer a problem, which means better woundhealing, better optical results. (Fig. 13).

**Fig. 13:** Vertical wound edges.

Trephines with different diameters easily can be exchanged and used with the same handle. (Fig. 14).

**Fig. 14:** Rotor trephine, different diameters.

Also a little rotor keratome, connected to the same handle, is available for small incisions. (Fig. 15).



#### TECHNICAL ADVANCES

**Fig. 15:** Rotor Keratome, perplacing incision for later air injection.

This keratome also cuts almost without any pressure transmitted to the tissue which especially is helpful in very soft eyes for instance in perforating injuries to prepare an incision for a later air injection to reform the anterior chamber.

So long even more difficult as for perforating graft was the use of the microscope for lamellar graft. Most of the instruments used for a lamellar keratectomy were not suitable for use under the microscope.

It is the merit of José Ignacio Barraquer to have developed a most precise automatic lamellar keratome for use with his keratomileusis and keratophakia operations. This instrument is most ingenious and perfect. But only a few places can afford to use such a perfect but as well expensive instrument. However for simple use with the microscope we constructed a small handsome instrument, which can be applied with the same type of rotor handle as the keratome for perforating graft (Fig. 16).

**Fig. 16:** Lamellar Microkeratome, total view.

The blade is cutting horizontally with high speed, also transmitting almost no pressure to the tissue, which, is even more important in lamellar incision. (Fig. 17).

**Fig. 17:** Lamellar Microkeratome, front part.

A vacuum ring, which is connected to the high vacuum pump of the microsurgical unit fixes the instrument to the globe. Two micrometers control the diameter and the thickness of the lamellar graft, which can be taken with the same instrument as well from the recipient's as from the donor's eye. (Fig. 18).

**Fig. 18:** Lamellar Microkeratome, vacuum ring, guide and rotary blade.

This little instrument is especially useful as it can be applied under the microscope for better optical control of this difficult phase in lamellar grafting. Automatically equal and smooth grafts of any desired thickness can be obtained. (Fig. 19).

**Fig. 19:** Lamellar keratome, donor graft.

J. DRAEGER

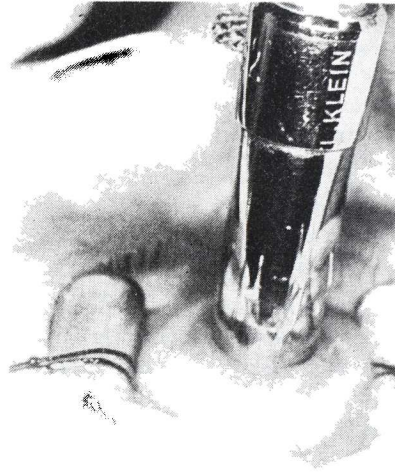


FIGURE 1  
*Manual trephine, oblique observation,  
only partial optical control.*

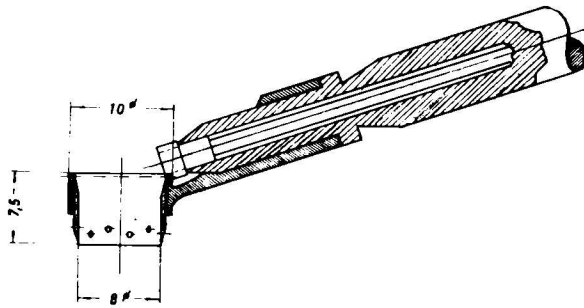


FIGURE 2  
*Rotor trephine, cross section.*

TECHNICAL ADVANCES

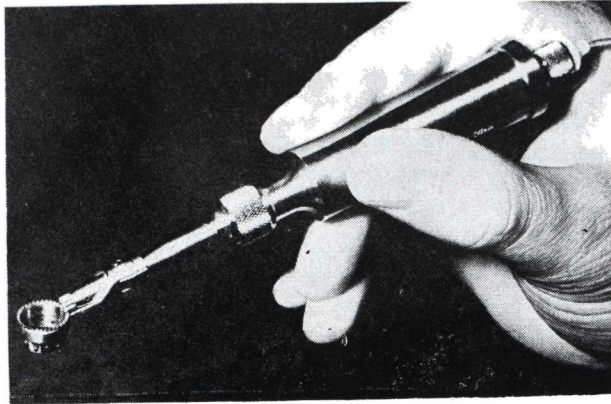


FIGURE 3  
*Rotor trephine with handle.*

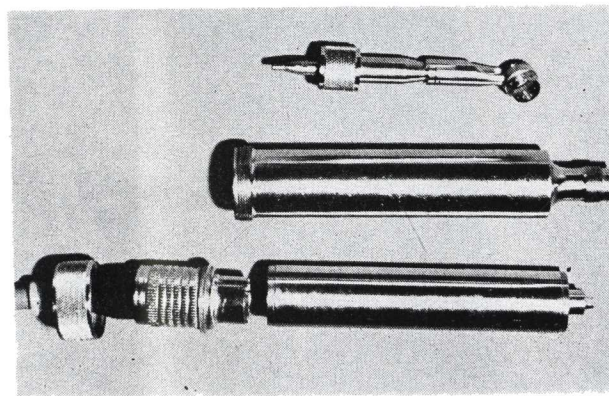


FIGURE 4  
*Rotor trephine, handle, motor, gear and trephine.*

J. DRAEGER




FIGURE 5

*Rotor trephine, blade disconnected.*

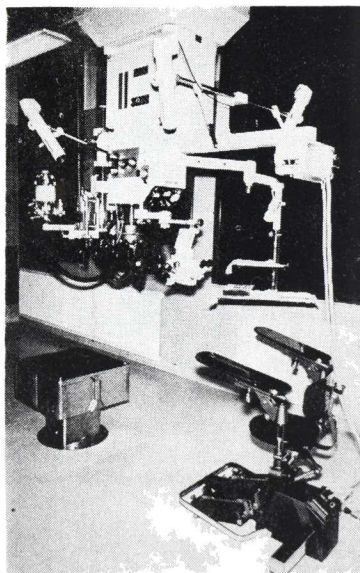


FIGURE 6

*Cable connection to microsurgical unit.*

TECHNICAL ADVANCES

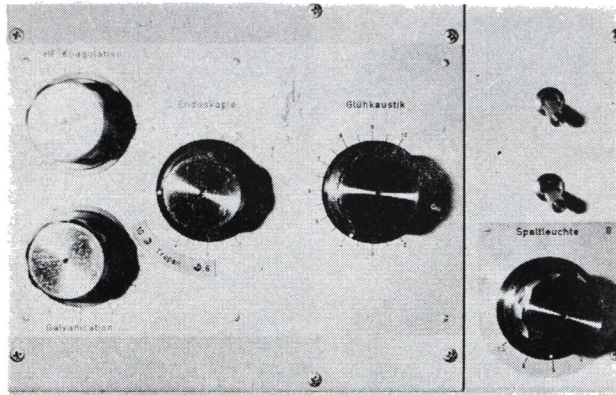


FIGURE 7  
*Electrical control for RPM.*

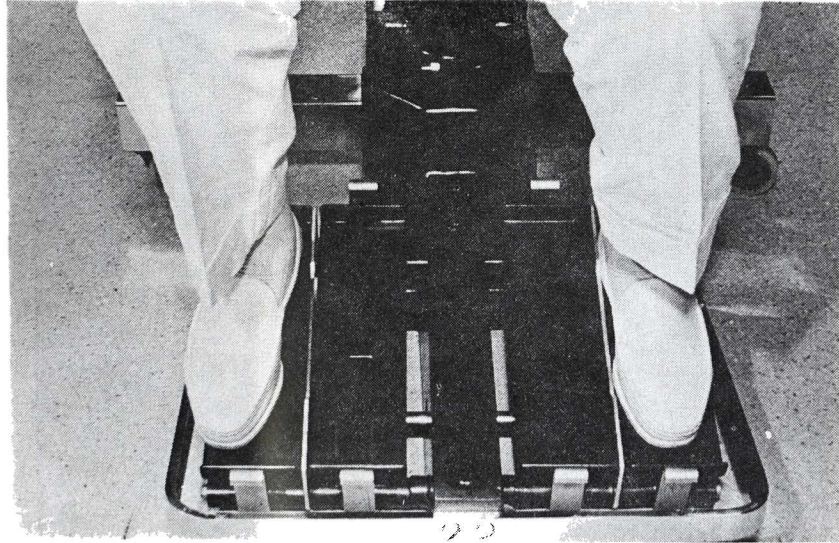


FIGURE 8  
*Foot control.*

J. DRAEGER

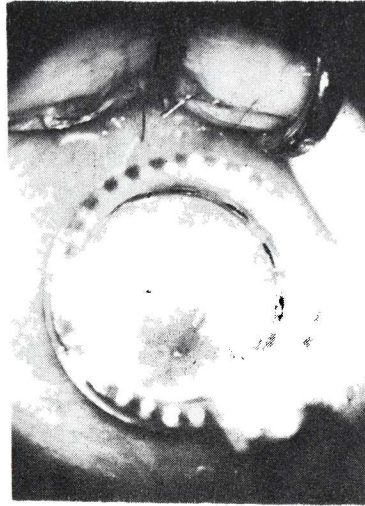

FIGURE 9  
*Rotor trephine, cutting under the  
microscope.*

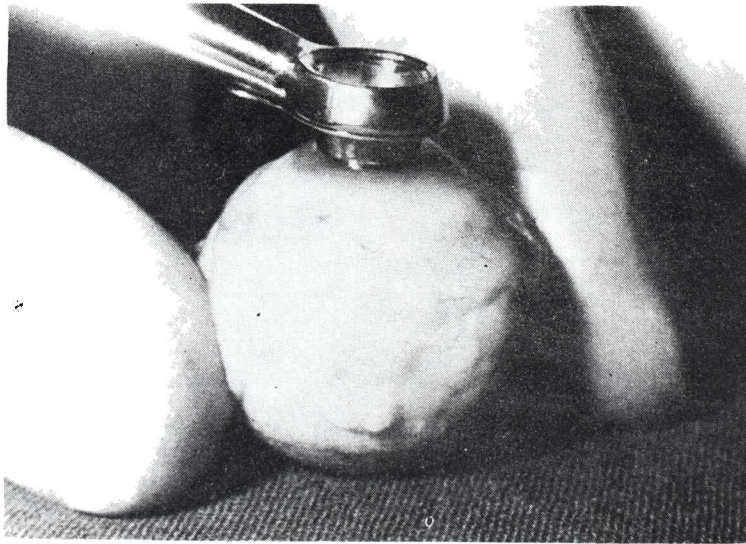


FIGURE 10  
*Rotor trephine, cutting recipient eye cornea.*

TECHNICAL ADVANCES

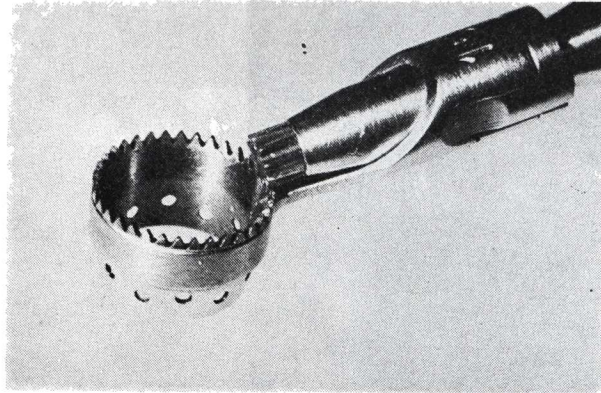


FIGURE 11

*Rotor trephine, drainage holes.*

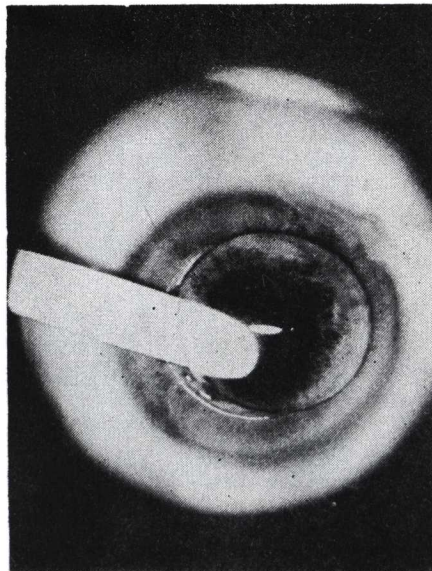


FIGURE 12

*Vertical wound edges.*

J. DRAEGER

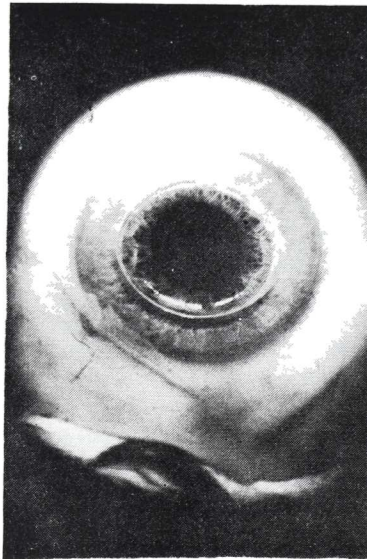


FIGURE 13  
*Vertical wound edges.*

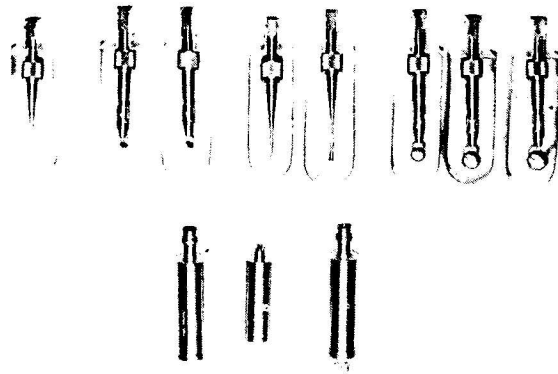


FIGURE 14  
*Rotor trephine, different diameters.*



TECHNICAL ADVANCES

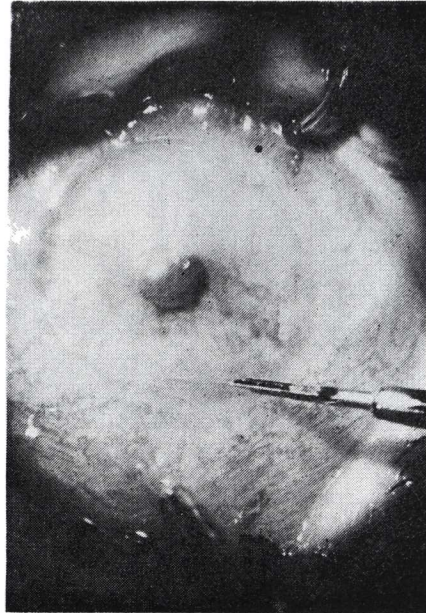


FIGURE 15  
*Rotor keratome, preplacing incision  
for later air injection.*

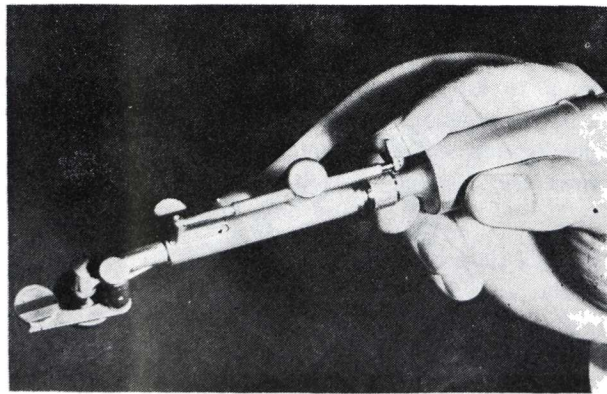


FIGURE 16  
*Lamellar keratome, total view.*

J. DRAEGER




FIGURE 17  
*Lamellar keratome, front part.*

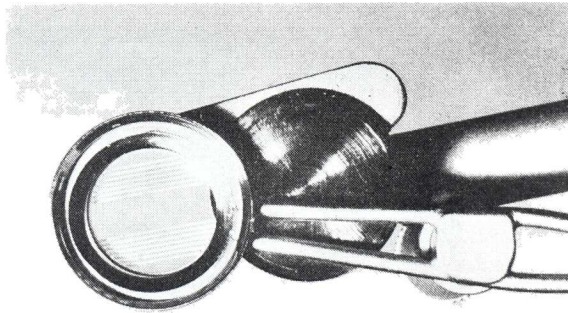


FIGURE 18  
*Lamellar keratome, vacuum ring, guide and rotary blade.*

#### TECHNICAL ADVANCES

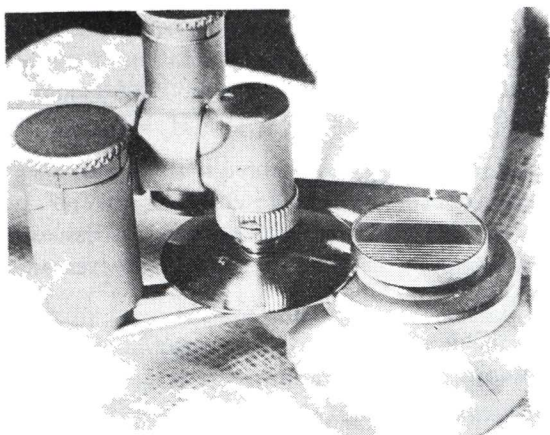


FIGURE 19

*Lamellar keratome, donor graft.*

#### SUMMARY

In this paper, the advantages and functioning of a new rotating trephine developed by the author, are presented. This trephine allows the surgeon to perform a corneal trephination under optical control during the course of keratoplasties. Up to the present this had been impossible using common trephines, due to their shape.

One of these trephines is designed for penetrating keratoplasties and consists basically of a very low and thin (8 mm.) tube, where the blade is mounted, permitting an optical control of 90% of the field through the microscope while the corneal incision is performed. The unit consists of 3 parts.

The first is a rotating trephine, copled to the handle and to a small motor in an upward and slanted way; this allows the surgeon to keep his

**J. DRAEGER**

hands off the operating field. The motor is actioned by a foot pedal and its revolutions may be controlled. The trephine has holes to centrifuge the ocuous humor during the trephination, making possible to perform a perfect and complete cut of well defined edges, both in the donor and in the host eye, helping to attain an excellent coaptation of the edges, resulting in optimal results in the postoperative period. Trephines of different diameters may be coupled to this unit.

A small rotating keratome may be adapted to this motor also, to perform small incisions used to reform the anterior chamber with air, since, due to its high speed, this keratome does not press over the tissues, facilitating thus the procedure, especially in cases of hypotonous eyes and eyes with penetrating wounds.

The whole unit, including its cable, may be sterilized and connected to the arm of the microsurgical unit.

Another instrument is designed for lamellar keratoplasties. Dr. José I. Barraquer developed an automatic microkeratome for his keratophakia and keratomileusis operations, but this ingenious and perfect instrument is at the reach of only a few surgeons. The author has adapted his lamellar instrument (to be used under microscope) to be coupled to the same unit for penetrating keratoplasties. A pneumatic ring, connected to the vacuum pump of the microsurgical unit, helps to fix the keratome to the ocular globe, and two micrometers control the diameter and depth of cut. A high speed blade which allows a horizontal cut, permits obtaining very clean grafts of the same size and thickness for better results in lamellar keratoplasties.

**P. N. G.**

## CORNEAL TRANSPLANTATION IN HERPETIC KERATITIS

By **N. S. C. RICE**  
(London — England)

The uncertain prognosis for corneal transplantation in herpetic eyes, well known to corneal surgeons, is hardly surprising for the very nature of herpetic disease is of recurrent inflammation of unpredictable periodicity and severity; furthermore, the available therapeutic agents, both anti-viral and anti-inflammatory, are of only limited efficacy.

A recent retrospective study on corneal grafts in herpetic eyes has led to some observations which have practical clinical application (Rice & Jones, 1973).

### 1. Penetrating corneal grafts

#### a) Incidence of allograft reaction:

In a series of 57 penetrating grafts, it was found that 58% developed oedema of the graft and uveitis; this complication appeared within the first 6 post-operative months in most cases, although it was seen as late as 6 years after surgery. It was somewhat commoner in those eyes which had clinically active disease at the time of surgery (64%) as compared to those which were clinically inactive (54%). The majority of cases were characterized by the appearance on the graft of a typical endothelial rejection line as described by Khodadoust and Silverstein (1969); this is pathognomonic evidence of an allograft reaction and unquestionably explains the oedema of the graft in such cases. In a minority of cases the graft became uniformly oedematous, without the appearance of an endothelial rejection line: although it is not possible to be certain of the mechanism in these cases, it would seem likely that they are also a manifestation of the allograft reaction, but mediated across the anterior chamber

**N. S. C. RICE**

rather than via the corneal blood vessels. The prompt recognition of the allograft reaction and the immediate institution of intensive topical cortico-steroid therapy resulted in half the cases responding and achieving clear grafts.

The cause of this very high incidence of allograft reaction in herpetic eyes is still speculative, but it does explain the uncertain and variable results of penetrating grafts in herpetic eyes. The lesson to the clinician is clear: these cases require the most careful, frequent and prolonged supervision following penetrating keratoplasty and awareness by the surgeon of the high incidence of graft reactions in these cases can lead to its early recognition and treatment and the salvaging of half the grafts.

It is noteworthy that just under 80% of the 50 eyes in this study achieved clear, penetrating grafts, although 10% required more than one graft.

**b) Recurrence of herpetic epithelial keratitis:**

Recurrence of active herpetic epithelial disease in the form of dendritic or amoeboid ulcers occurred in 9% of the penetrating grafts in this series. In all cases the lesions healed in response to topical anti-viral therapy (I.D.U.) and in no case did such lesions prejudice the outcome of the graft. This recurrence rate, which appears to be lower than the natural rate, is surprising, particularly as all these eyes received prolonged and often intensive cortico-steroid for at least 9 months post-operatively. It has led us to the conclusion that routine prophylactic anti-viral therapy is not indicated in the post-operative management of herpetic eyes following penetrating keratoplasty: indeed, I.D.U. is undoubtedly toxic to the corneal epithelium and we have seen cases in which graft failure appears to have been directly related to I.D.U. toxicity.

**c) The rôle for therapeutic penetrating keratoplasty:**

In 22 eyes penetrating keratoplasty was performed when the herpetic kerato-uveitis was active. In most cases the disease was recurrent and the inflammation had been present for many months without resolution on medical therapy; in 2 eyes the cornea had perforated. Sixty-eight percent of these grafts were clear and 2 of the failures subsequently achieved a clear re-graft, so that 77% of these eyes ultimately achieved clear grafts. These results are almost identical with those obtained in eyes which were

## CORNEAL TRANSPLANTATION

clinically quiet at the time of surgery, i.e. 68% of first grafts were clear and 79% of eyes ultimately achieved clear grafts. These encouraging results of penetrating grafts in eyes with active herpetic disease have led us to conclude that therapeutic penetrating keratoplasty can have a valuable place in the treatment of some severely infected eyes.

### 2. Lamellar keratoplasty

#### a) Recurrence of stromal keratitis:

Of 17 cases in which lamellar keratoplasty was performed 11 (65%) developed recurrence of stromal inflammation. This usually appeared to start in the host cornea deep to the lamellar graft and showed a strong tendency to spread and involve the graft; a severe, necrotising keratitis developed in some cases. This high rate of recurrent stromal disease has led us to conclude that lamellar keratoplasty has little, if any, place in the treatment of herpetic keratitis.

It is noteworthy that out of 18 eyes which had received preparatory lamellar grafts, only 8 (44%) subsequently achieved clear penetrating grafts. These figures do not support the concept of preparatory lamellar keratoplasty prior to penetrating keratoplasty in herpetic eyes.

#### b) Recurrence of epithelial keratitis:

Recurrence of epithelial disease occurred in 35% of cases following lamellar keratoplasty, a significantly higher figure than that for penetrating keratoplasty. There is no obvious explanation for this difference.

## REFERENCES

1. Rice, N. S. C. and Jones, B. R. (1973): Problems of corneal grafting in herpetic keratitis. *Corneal Graft Failure. Ciba Foundation Symposium*, p. 221.
2. Khodadoust, A. A. and Silverstein, A. M. (1969): Transplantation and rejection of individual cell layers of the cornea. *Invest. Ophthalmol.*, **8**, 180.

N. S. C. RICE

SUMMARY

The prognosis for corneal grafts practiced in herpetic eyes is uncertain due to the nature of the affection and to the limited efficiency of the drugs.

In a retrospective study of corneal grafts in herpetic eyes, the following conclusions were reached:

1. **With penetrating keratoplasties**

a) Total rejection of the graft. In a series of 57 penetrating keratoplasties it was found that 58% of the cases developed edema of the graft and uveitis. Most of the cases presented a line of endothelial rejection and total edema in the graft, but early diagnosis and intensive treatment with corticoids improved the prognosis.

b) Relapse of herpetic keratitis. In 9% of grafts there is a relapse of herpetic keratitis. In all of the cases there was a healing response after treatment with antivirals (IDU), with no sequels. However, IDU must not be used as a prophylactic since its toxicity leads to opacity of the graft.

c) The role of therapeutic penetrating keratoplasty. In 22 eyes in which penetrating keratoplasties with active keratouveitis were practiced (where in most cases the affection was a relapse), it was found that 68% of the grafts were clear. This percentage was the same as in grafts performed in tranquile eyes.

2. **With lamellar keratoplasties**

a) Recurrence of stromal keratitis. From 17 cases in which a lamellar keratoplasty was performed, 65% developed a recurrence of stromal inflammation. The relapse begins in the host stroma and involves the graft. There have also appeared necrotising keratitis.

CONCLUSION: The operation must not be performed.

b) Relapse of epithelial keratitis. It occurs in 35% of cases of lamellar keratoplasty.

CONCLUSION: The operation must not be performed.

P. G.



## COMBINED KERATOPLASTY AND CATARACT EXTRACTION

**ARNOLD I. TURTZ, M. D.**

(New York — U. S. A.)

The surgical approach to patients with corneal pathology and cataract requires thoughtful consideration. The surgeon must decide whether keratoplasty or cataract extraction alone might sufficiently benefit his patient as to make the other unnecessary. Many elderly patients such as these with developing cataracts have had corneal opacities since infancy which despite their appearance are not inconsistent with acceptable vision if the cataract should be removed. On the other hand it is often difficult to estimate the density of a cataract viewed through a semiopaque cornea. Keratoplasty alone may suffice, or subsequent cataract extraction can be required. The past history and the course of recent visual loss must be carefully evaluated. Cataract may accompany any type of corneal pathology requiring keratoplasty but many of the patients presenting this problem suffer from Fuch's Dystrophy since both reach their highest incidence in the elderly.

If both keratoplasty and cataract extraction are deemed necessary there are three choices, keratoplasty following cataract extraction, keratoplasty preceding cataract extraction or simultaneous surgery.

Authors in the past cautioned against penetrating keratoplasty in the presence of aphakia. In 1955 Paton advised deferring cataract extraction till after keratoplasty, and in 1958 Castroviejo felt that aphakic keratoplasty was not likely to be successful. In 1964, however, Fine reported a 65% success rate in keratoplasty for aphakic bullous keratopathy, and subsequent reports have indicated that refined surgical technique, the use of the operating microscope, ocular hypotensive agents, improved instrumentation and suture materials, have altered the prognosis favorably. Success rates up to 95% have been achieved. Nevertheless keratoplasty in the

ARNOLD I. TURTZ

presence of aphakia remains a more difficult and hazardous procedure due to the presence of iris and vitreous corneal adhesions often vascularized, secondary glaucoma and a tendency for post-operative shallow anterior chamber and vitreous touch syndrome.

Vitreotomy has been helpful in obtaining clear grafts in the presence of aphakia but unfortunately the visual acuity does not always parallel graft clarity. In some series of cases with up to 80% graft clarity only 40 to 50% achieved vision of 20/70 or better. The newer mechanical vitreous infusion suction cutters may improve surgical results, but it is important to remember that uveitis, vitreitis, late vitreoretinal traction phenomena and secondary glaucoma are not innocuous and may result in functional deterioration of the globe. This eye suffered corneal laceration with avulsion of iris and lens. The initial repair followed by subsequent penetrating keratoplasty resulted in 20/25 vision. Some aphakic grafts do very well and others very poorly. This eye has intractible glaucoma. Although this graft remains clear vitreoretinal traction has caused cystoid macular disease.

Cataract extraction after keratoplasty is also associated with some risk. Previously successful grafts may become edematous and fail following subsequent cataract surgery. The graft endothelium may be injured by mechanical trauma or by a delayed onset allograft reaction due to post-operative inflammation. Authors generally agree that any subsequent intra-ocular surgery poses a threat to graft clarity. Although results have improved perhaps 20% of clear grafts can be expected to fail after cataract extraction despite all surgical precautions and appropriate waiting periods. This eye suffered a corneal burn with perforation by molten metal. 20/40 vision was restored by penetrating keratoplasty followed by cataract extraction. This previously clear graft has had persistent peripheral edema for three years following cataract extraction. Another graft has become totally edematous and opaque. In this case cataract extraction was followed by a severe late graft rejection which fortunately responded well to graft replacement seen here at six months and two years post-operatively.

In view of the hazards and difficulties, the lost time, the long wait for useful vision particularly in an elderly individual with limited life expectancy, and the late failures which occur regularly in the two-stage procedures, one is tempted by a combined procedure and corneal surgeons appear to be turning increasingly toward simultaneous surgery. Some authors have warned of greater inherent risks, but success rates of 80%

#### COMBINED KERATOPLASTY

and better have been reported and this may be expected to improve with technical advances.

The combined procedure is indicated for cases of Fuch's Dystrophy and cataract when sufficient corneal and lens pathology exist to suggest that both procedures will be necessary. It is often indicated when an opaque graft and cataract are present particularly when anterior synechiae and a shallow anterior chamber coexist. Trauma involving the cornea and lens often mandates simultaneous surgery. Blind, elderly or poor risk patients and keratoplasty candidates with aphakic fellow eyes might also benefit.

This patient had bilateral corneal scarring and cataracts. Her right eye had penetrating keratoplasty followed by cataract extraction one year later. Her left eye did equally well with combined keratoplasty and cataract extraction. This eye suffered a central corneal laceration and traumatic cataract. Simultaneous graft and cataract extraction was performed. This patient had bilateral combined procedures for cataract and Fuch's Dystrophy.

Keates described an extracapsular technique designed to maintain a capsulozonular barrier to prevent operative vitreous loss and post-operative vitreocorneal complications. This irrigation-aspiration technique as well as other extracapsular techniques including phaco-emulsification and the Katzin Hydropulse procedures illustrated in these post-operative photographs may make simultaneous surgery less hazardous and more effective.

Preoperative ocular hypotensive agents and digital compression reduce the operative risk. The pupil should be dilated.

Some form of scleral support such as the Flieringa ring is important. The use of alpha chymotrypsin facilitates intracapsular cataract extraction and does not increase operative risk. One or more peripheral iridectomies must be performed and a water tight closure is imperative. Vitrectomy is indicated only if vitreous is lost or continues to bulge through the trephination. Excision of vitreous should continue until one achieves a concave vitreous pseudoface behind the iris plane.

Local antibiotics, steroids and mydriatics are begun after the first dressing. Diamox is prescribed routinely to control secondary glaucoma which commonly occurs.

ARNOLD I. TURTZ

**Summary:**

The combination of cataract with corneal pathology warranting keratoplasty places the patient in some jeopardy. There is risk involved in both separate and simultaneous procedures. Where minimal pathology exists in either cornea or lens the surgery should be directed toward the elimination of the other problem. When significant changes are present in both locations simultaneous surgery offers an equally safe feasible and more practical solution for the patient.

There are three surgical procedures in cases of corneal pathology and cataract:

- 1 — Keratoplasty preceding a cataract extraction.
- 2 — Keratoplasty following a cataract extraction.
- 3 — Simultaneous cataract surgery and keratoplasty.
  1. In cataract extractions following a keratoplasty the following problems may arise: A clear graft may become edematose due to an inflammatory reaction or endothelial trauma. This shows that any intraocular surgery may produce changes in the graft.
  2. In keratoplasties performed in aphakic eyes there are complications due to its associate pathology. Such complications may include: corneal adherences of iris and vitreous, very often vascularized, secondary glaucoma, and a tendency to a shallow anterior chamber. When a vitrectomy was performed in these patients, it helped to obtain clear grafts. There was no relation between the transparency and the visual acuity because in only 40-50% of cases where the transparency of the graft was 80% the visual acuity reached 20/70.
  3. In view of the difficulties inherent to the mentioned procedures, such as loss of time, a long waiting period to obtain acceptable vision, and technical errors, it has been decided to perform the combined cataract and keratoplasty surgery. This procedure is indicated in cases of Fuchs, dystrophia and cataract, in those cases in which the graft is not clear and simultaneously there is

#### COMBINED KERATOPLASTY

a cataract, and in traumas involving cornea and lens. During surgery, hypotension agents and digital compression must be used; the pupil must be dilated and a filtering ring must be placed and, in some cases, alfachimotripsine must be applied. One or two iridectomies, followed by a vitrectomy (according to the case) must be performed. Antibiotics and mydiatics are applied topically simultaneously with treatment with corticoids to avoid the secondary ocular hypertension which usually takes place.

P. G.

## QUERATOPLASTIA EN CASOS COMPLICADOS

**JOAQUIN BARRAQUER, M. D.**

(Barcelona — España)

Señor presidente, colegas y amigos:

Biológicamente la gran diferencia entre los trasplantes de córnea y los de otros tejidos estriba en el escaso poder antigénico de aquella y su carencia de vasos sanguíneos, lo que explica el éxito de los homoinjertos corneales mucho antes que en otras ramas de la cirugía.

El pronóstico de las queratoplastias mejora de día en día, gracias a una serie de perfeccionamientos:

- Anestesia, preferentemente general.
- Antibióticos.
- Esteroides anti-inflamatorios.
- Inmunodepresores (Imurán).
- Refinamiento del instrumental.
- Trépanos muy cortantes.
- Agujas muy finas y punzantes.
- Material de sutura muy fino e inerte.
- Empleo del microscopio operatorio.

Es de capital importancia:

- Selección del injerto en excelentes condiciones de viabilidad.
- Indicación operatoria adecuada.
- Mejor conocimiento de la patogenia de las complicaciones, lo que permite su profilaxis así como un mejor tratamiento.

#### JOAQUIN BARRAQUER

En queratoplastia laminar es fundamental que la disección sea suficientemente profunda para alcanzar un lecho sano y que éste sea muy regular para conseguir una buena adaptación entre el injerto y el receptor. En todo momento debe evitarse profundizar excesivamente y penetrar en la cámara anterior.

El uso del microscopio quirúrgico con lámpara de hendidura es fundamental para realizar las maniobras con la mayor precisión.

Con la queratoplastia laminar podemos eliminar opacidades superficiales, normalizar el espesor y la curvatura en córneas adelgazadas o deformadas, tratar "en caliente" queratitis resistentes al tratamiento médico y corregir defectos refractivos. En esta última indicación se incluyen las técnicas de J. I. Barraquer, queratomileusis y queratofaquia.

En queratoplastia penetrante es de capital importancia el empleo de trépanos impecables, para obtener un tallado muy nítido y de bordes cilíndricos. El diámetro debe ser suficiente para alcanzar córnea periférica de espesor normal. Tanto en el globo receptor como en el dador, el trépano debe aplicarse perpendicular al plano del iris para que el tallado quede vertical y cilíndrico. Así la coaptación será más fácil y el astigmatismo menor.

El trépano de motor eléctrico es muy ventajoso para obtener una incisión correcta. El modelo fabricado por la casa Grieshaber permite utilizar trépanos de todos los diámetros, tiene diferentes velocidades (entre 12 y 65 r. p. m.) pesa poco y es fácil de manejar. Se pone en marcha y se para instantáneamente mediante un pedal, lo que deja al cirujano las dos manos libres para centrar el trépano y mantenerlo perpendicularmente durante todo el tallado.

Suturas. Los nuevos materiales de sutura permiten dejar la sutura "in situ" durante 3 - 6 - 9 meses hasta que la cicatrización sea muy firme. Esto es de capital importancia en el queratocono y en general cuando existe vascularización corneal.

Los adelantos técnicos y medicamentosos hacen posible hoy día una serie de buenos resultados en casos en que antes la queratoplastia era de un pronóstico muy reservado. Vamos a presentar unos casos al respecto.

Queratotoro, córnea muy adelgazada (Fig. 1 a, b). Vemos en la fotografía con hendidura toda la córnea adelgazada, pero además con una curvatura muy irregular que provoca un astigmatismo de  $-17$  dioptrías, im-

### QUERATOPLASTIA EN CASOS COMPLICADOS

posible de corregir, con cristales o con lentes de contacto. Vemos en la figura 2 a, b, el resultado 2 meses después de practicar una queratoplastia laminar de 10 mm. de diámetro y 0.4 de profundidad. La Fig. 3 a, b, muestra el resultado 5 años después de la operación. Las 17 dioptrías de astigmatismo se convirtieron en 0.75 y quedó una miopía de 6 dioptrías. V. = 0'5 - N° 1 - TG = 16 mm. Hg. Por tanto, gran valor de la queratoplastia laminar reconstructiva para estos casos que teniendo las capas profundas transparentes, con una disección interlaminar muy regular puede obtenerse un buen resultado óptico y, por lo tanto, sumamente satisfactorio.

Ectasia marginal de Terrien (Fig. 4 a, b). En la fotografía con hendidura observamos que la córnea está tan adelgazada, que en nuestras manos no creímos posible realizar una queratoplastia laminar reconstructiva. Se practicó una queratoplastia penetrante en forma de "creciente" (Fig. 5). La Fig. 6 a, b, muestra el resultado 1 año después. El paciente antes de ser operado tenía un astigmatismo de - 20 dioptrías con la córnea adelgazada y peligro de perforación. Después de la intervención quedó con - 7 dioptrías de astigmatismo, V. = 0'5 N° 1 TG. = 13 mm. Hg.

Ectasia marginal de Terrien circunferencial (Fig. 7 a, b). En este caso tampoco juzgamos posible hacer una queratoplastia laminar, dado el gran adelgazamiento y ectasia. En la Fig. 8 podemos observar la topografía del espesor corneal. La zona con rayado corresponde a un espesor de 5 centésimas a 1 décima de milímetro. En la parte central (zona punteada) el espesor es casi normal. En este caso practicamos una homoqueratoplastia anular penetrante reconstructiva de 13 mm. de diámetro y en su centro una autoqueratoplastia óptica de 6'1 mm. de diámetro.

La Fig. 9 representa la técnica de la intervención (complicada y larga) con 4 iridectomías periféricas, con colgajo conjuntival de base fornix cubriendo todos los puntos corneo-esclerales y el autoinjerto fijado en el centro del homoinjerto con una sutura borde a borde de seda virgen y una sutura continua de Perlon.

La Fig. 10 corresponde a 3 semanas después de la intervención. Se ve el autoinjerto transparente y el homoinjerto velado. En la Fig. 11 a, b, vemos el resultado a las 4 semanas; en él se ve claramente un edema en el homoinjerto; en cambio el autoinjerto continúa transparente, pero con precipitados en su endotelio. Existe gran hiperemia y comienza la neovascularización del homoinjerto; se instituye "ipso facto" una terapéutica con



JOAQUIN BARRAQUER

Imurán a razón de 1 mg. por kilo de peso, practicando hemograma, pruebas hepáticas y renales cada 15 días. El paciente pesaba 100 kilos y se le administraron 100 mgs. de Imurán al día. Con este derivado de la Mercaptopurina se logró solucionar el problema. En la Fig. 12, a, b, 2 meses después de iniciar este tratamiento, vemos que el ojo está ya muy tranquilo, ha desaparecido de la gran inyección vascular, la córnea homoinjerto está menos edematosa y el autoinjerto se mantiene muy transparente. Con la hendidura podemos ver las diferencias de espesor: el homoinjerto está algo engrosado pero permite una excelente transparencia del autoinjerto, y no hay tendencia a la vascularización. La Fig. 13 a, b, ilustra el resultado definitivo y la Fig. 14 la topografía de espesores. Creo interesante presentar esta técnica que, si bien es muy laboriosa, permite la práctica de una autoqueratoplastia en el centro de una homoqueratoplastia con las indudables ventajas de aquella.

La distrofia de Fuchs cuando está muy avanzada constituye un problema. En la Fig. 15 a, b, vemos una queratoplastia opacificada y en la 16 a, b, el ojo compañero del mismo paciente, al que le habían practicado una iridectomía, "llamada óptica". Vemos que la distrofia de Fuchs en el ojo que vamos a operar era enorme y con alteración hasta la periferia. Sin embargo, se practicó una queratoplastia penetrante de 9.1 mm. de diámetro con extracción simultánea de la catarata (Fig. 17 a, b). En la fotografía con hendidura podemos ver la córnea de espesor normal y la hialoides íntegra. El resultado final se ilustra en la Fig. 18 a, b. Visión: 0.8 - N° 1; TG: 12 mm. Hg.

Glaucoma operado 4 veces (Fig. 19 a, b), glaucoma maligno, afaquia complicada vítreo enclavado, estafilomas ciliares, cámara anterior estrecha, iris muy alterado. Seidel positivo, TG = 40 mm. Hg. V. = 0,15 ( $160^\circ + 12 + 6$ ).

El ojo derecho de la misma paciente, ciego por glaucoma pero con córnea en buen estado (Fig. 20 a, b).

Se practicó autoqueratoplastia penetrante de 14 mm. de diámetro. La Fig. 21 ilustra la obtención del autoinjerto conjuntivo-esclero-corneal y la Fig. 22 la sutura del autoinjerto, después de la resección de la córnea, iris y estafilomas. Para cohibir la hemorragia se empleó la diatermia bipolar.

En la Fig. 23 a, b, vemos el resultado final un año después de la operación. V. = 0.2 ( $105^\circ + 2 + 14$ ), TG = 12 mm. Hg. Es interesante ima-

#### QUERATOPLASTIA EN CASOS COMPLICADOS

ginar por qué mecanismo se ha normalizado la tensión ocular (Obsérvese asimismo que el astigmatismo preoperatorio era de 12 dioptrías y el postoperatorio de 2 dioptrías).

Por último presentamos un paciente con queratitis recidivante que acudió a nuestra consulta con toda la córnea alterada, muy infiltrada y con descemetocele periférico a punto de perforar (Fig. 24 a, b). El otro ojo era ciego por perdigón intraocular con una córnea perfectamente transparente (Fig. 25). En este caso practicamos una autoqueratoplastia de 13 mm. de diámetro con colgajo conjuntival y con un reborde de esclerótica. La Fig. 26 ilustra el resultado postoperatorio inmediato y la Fig. 27 el resultado a los 15 días.

En la Fig. 28 vemos el resultado definitivo un año después de la operación.  $V = 0.8 (80^\circ - 2'25) = 0.95$ , N° 1 TG = 14 mm. Hg. En la Fig. 29 vemos el ángulo camerular y las iridectomías periféricas muy basales.

De estos casos presentados queremos destacar que con la autoqueratoplastia hemos podido resolver 3 casos sumamente complicados.

JOAQUIN BARRAQUER

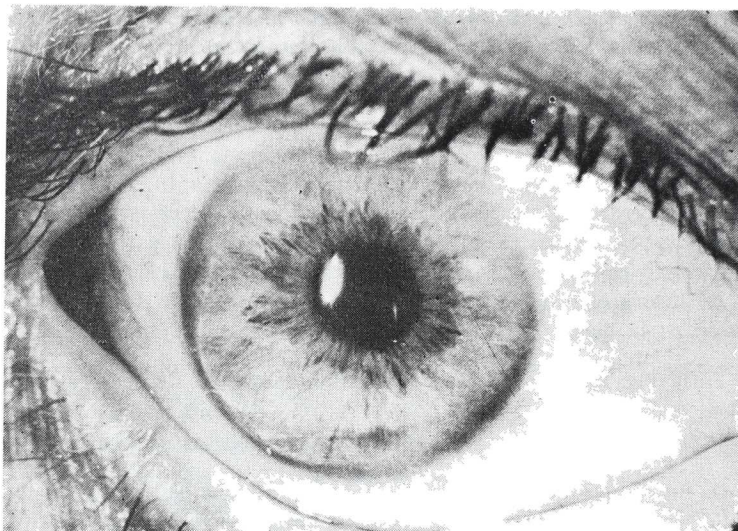


FIGURA 1 a

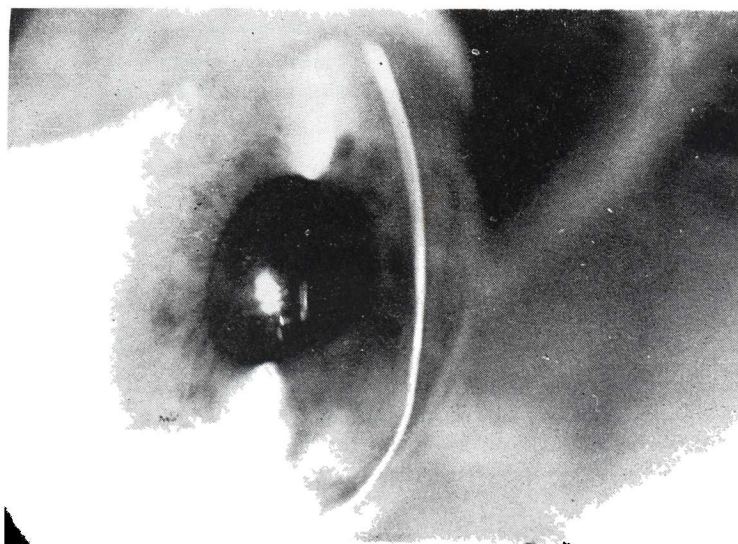


FIGURA 1 b

QUERATOPLASTIA EN CASOS COMPLICADOS

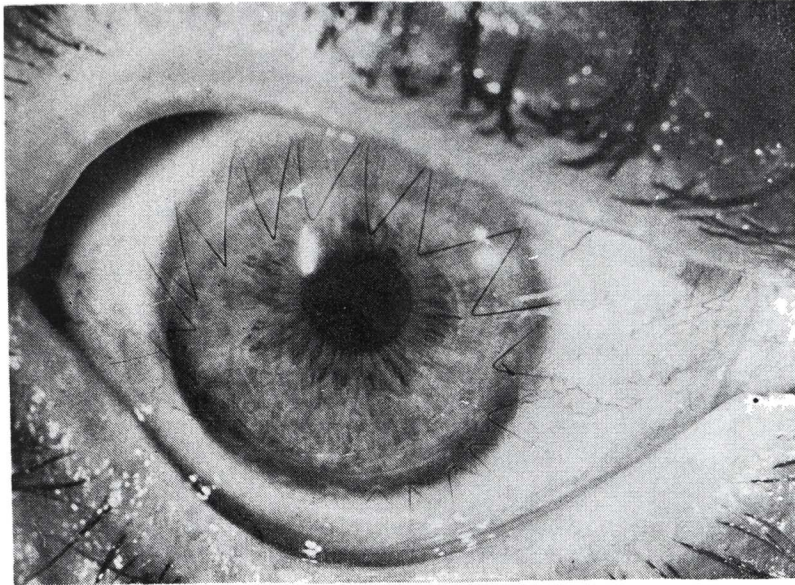


FIGURA 2 a

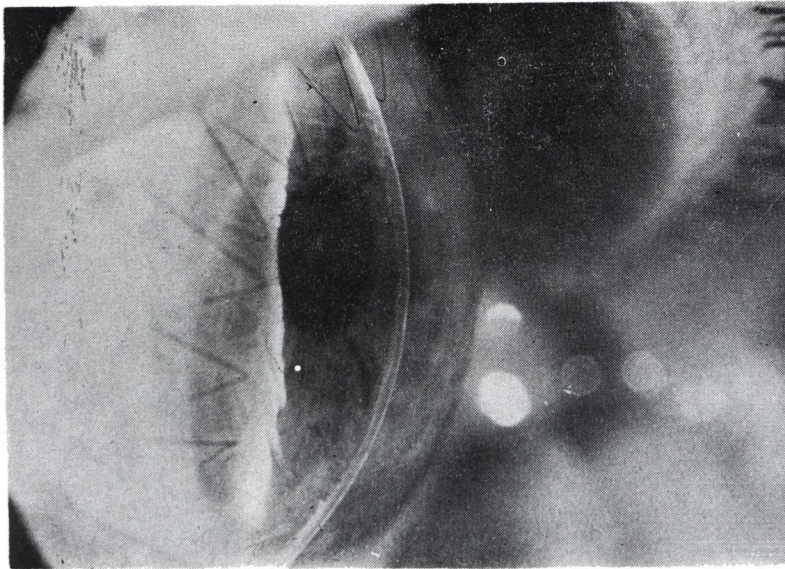


FIGURA 2 b

JOAQUIN BARRAQUER

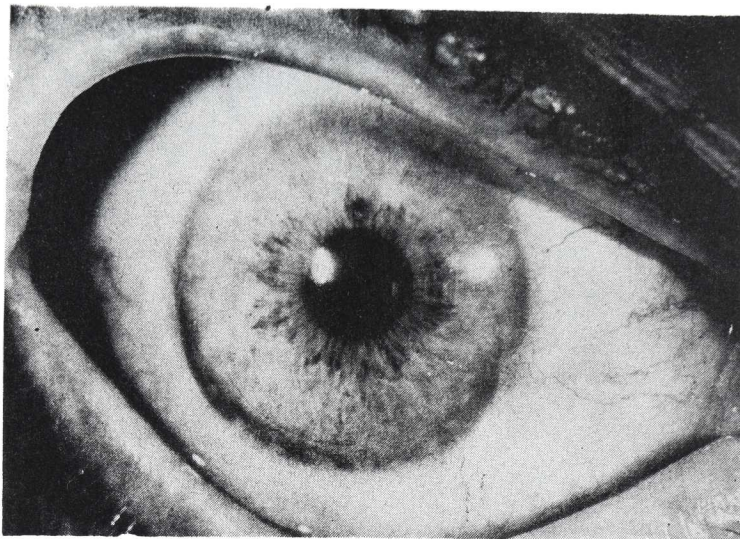


FIGURA 3 a

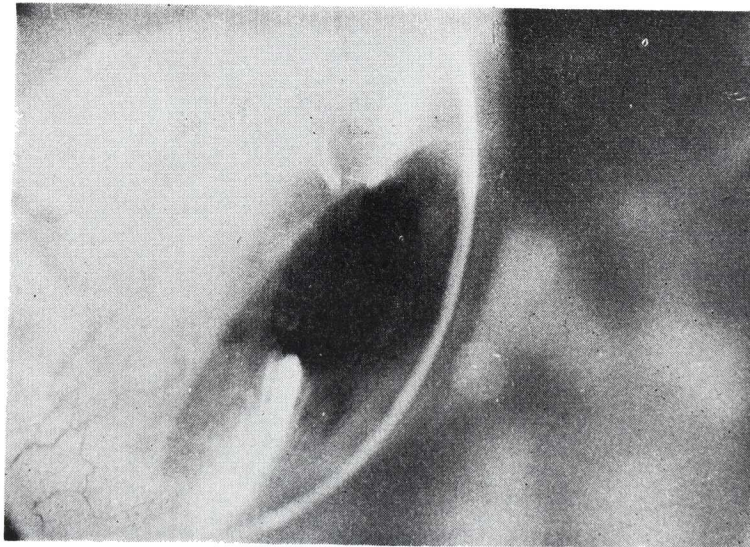


FIGURA 3 b

QUERATOPLASTIA EN CASOS COMPLICADOS

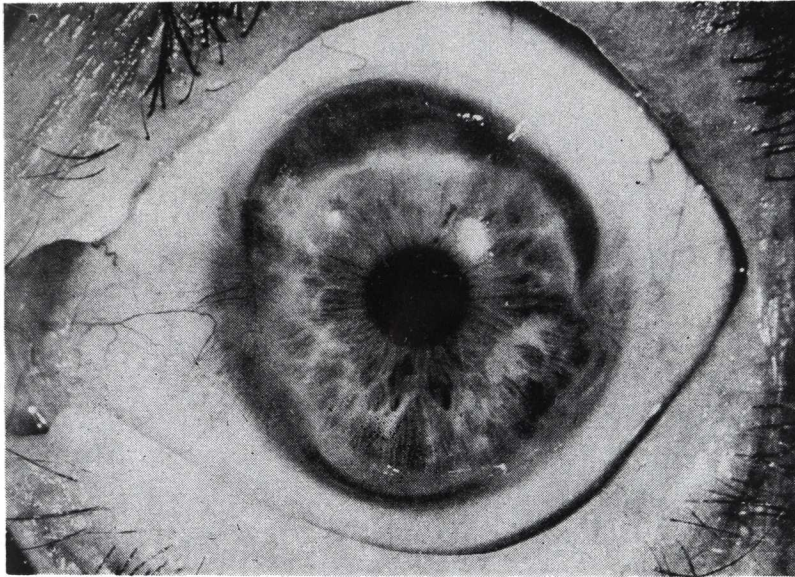


FIGURA 4 a

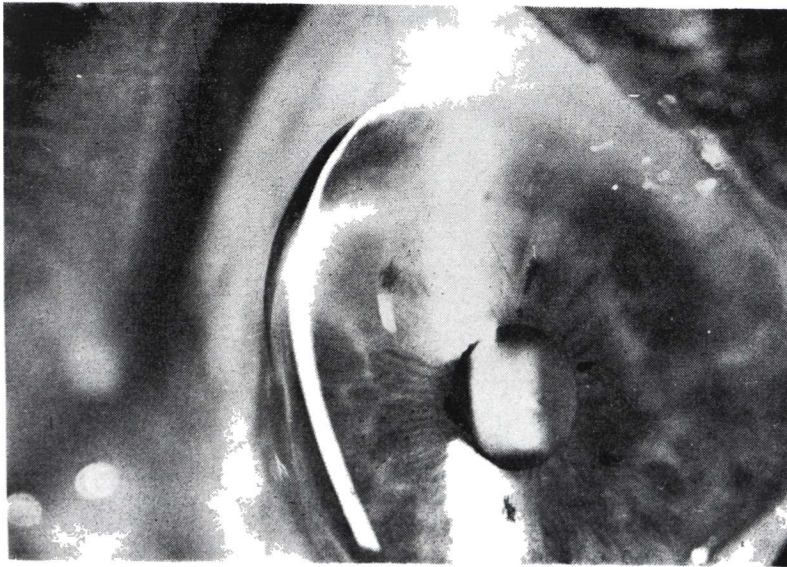


FIGURA 4 b

JOAQUIN BARRAQUER

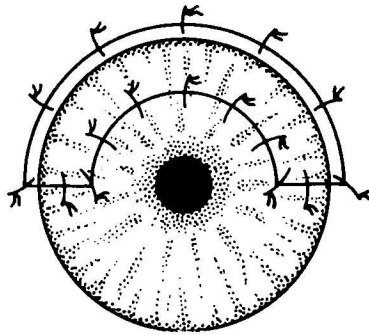


FIGURA 5

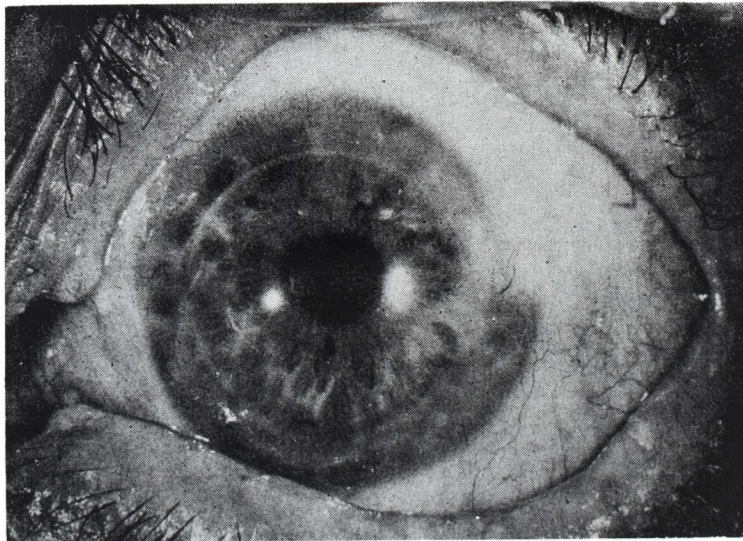


FIGURA 6 a

QUERATOPLASTIA EN CASOS COMPLICADOS

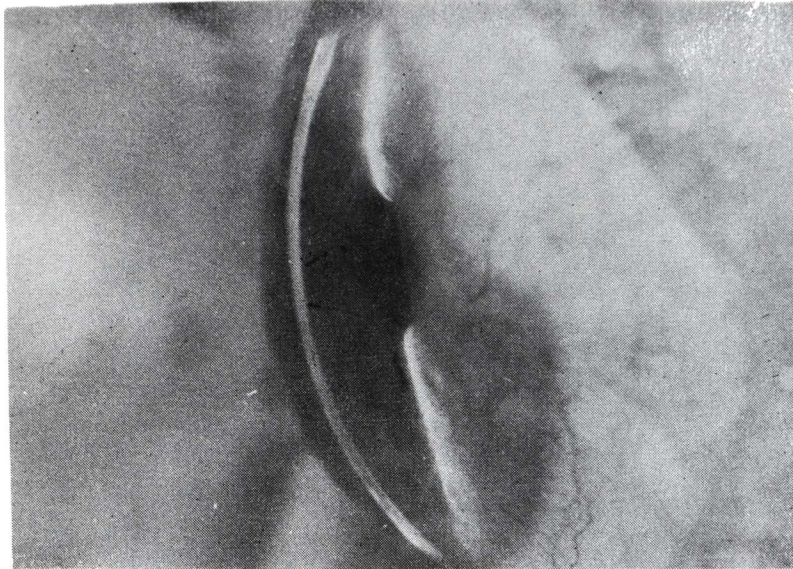


FIGURA 6 b

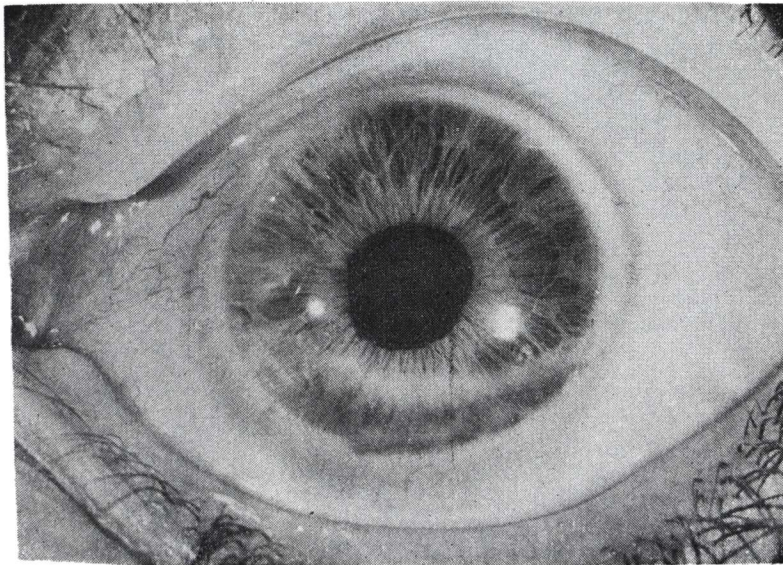


FIGURA 7 a



JOAQUIN BARRAQUER

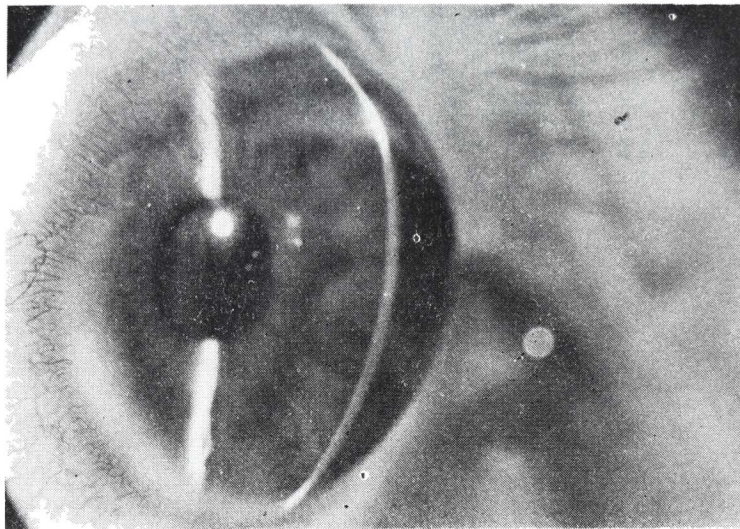


FIGURA 7 b

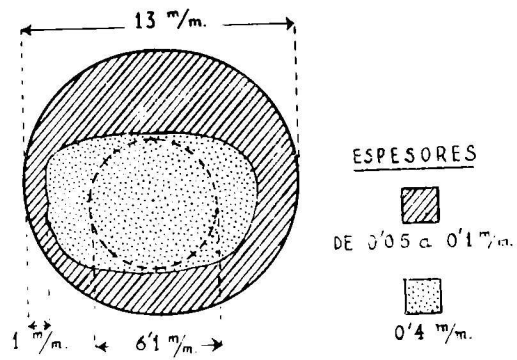


FIGURA 8

QUERATOPLASTIA EN CASOS COMPLICADOS

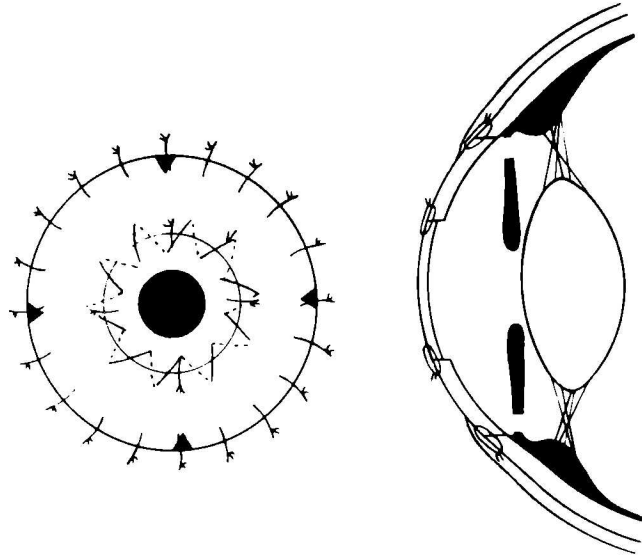


FIGURA 9

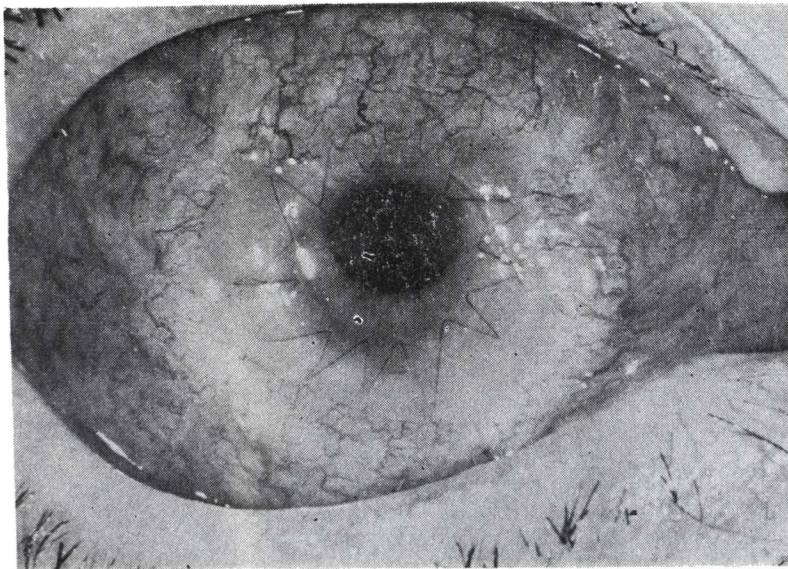


FIGURA 10

JOAQUIN BARRAQUER

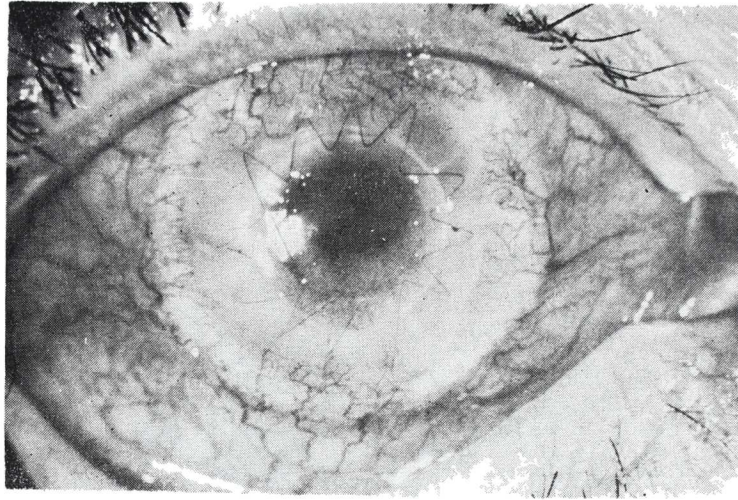


FIGURA 11 a

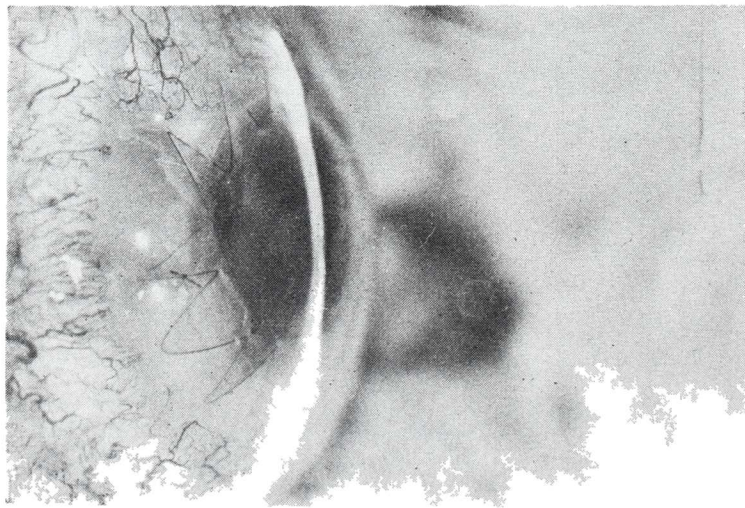
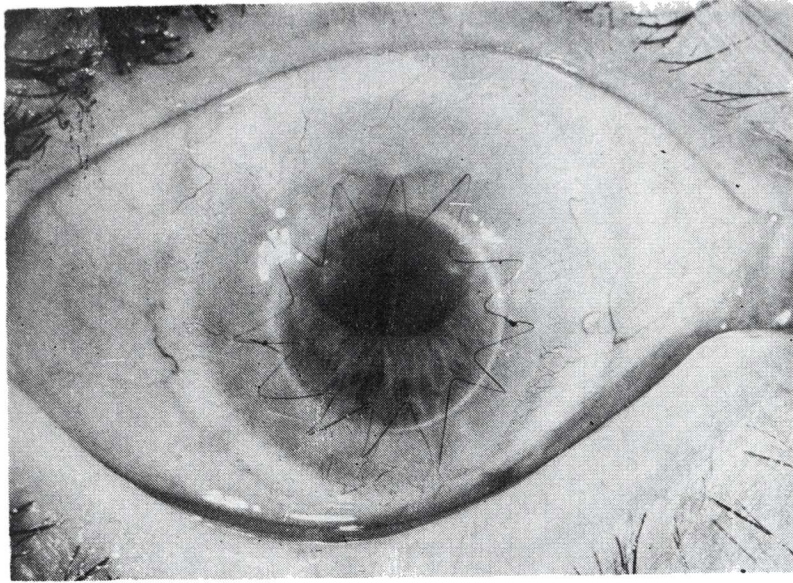
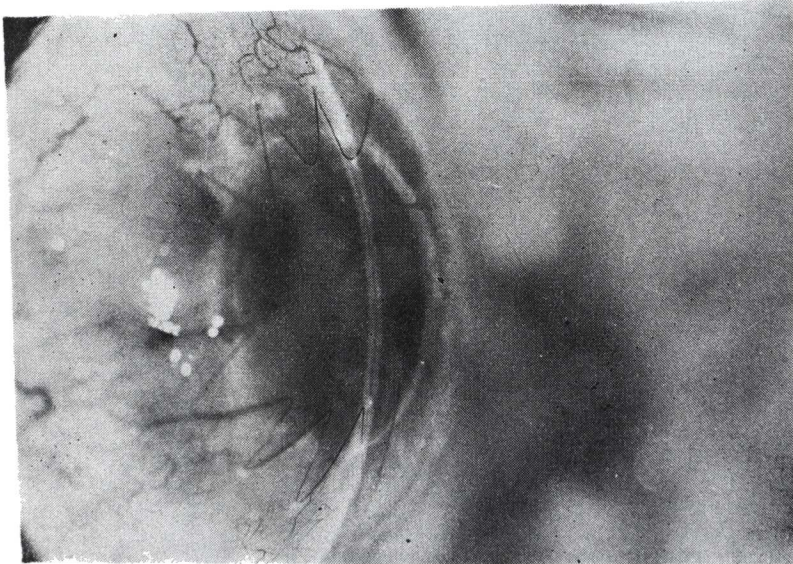


FIGURA 11 b

**QUERATOPLASTIA EN CASOS COMPLICADOS**



**FIGURA 12 a**



**FIGURA 12 b**

JOAQUIN BARRAQUER

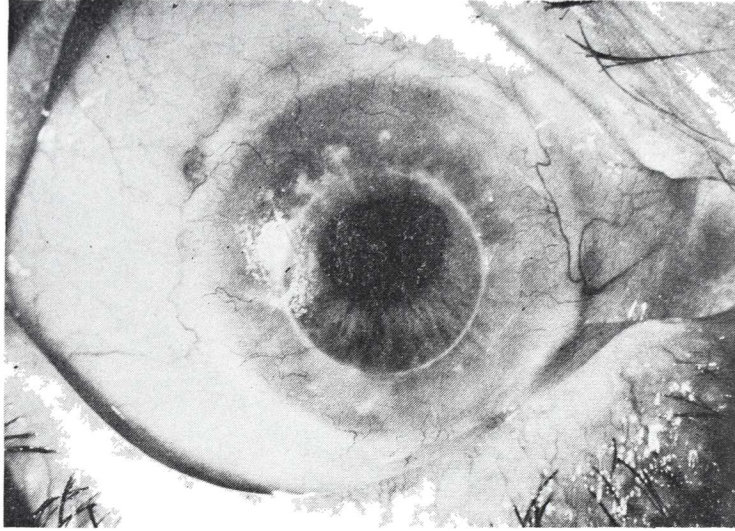


FIGURA 13 a

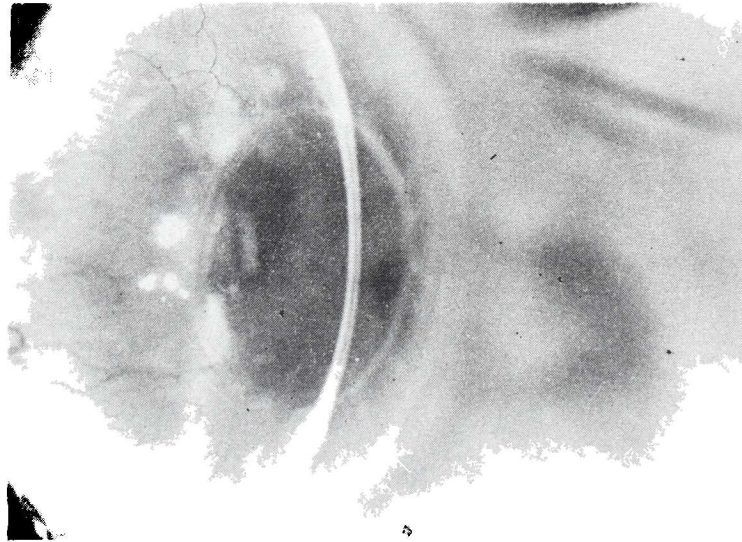
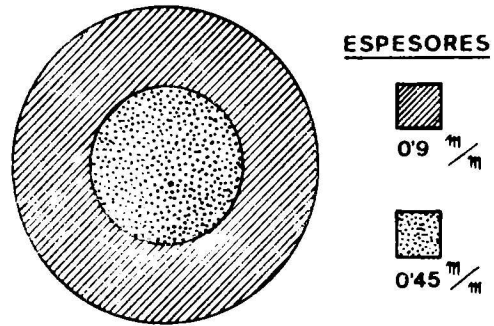


FIGURA 13 b

QUERATOPLASTIA EN CASOS COMPLICADOS



$V=0'4 (-6 \text{ a } 70^\circ). N 1 J . TG. = 10$

FIGURA 14

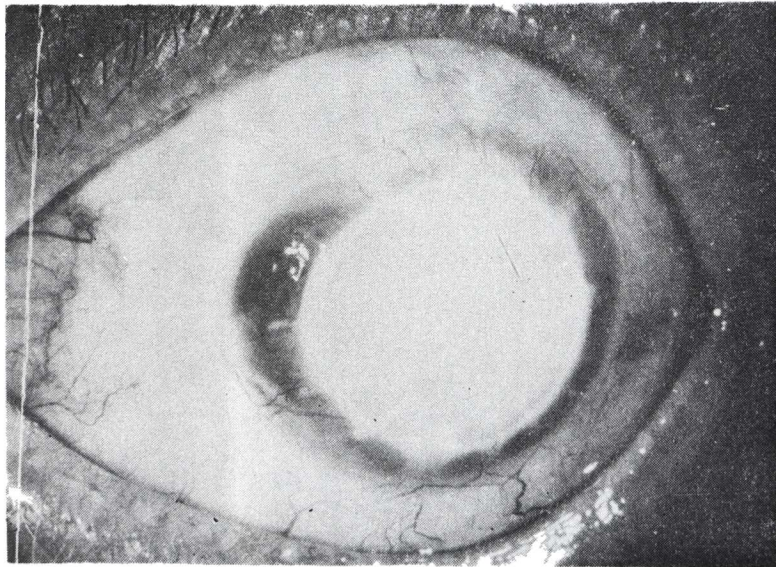


FIGURA 15 a

JOAQUIN BARRAQUER

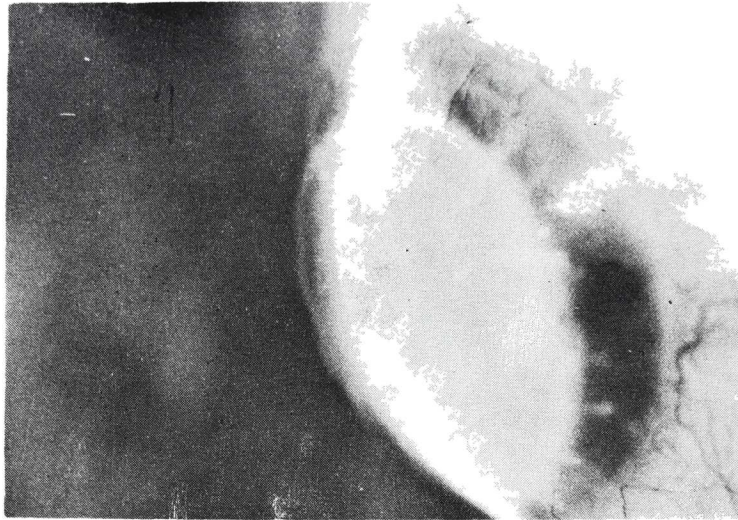


FIGURA 15 b

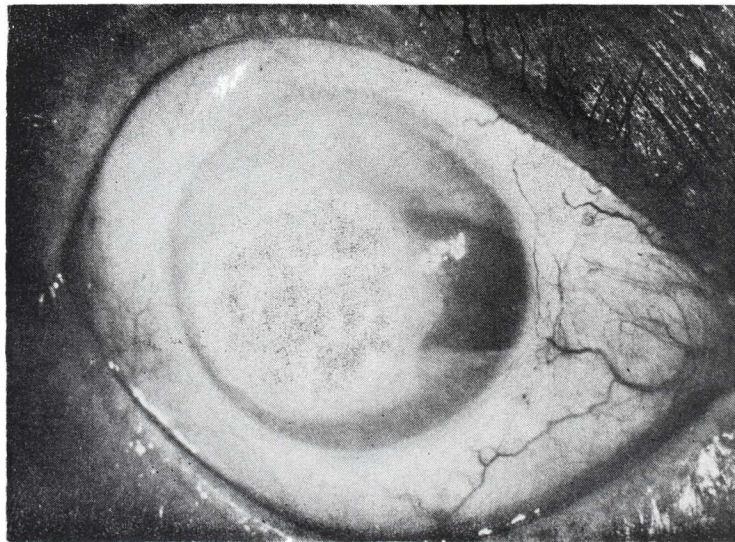


FIGURA 16 a

QUERATOPLASTIA EN CASOS COMPLICADOS

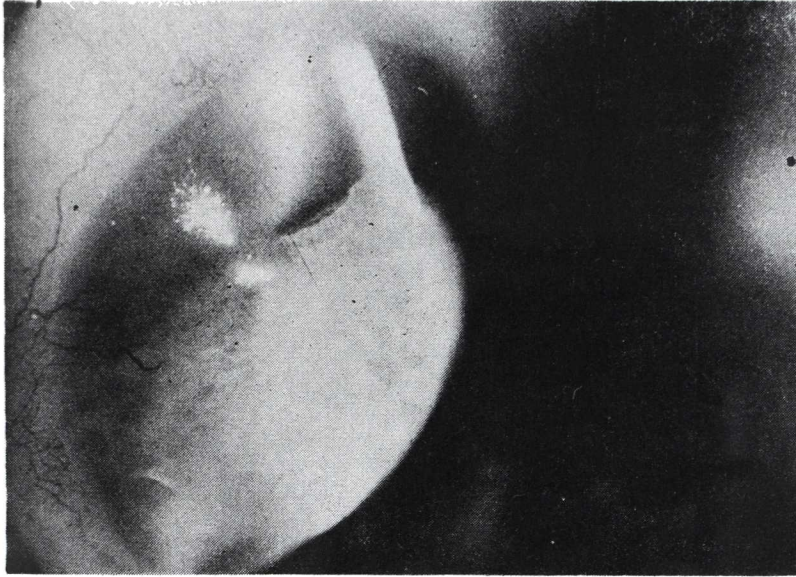


FIGURA 16 b

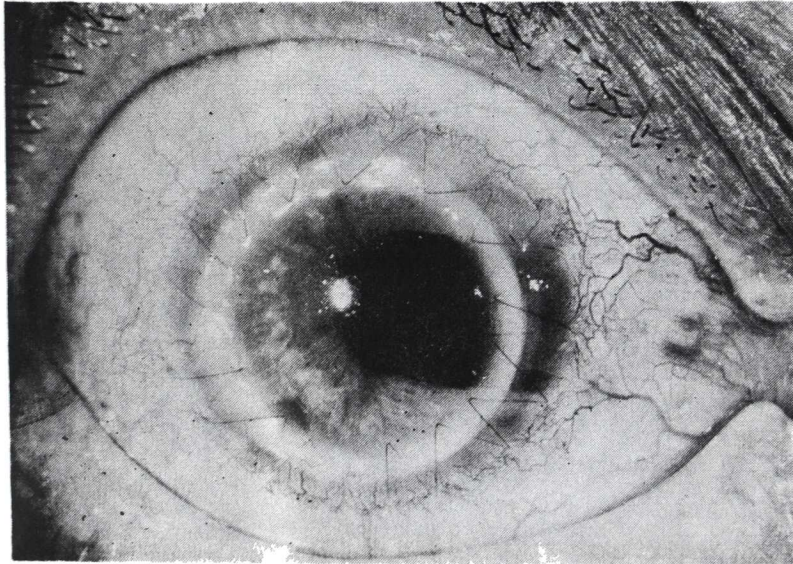


FIGURA 17 a



JOAQUIN BARRAQUER

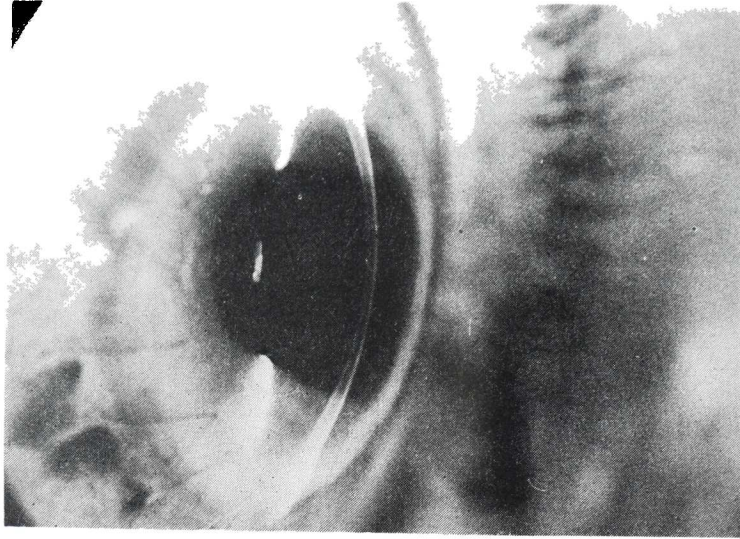


FIGURA 17 b

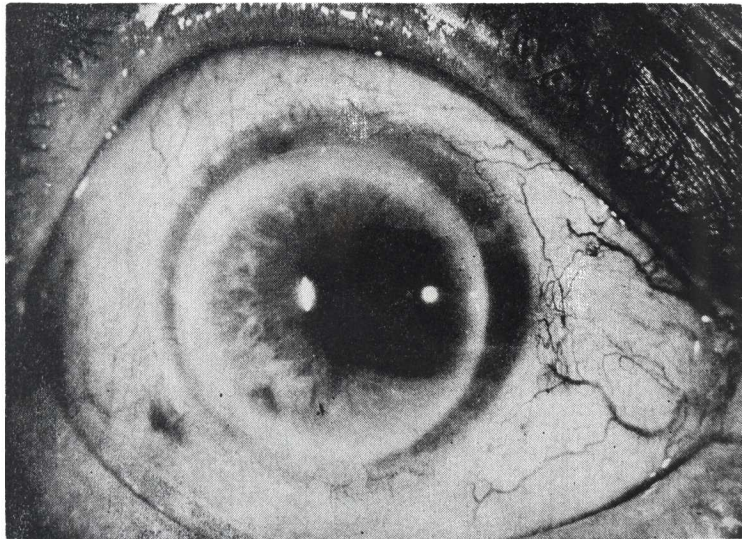


FIGURA 18 a

QUERATOPLASTIA EN CASOS COMPLICADOS

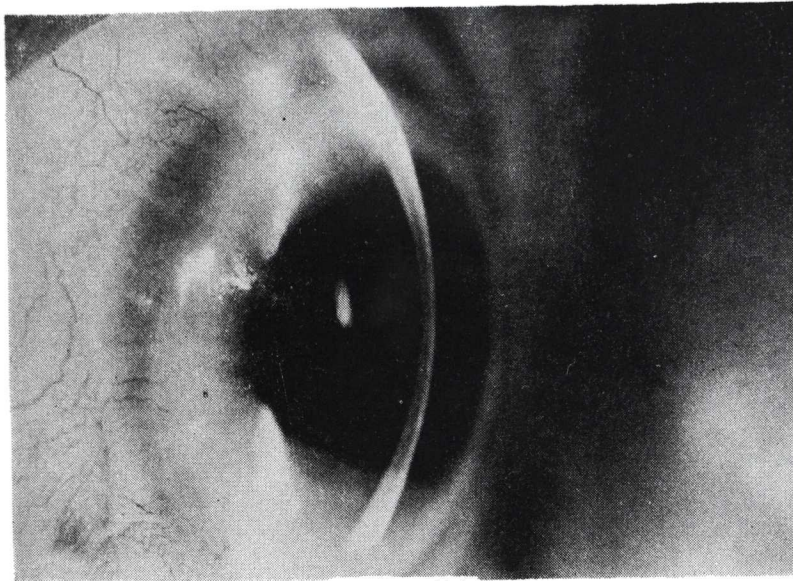


FIGURA 18 b

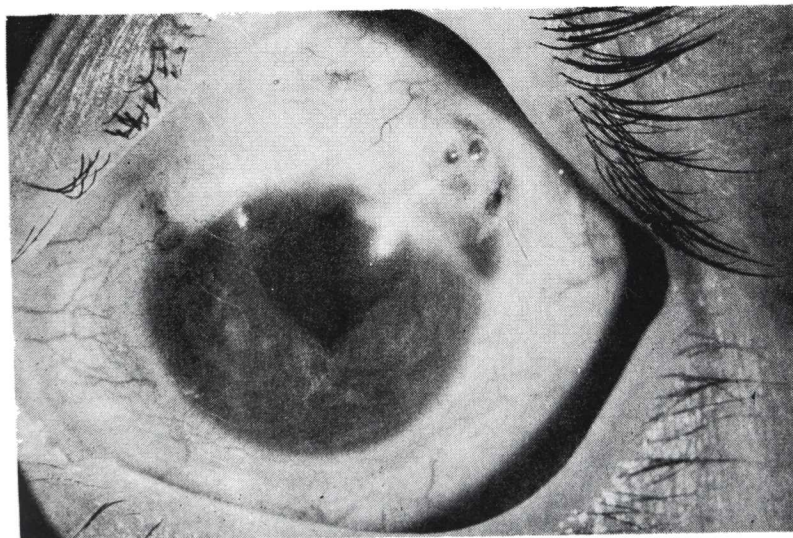


FIGURA 19 a

JOAQUIN BARRAQUER

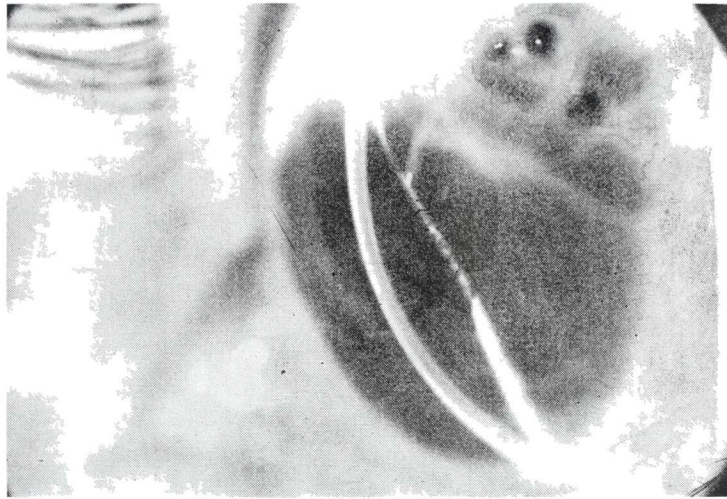

FIGURA 13 b

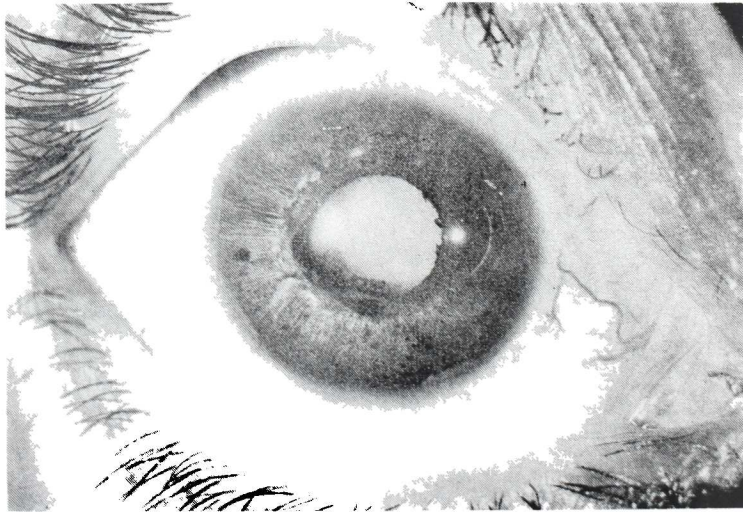

FIGURA 20 a

QUERATOPLASTIA EN CASOS COMPLICADOS

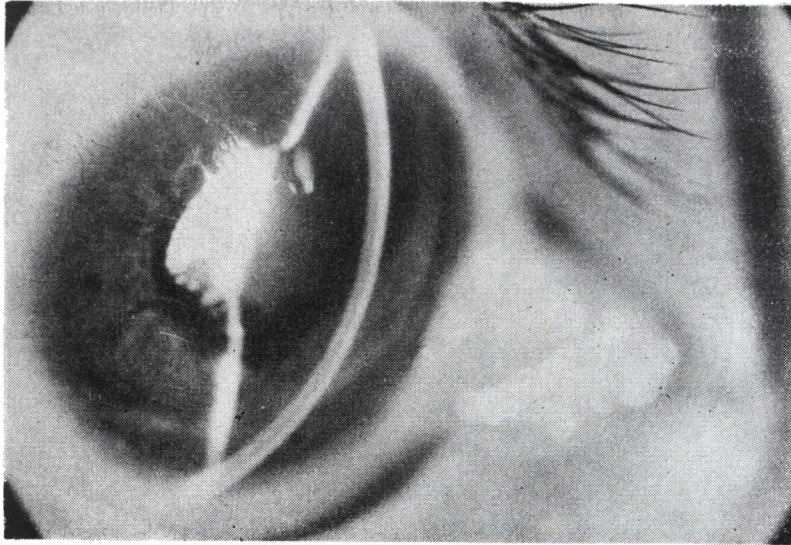


FIGURA 20 b




FIGURA 21

JOAQUIN BARRAQUER

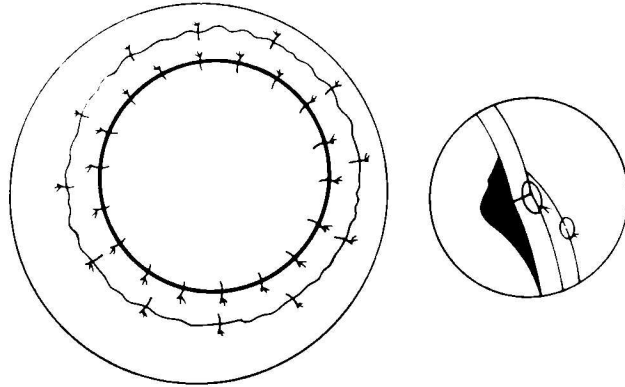


FIGURA 22

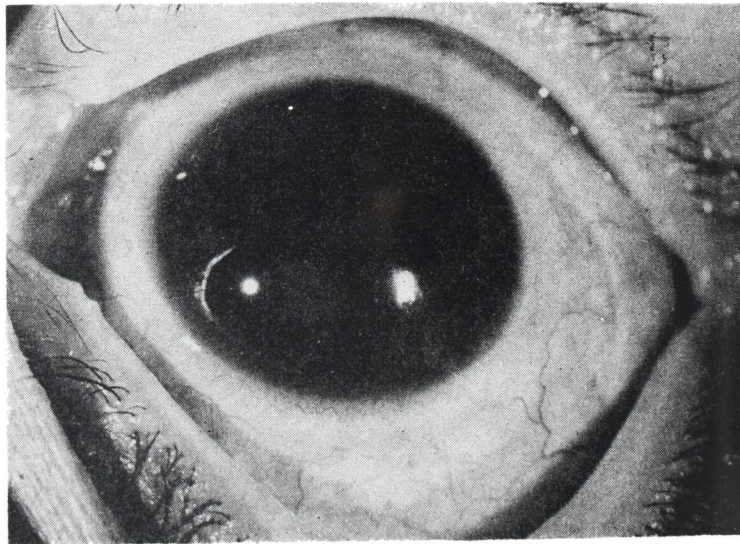


FIGURA 23 a

QUERATOPLASTIA EN CASOS COMPLICADOS

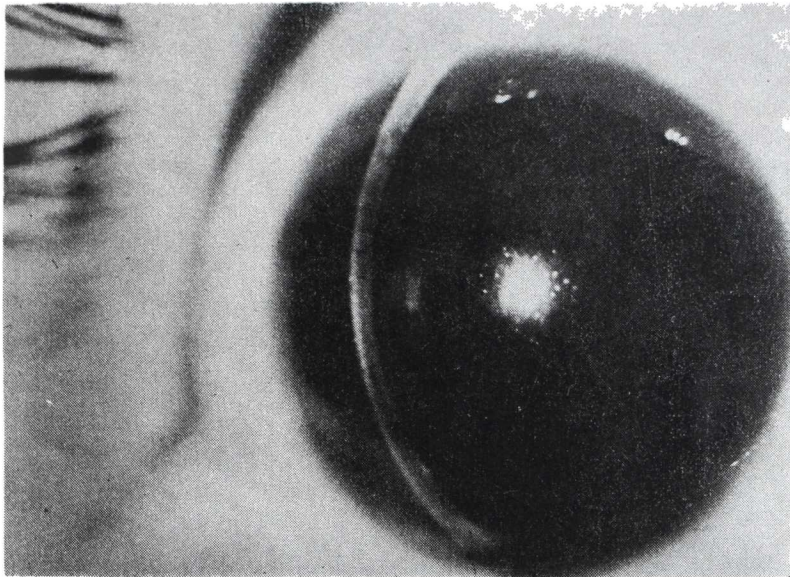


FIGURA 23 b

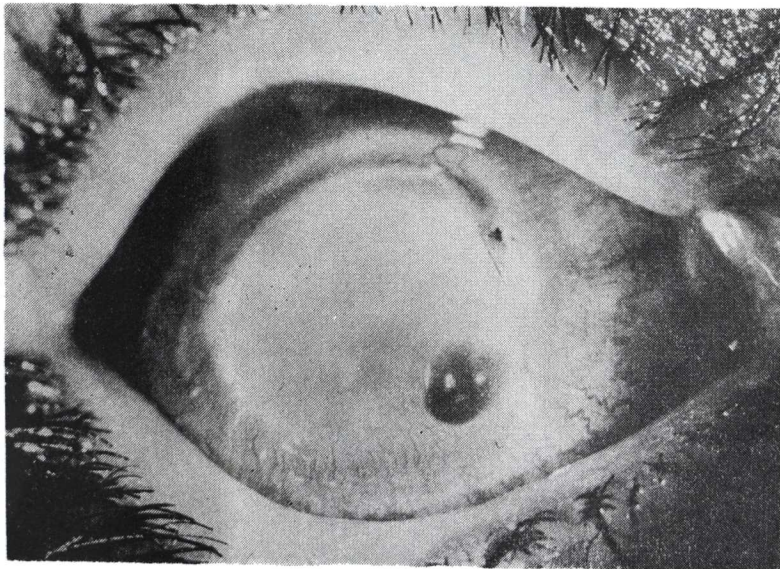


FIGURA 24 a

JOAQUIN BARRAQUER

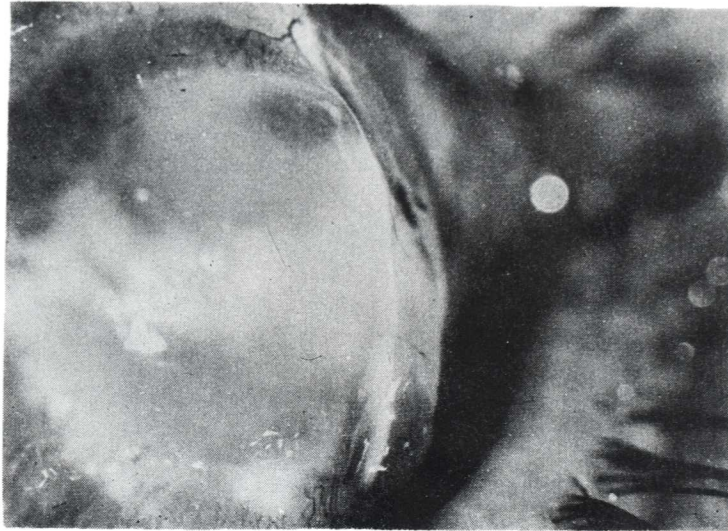


FIGURA 24 b

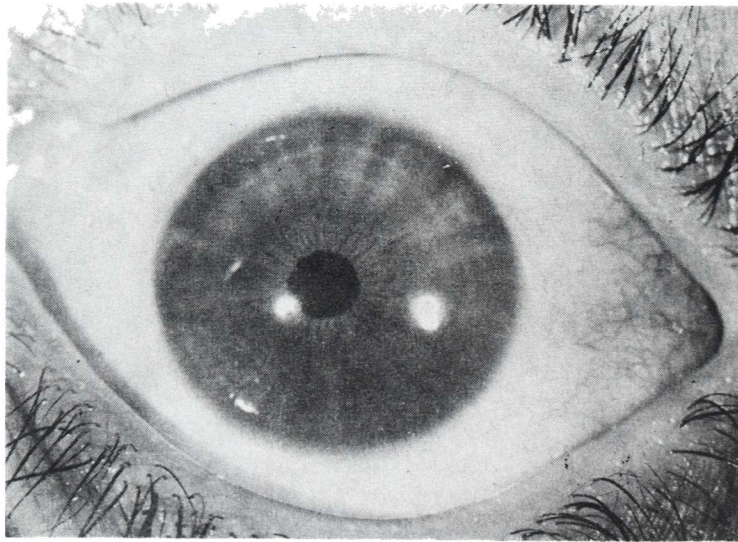


FIGURA 25

QUERATOPLASTIA EN CASOS COMPLICADOS

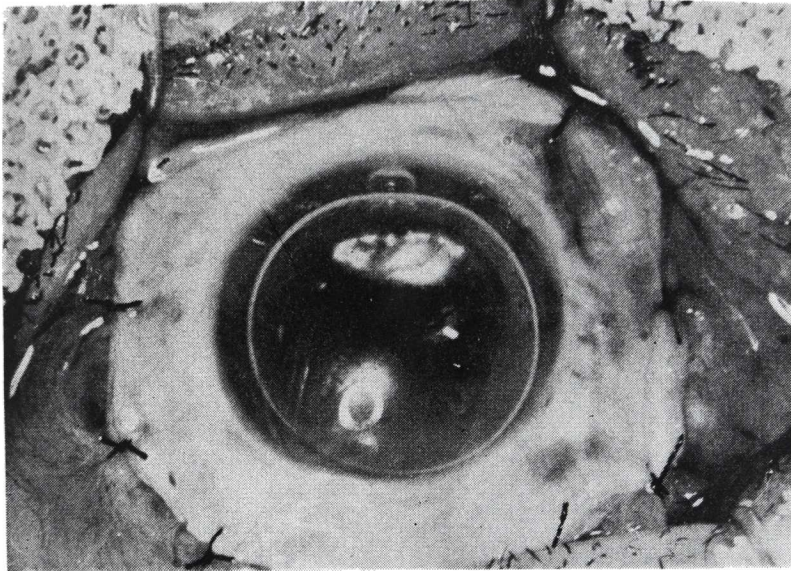


FIGURA 26

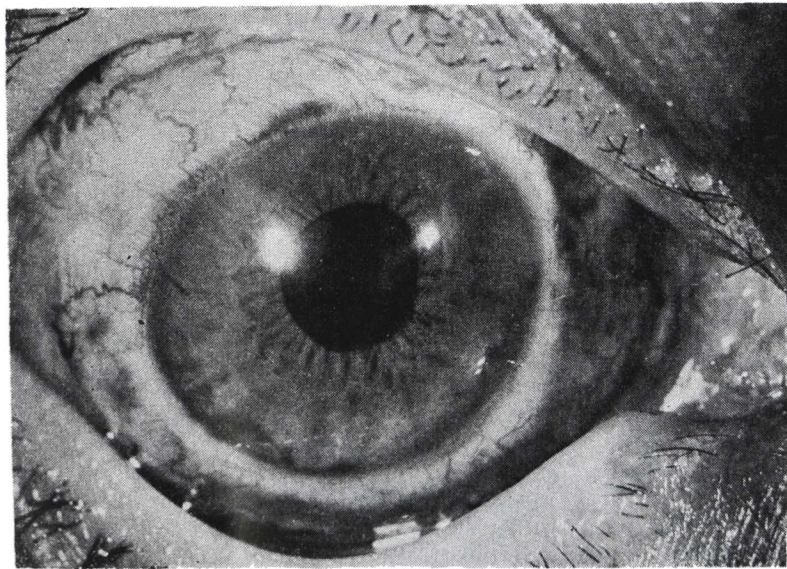


FIGURA 27



JOAQUIN BARRAQUER

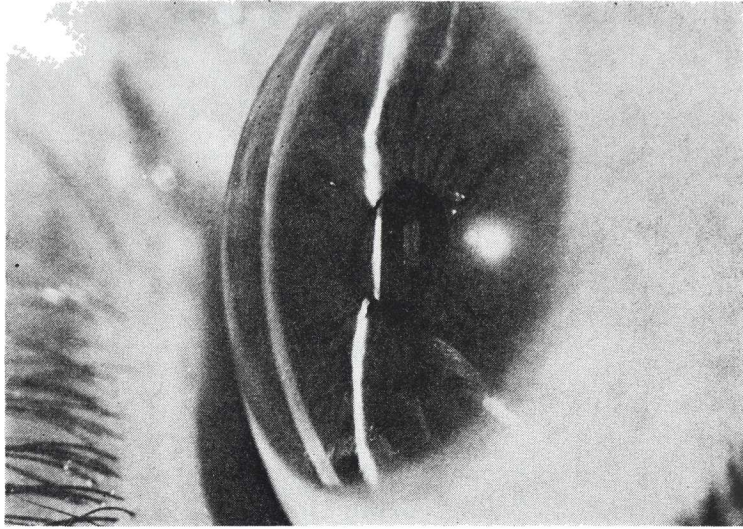


FIGURA 28

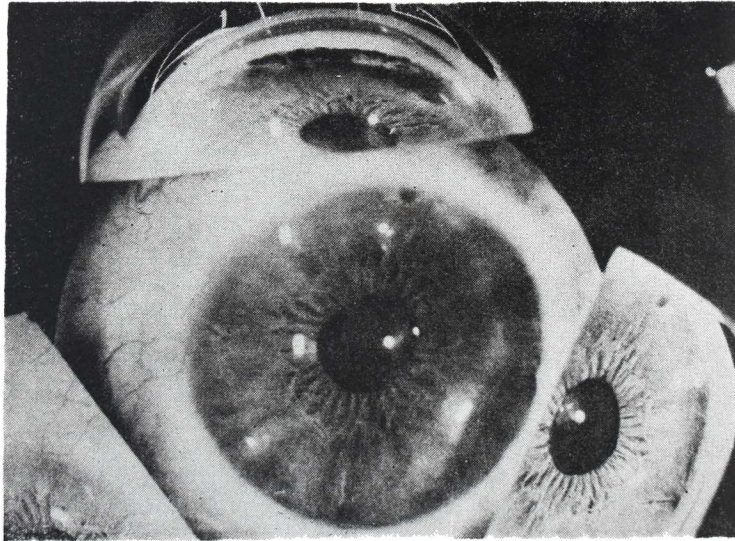


FIGURA 29

## NOTICE TO CONTRIBUTORS

Papers submitted for publication, book for review and other editorial communications, including applications for exchanges should be sent to the "Redacción Archivos de la Sociedad Americana de Oftalmología y Optometría", Apartado Aéreo 091019, Bogotá, 8, Colombia.

All papers should be accompanied by a statement that they have not already been published elsewhere and that, if accepted, they will not subsequently be offered to another publisher without the consent of the Editorial Committee. They should be typewritten in double spacing on one side of the paper only, with 2-inch margin. The author's name should be plainly indicated following title of paper and the address should appear at the end of the article.

The author's name should be accompanied by highest earned academic or medical degree which he holds.

Illustration should be separate from the typescript and numbered in sequence with the appropriate legends, on a separate sheet. Each should be marked on the back with the author's name, and the upper edge should be marked "Top" for the printer's guidance. Graphs and charts should be clearly drawn in Indian ink on tracing linen, Bristol board, or stout, smooth, white paper. All lettering should be lightly written in pencil. Photomicrographs should bear a note as to the degree of magnification. When X-ray reproduction is required, the author is advised to send the original film.

If it is necessary to publish a recognizable photograph of a person, the author should notify the publisher that permission to publish has been obtained from the subject himself in an adult, or from the parents or guardian if a child.

References should be listed alphabetically, arranged in the style of the Harvard system, and abbreviated according to the World List of Scientific Publications (the volume number in arabic numerals underlined with a wavy line to indicate bold type, the number of the first page in arabic numerals):

v. g. SCHEPENS, C. L., (1955) *Amer. J. Ophthalm.*, 38,8.

When a book is referred to, the full title, publisher, place and year of publication, edition and page number should given:

v. g. RYCROFT, B. W., (1955) "Corneal Grafts" p. 9. Butterworth. London.

Contributors will receive galley-proofs on their articles, but it will be assumed that all but verbal corrections have been made in the original manuscript. Fifty reprints of each article will be sent free to the contributor (s). A limited number of additional reprints as cost price can be supplied applications in made when returning proofs.

Applications and correspond concerning advertisements should be addressed to: Casa Heller Ltda. Apartado Aéreo 4966. Bogotá - Colombia

Subscription price per annum, including postage:

Colombia — \$ 150.00 (Colombian pesos).

Foreign — \$ 10.00 (U. S. Currency).