

METASTATIC TUMOR IMPLANTS IN THE ANTERIOR CHAMBER

GEORGES ASSIS MASRI, M. D.

Cali - Colombia

CASE REPORT:

V. B. years old, white male, came to the office complaining of pain, photophobia, lacrimation, blurred vision, and congested left eye for the last three days. He had lost 20 pounds in two months and noticed low back pain.

Examination revealed visual acuity of 20/25 in the right eye and 20/40 in the left eye with correction. Refraction: + OD: + 1.25; OS = + 0.75. The right eye was normal with incipient nuclear senil cataract. The left eye was tender to palpation and showed marked injection mainly circumcorneally. The pupillary reaction was impaired and the pupil was miotic and slightly distorted to the lateral side where a white, coliflowerlike, mass occupied part of the angle of the anterior chamber, mostly the upper lateral quadrant. This mass was avascular, well circumscribed and adherent to the adjacent iris. The aqueous was turbid, three plus Tyndall, and there were small keratic precipitates on the posterior surfacer of the cornea, composed of lymphocytes. The iris itself was edematous with loss of normal luster. There was absence of posterior or anterior synechiae at gonioscopic examination. Ophthalmoscopic examination was not done at this time. The intraocular preassure was 12 mm Hg. In the right eye and 17 mm Hg, in the left eye. The diagnosis was acute anterior uveitis, secondary to local necrosis of metastatic tumor in the anterior chamber. Few days, after treatment with local 2.5% Hydrocortisone every 2 hours and Atropine 1% gtt. twice a day, the uveitis subsided and the ophthalmoscopic examina-

GEORGES ASSIS MASRI

tion with indirect ophthalmoscope was done. No tumor mass were seen up to the ora serrata. Transillumination was negative except at the side of the tumor mass. The vitreous showed moderate Tyndall of inflammatory cells and the optic disc and the posterior pole were normal. The visual acuity improved to 20/25 cc, and the intraocular pressure dropped to 12 mm Hg.

GENERAL PHYSICAL EXAMINATION:

The only positive findings were a nodule in the left lobe of the thyroid, hard, regular, non tender and mobile. There was small, firm nodule, in the left upper flank measuring 1 x 1.5 cm fixed to the skin. Rectal examination disclosed an enlarged but benign prostate to palpation.

LABORATORY FINDINGS:

The hemogram as well as the peripheral smear were normal. Bone marrow was also unremarkable. Chest films revealed a wide mediastinum with a nodule in the right hilum and a prominent aortic arch. Bronchoscopy and bronchograms were normal (there was no deformity of the main bronchi).

Biopsies were performed of the thyroid and in the abdominal wall nodule. Pathology reported nodular thyroid and in the abdominal wall nodule many abnormal lymphocytes, with hyperchromatic nuclei, without any arrangement and with a sarcomatous stroma. The diagnosis was lymphosarcoma, lymphocytic-type.

The patient was treated with Nitrogen Mustard, 0.2 mg x kg, divided in two doses. The white blood count dropped to 3,000 but the drug was well tolerated.

DISCUSSION:

This is the case of a well demonstrated lymphocytic lymphosarcoma with metastasis to the left eye, abdominal wall and nodes. The probable mechanism of this anterior uvea metastasis is through the long ciliary arteries though typically they appear more frequently in the posterior choroid by way of the short posterior ciliary arteries. The original tumor was probably located in the mediastinum.

METASTATIC TUMOR IMPLANTS IN THE ANTERIOR CHAMBER

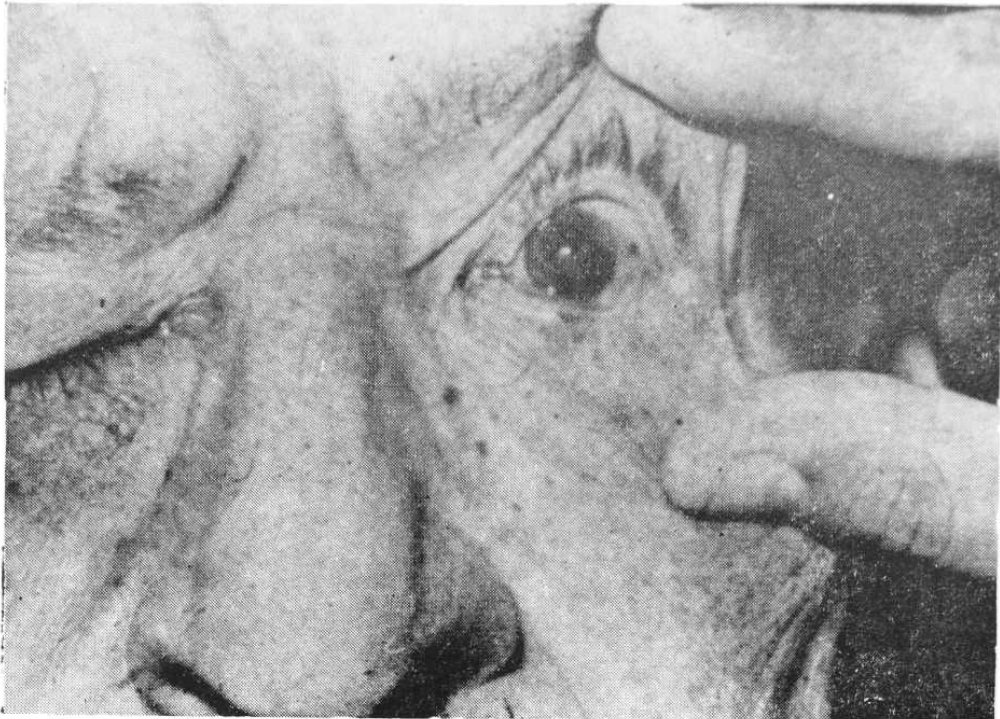

FIGURE 1

Photograph showing the tumor in the upper lateral quadrant.

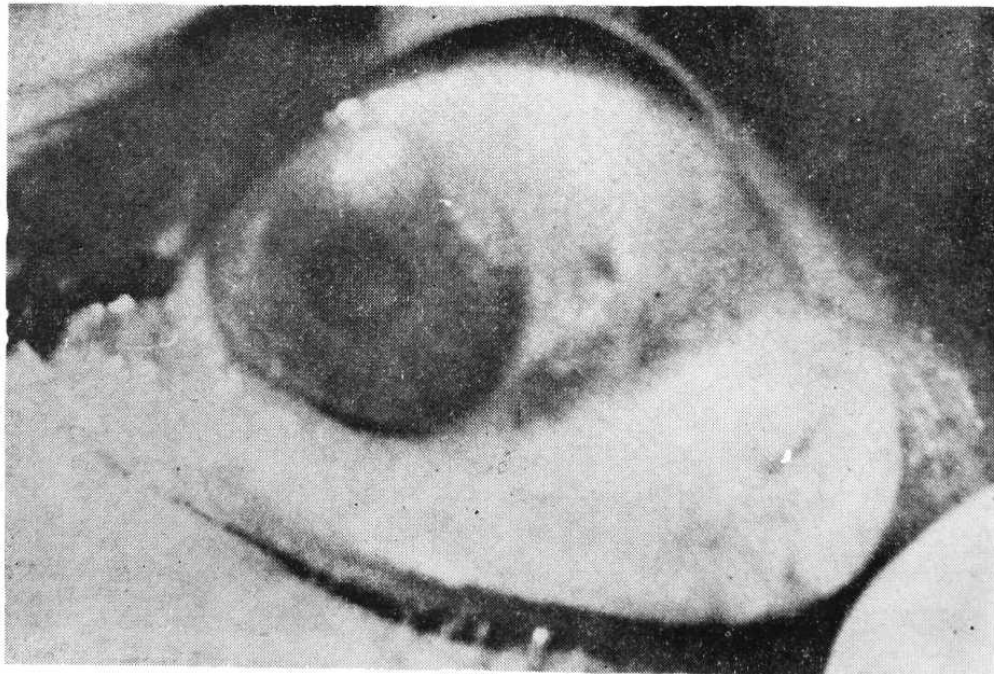


FIGURE 2

Close view of the tumor mass.

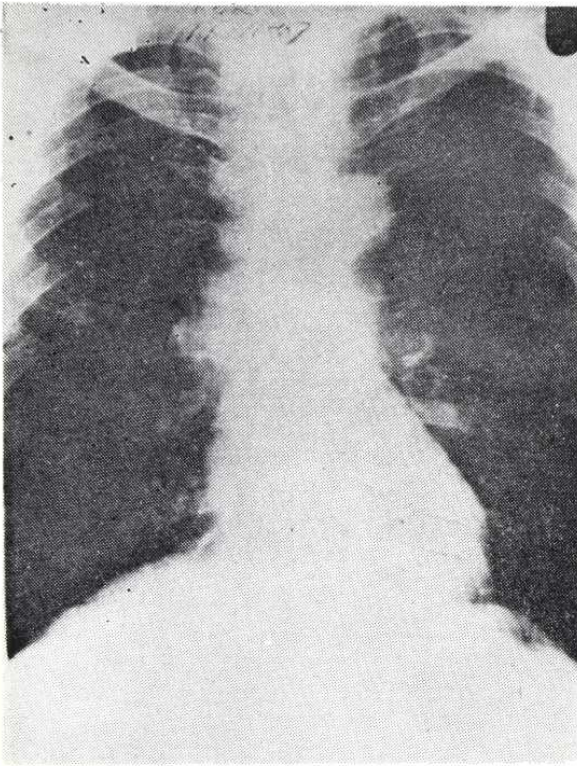


FIGURE 3

X-ray of the chest. Wide mediastinum and prominent right hilum.

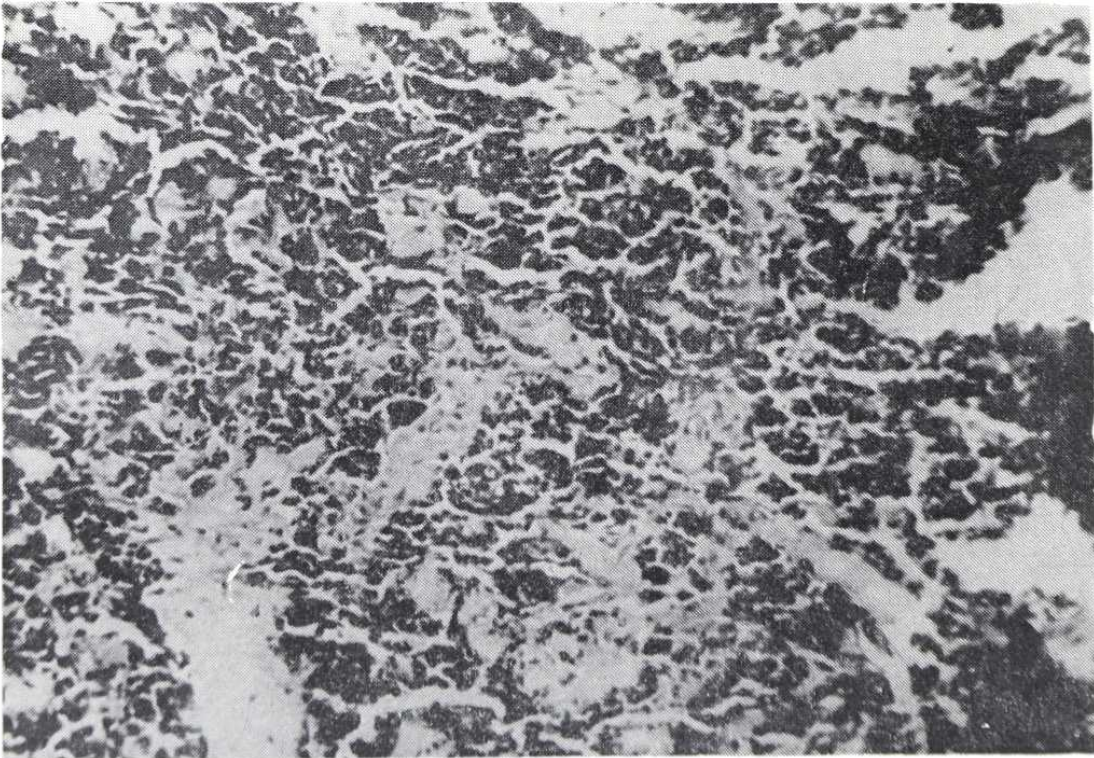


FIGURE 4

Microscopic view of the abdominal nodule. Numerous atypical lymphocytes without any arrangement and sarcomatous stroma.

METASTATIC TUMOR IMPLANTS IN THE ANTERIOR CHAMBER

We considered this an advanced case in view of the spread, age and condition of the patient. The eyes was not enucleated because the pain could be easily controled.

Nitrogen Mustard was the drug of election. In case of respiratory obstruction or hemopthysis, the mediastinum and the hilum of the right lung could be radiated.

SUMMARY:

This case showed that the eye is not infrequently the first site of malignant spread, and the eye symptoms occasionally precede the diagnosis of the primary tumor.