

## ACTAS TERTIUM FORUM OPHTHALMOLOGICUM

### OCULAR RHEOGRAPHY IN PRIMARY GLAUCOMA

Profesor GIUSEPPE CRISTINI  
Bologna, Italia

Rheography is the recording of the electrical impedance variations in a body district filled with blood which has been set between two electrodes connected with a Weathstone bridge.

Blood is an excellent electrical conductor so that during systole, owing to lower electrical resistance, a rise of the curve is recorded, while during diastole, cwing to increased resistance, a fall is observed.

In 1975 in our Department we worked out an ocular rheographic method for the study of the circulation in the human eye. Since the largest quantity of ocular blood flows through the uvea ocular rheography allowed us to study blood flow in this membrane.

With this method we were able to examine all qualitative aspects of ocular blood pulse, such as amplitude and sphygmic speed, and also to measure the rate of blood flow in the eye.

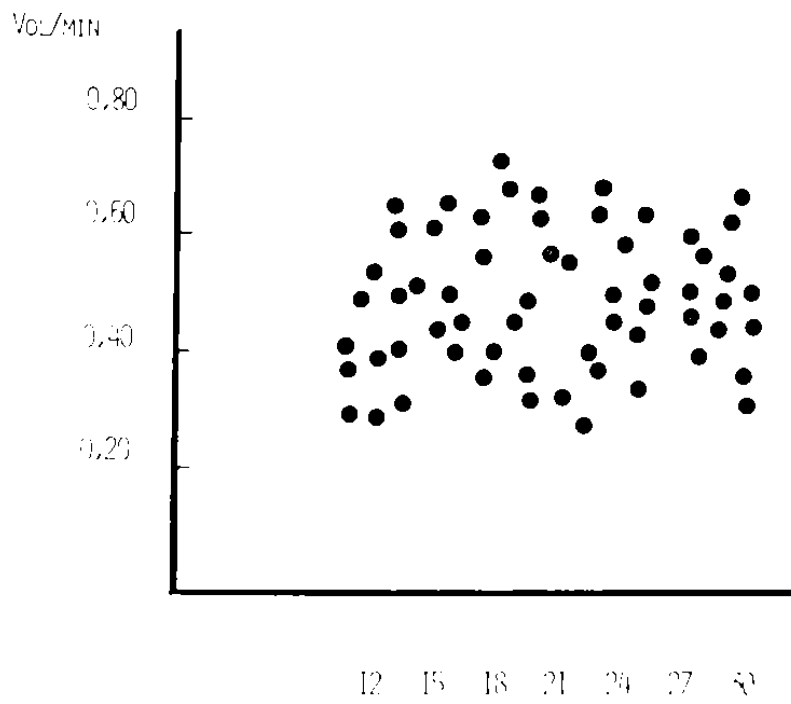
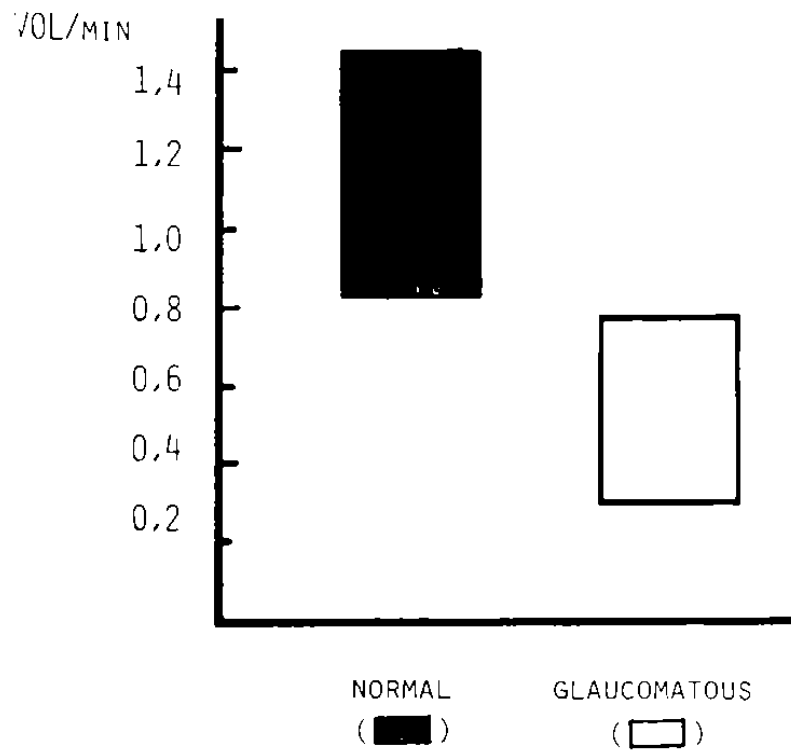
The following film is a schematization of the method employed.

What is the importance of ocular rheography in an eye affected with primary glaucoma?

While a detailed body of doctrines has been built up on the debit of the aqueous humour in the glaucomatous eye, the same cannot be said of blood flow.

Nevertheless experimental, pathological, and clinical indications have been given also for ocular hypertension which drew attention to the significant pathological changes in uveal circulation.

GIUSEPPE CRISTINI



I.O.P. (mmHg)

## PTERIGIO. TRATAMIENTO QUIRURGICO

### SUSPICIOUS GLAUCOMA

Amplitude, sphygmie speed, rate of blood flow

Age 59  
general pressure 140/70 mmHg  
intraocular pressure 20 mmHg

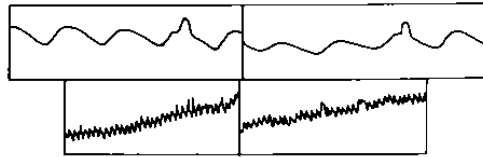
#### In basal conditions

rate of blood flow 0,90 cm<sup>3</sup>/min.

#### With amyl nitrite

Amplitude, sphygmie speed, rate  
of blood flow are reduced.

Rate of blood flow 0,80 cm<sup>3</sup>/min.



### GLAUCOMATOUS CYCLITIS

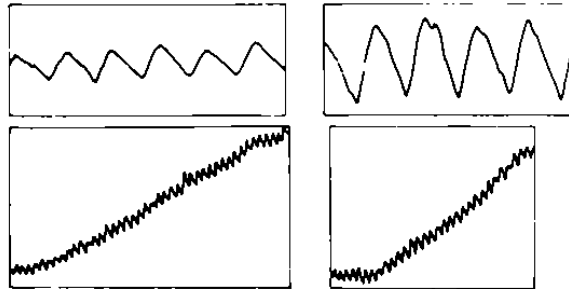
Age 28  
general pressure 130/50 mmHg  
intraocular pressure 40 mmHg

#### In basal conditions

rate of blood flow 1,1 cm<sup>3</sup>/min.

#### With amyl nitrite

Amplitude, sphygmie speed, rate  
of blood flow are increased.  
Rate of blood flow 1,35 cm<sup>3</sup>/min.



From the numerous experimental and clinical studies performed with our collaborators from 1975 up to date we can thus summarize our results:

1) Sphygmie amplitude in the glaucomatous eye is always lower than in the normal eye of a subject of the same age. While in the normal eye sphygmie amplitude is generally correlated to the subject's age, in the glaucomatous eye it is correlated to the disease only.

GIUSEPPE CRISTINI

2) Sphygmie speed is always reduced in the glaucomatous eye as compared with the normal eye of a subject of the same age.

3) The rate of blood flow in the normal eye is between 1,35 cm<sup>3</sup>/ min. and 0,8 cm<sup>3</sup>/min. The decrease is related to the subject's age.

In the glaucomatous eye we have always found values lower than 0,8 cm<sup>3</sup>/min. and there was no relationship to ocular hypertension.

The short time at our disposal does not allow us to report the theoretical implications deriving from our results. A more detailed paper is being published in Graefes Archiv.

But we can, I think, affirm that rheography is the most striking method for the functional exploration of uveal circulation, in the glaucomatous eye as well.

Above all, ocular rheography, if performed during the inhalation of amyl nitrite, is a precious method to detect suspicious glaucoma, superior in our experience, to any other provocative test so far known.

While in normal subjects the inhalation of amyl nitrite produces an increase especially in amplitude, but also in sphygmie speed and in the rate of blood flow, in a patient with suspicious glaucoma amplitude, sphygmie speed, and the rate of blood flow either remain unvaried or are reduced, but never are they increased.

As we have written on various occasions this probably depends on the fact that in glaucomatous eye the network of the small uveal vessels is progressively reduced, involving even the capillary reserve districts.