

PROSTHOKERATOPLASTY

HERNANDO CARDONA, M. D.
Cali, Colombia

After several years of investigation in Prosthokeratoplasty, during which time many prototypes and techniques of implantation have been tried, we have found several factors which have continuously given us positive results, and we have leaned towards those findings, applying them in the hope of making further advances in the field. Those factors are out-lined below:

1. A central optical cylinder is the best way to transport an image to the retina.
2. A screwing mechanism in this cylinder permits setting the surface of the cylinder to the level of the surrounding tissue at completion of the operation or at any time during the procedure.
3. A pigment, imbedded in the periphery of the optical cylinder improves the image on the retina by eliminating glare and circular diffusion.
4. The combination of various indexes of refraction in the cylinder helps to obtain better resolution of the image.
5. The estenopeic effect added to previous factors permits the patient, in many cases, to see both near by and at a distance without correction.
6. The visual field depends on the diameter and the length of the cylinder. We have found that the optimum measurements are 3.5 mm. in diameter, and 7.5 mm. in length. These measurements can be varied according to desire at any time.
7. We are currently using a standard dioptric power of ± 68 . Ultrasound measurements of the axial length can be taken if a better correction is desired. This is not, however, essential. Vision can also be corrected with additional glases or hydrophylic contact lenses in some cases.

In our observations of more than 1500 cases of Prosthokeratoplasty during a period of thirty years, we have seen that in 25% of the cases, the prosthesis is slowly extruded. An analysis of the mechanisms of extrusion have led to the development of a new technique of implantation which seems to offer a solution to the problem. This technique, which has given very satisfactory results in twelve cases observed over a five year period, is presented here.

A brief analysis of the mechanism of extrusion

Extrusion generally results from lysing or melting of the scarred cornea due to enzymatic activity as in severe chemical burns. Deterioration begins around the edges of the cylinder and is helped by the blinking action of the eyelid. It takes a period of one to three months for extrusion to be completed. (See Fig. 1).

In previous cases, we limited ourselves to placing the prosthesis underneath a granulomatous, vascularized tissue which contained insufficient collagen fibers to support the prosthesis. It was seen that this granulomatous tissue has no retentive properties, and the prosthesis, which slowly begins to move away from the center of the cornea, is extruded.

To avoid these problems, we have begun to apply a new system of support using a piece of flexible non-degradable mesh made of Dacron, which is covered with an autologous tissue like fascia lata or periosteum. We have also extended the area covered by the supporting tissue to the four recti muscles. This new procedure has greatly reduced the extrusion rate.

The Model Keratoprosthesis (See Fig. 2).

The Keratoprosthesis is composed of two parts:

- A. An optical cylinder of methyl methacrylate attached to a clear or colored flange. In some cases, this flange may be removed. This cylinder is pigmented at the periphery to reduce glare, and it is also threaded along the entire length except for the last millimeter. The cylinder measures 3.5 mm. in diameter, and 7.5 mm. in length.
- B. A Teflon skirt, 8.5 mm. in diameter, and 0.3 mm. thick, with a curvature radius of 6 mm., it is perforated with holes 1.8 mm. and 0.5 mm. in diameter to allow the recipient tissue to grow through. In the center there is a threaded perforation 3.5 mm. through which the cylinder is screwed.

(See Figs. A and B).

PROSTHOKERATOPLASTY

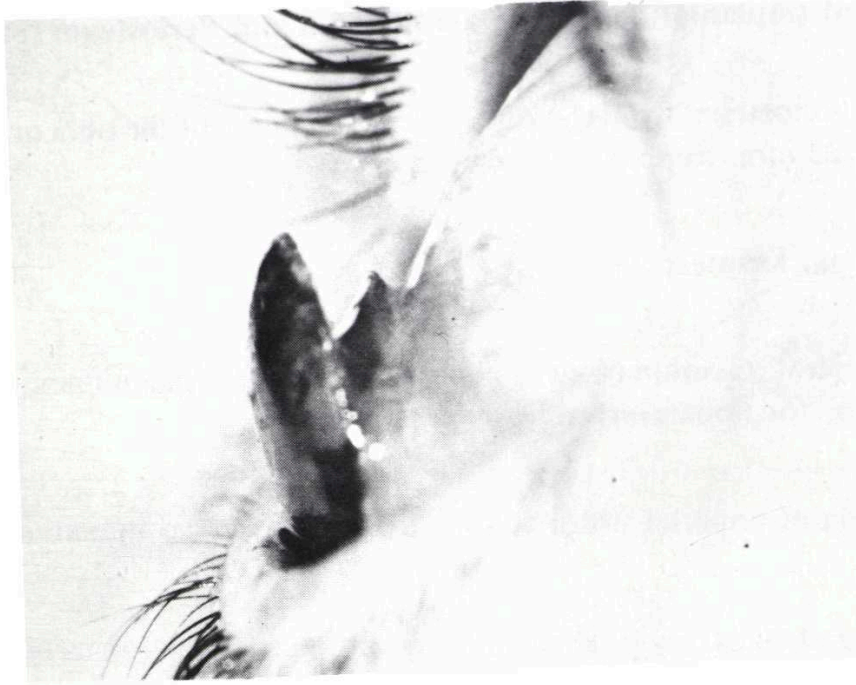

FIGURA 1

Queratoprótesis en un caso operado de queratitis bullosa, tres años de evolución con una visión de 20/40, comenzó a erosionar por la parte superior, la acción del párpado superior, ayudó a la expulsión.

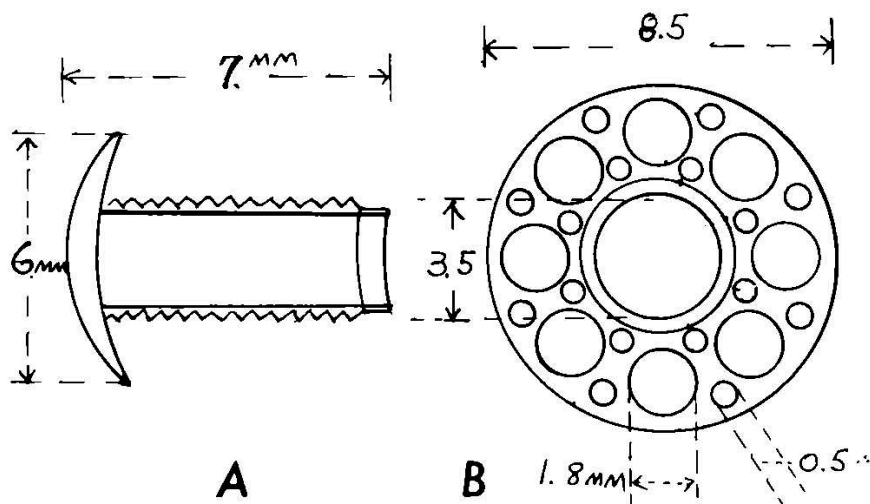


FIGURA 2

QUERATOPROTESIS, medidas más usadas, prototipo standard.

- A. El cilindro óptico está hecho de Metilmetacrilato, lleva una lente de contacto adherida en la parte anterior, la cual puede ser clara o coloreada.*
- B. Arandela de Teflon, con agujeros medianos en la periferia, y agujeros más pequeños alrededor del agujero central.*

Technique of Implantation using Dacron Mesh and Periosteum (See Fig. 3).

1. Obtain periosteum from the superior medial phase of the tibia or fascia lata using a 22 mm. trephine pipe or scissors.
2. Superficial Keratectomy.
3. Panforniceal resection of tarso-conjunctival layer in pemphigoid or dry eye syndrome for implantation through the eye lid.
4. Resection of upperlid obicularis if through the eye lid implantation.
5. Marking of visual axis and partial penetrating trephination using 3.0 or 3.5 mm. trephine.

(See Fig. 3A).

6. Corneal Scleral incisión and lensectomy.
7. Total iridectomy.
8. Total anterior vitrectomy when a vitreous cutting instrument is available.
9. Healon reconstruction of anterior vitreous.
10. Suturing of Teflon skirt over anterior surface of the cornea with interrupted mersilene. Align the central partial perforation of the cornea with the central hole of the Teflon skirt. Complete the partial trephination using sharp scissors and fine forceps.(See Fig. 3B).
11. Threading of the optical cylinder in situ.(See Fig. 3C).
12. Onlay of Dacron mesh over Teflon skirt and anchorage near horizontal recti muscles with 6-0 chromic dextron 7-0 sutures.

PROSTHOKERATOPLASTY

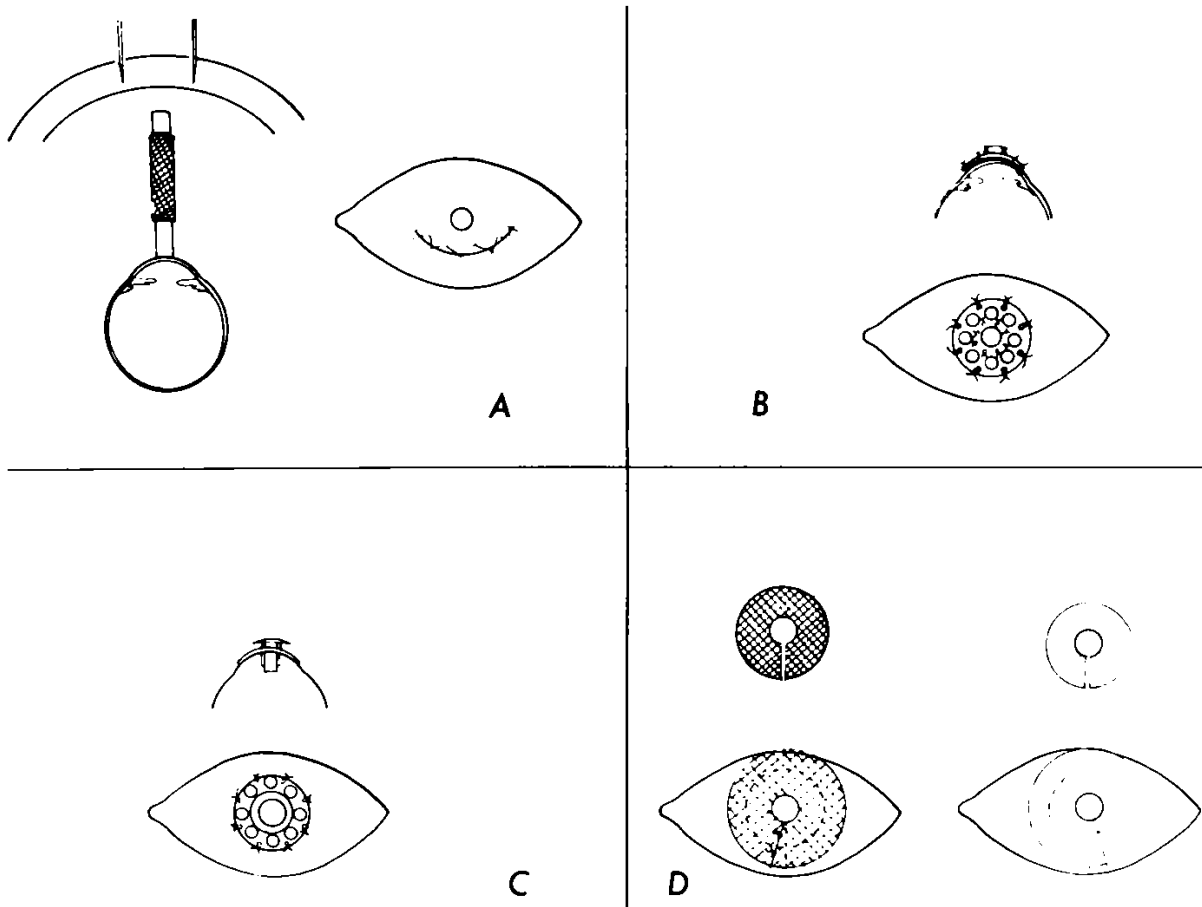


FIGURA 3

TECNICA DE IMPLANTACION, aspectos más sobresalientes.

- A. *Marcado del centro corneal, sobre el eje visual se hace una trepanación parcial con trépano de 3 mm o de 3.5 mm. Extracción de cristalino.*
- B. *Sutura de la arandela de Teflon, sobre la superficie anterior de la córnea suturas separadas por los agujeros externos y luego por los pequeños paracentrales. Con Mersilene No. 5 se termina la trepanación parcial central usando tijeras finas.*
13. **Suturing of fascia lata or periosteum over the Teflon skirt and Dacron mesh.(See Fig. 3D).**
14. **Closure of bulbar conjunctiva over fascia lata or periosteum.(See Fig. 4).**
15. **Total tarsorrhaphy in pemphigoid or dry eye syndrome.**

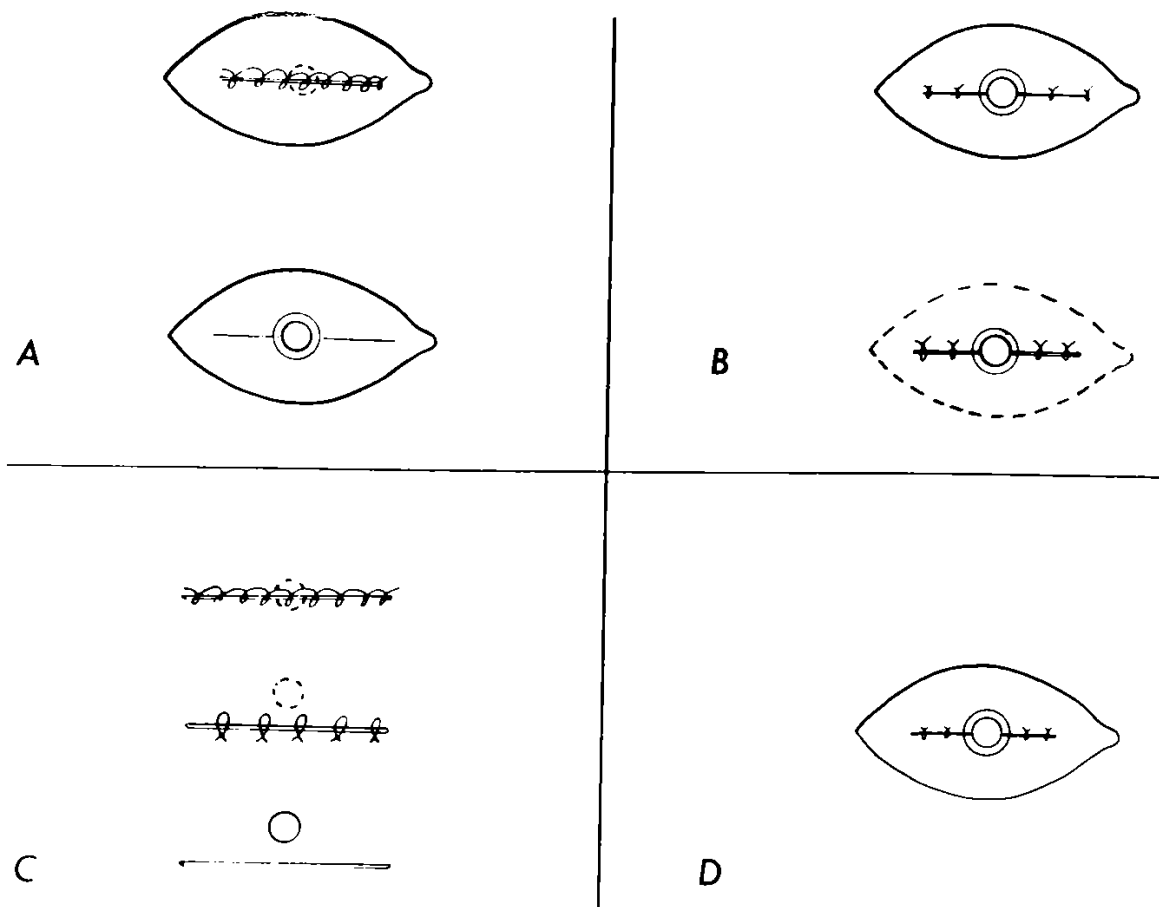


FIGURA 4

CIERRE.

- A. *Cierre de la conjuntiva sobre el cilindro óptico, en aquellos casos donde el tejido conjuntival lo permite. (Quemaduras químicas), esperar dos meses abrir la conjuntiva sobre la parte óptica.*
- B. *Cerrar conjuntiva, luego efectuar una tarsorrafía dejando el cilindro óptico en medio de los párpados en algunos casos de quemaduras químicas, u ojo penfigoide.*
- C. *Cierre de la conjuntiva. Total tarsorrafía. Haciendo pasar el cilindro óptico a través del párpado superior. Usado en penfigoide avanzado.*
- D. *Cierre de la conjuntiva, con puntos separados, alrededor del cilindro óptico, ayudado con una espátula, pasarla por debajo de la lentilla anterior. Usado cuando aún la conjuntiva conserva su aspecto normal, y hay un buen fluido lagrimal.*

PROSTHOKERATOPLASTY

Indications.

1. Chemical burns.
2. Ocular Pemphigoid.
3. Advanced dry eye syndrome.
4. Previous keratoplasty failure.
5. Trachoma.
6. Advanced Bullous Keratopathy.
7. Stevens-Johnson syndrome.

The following criteria must be met before prosthokeratoplasty is attempted: Standard keratoplasty failure, satisfactory functional capability, and lack of a functional fellow eye.

Visual Results

Visual results varied in different cases. The best results were obtained in cases of advanced ocular pemphigoid and advanced bullous keratopathy. Some cases have been so extraordinary that the patient has been able to read and see at a distance without the aid of corrective lenses. (See Fig. 5).

The least favorable results have been obtained in cases of chemical burns with a history of secondary glaucoma. (See Table 1).

TABLA No. 1

| | | Meses Resultado Visual Expulsión | | | |
|----|----------------------------|----------------------------------|---------|--------|---|
| | | Antes | Después | % | |
| 1 | Ojo penfigoide | 63 | P.L. | 20/0 | — |
| 2 | Queratoptia bullosa | 60 | P.L. | 30/30 | — |
| 3 | Queratoptia bullosa | 51 | M.M. | 20/20 | — |
| 4 | Quemadura química (álcali) | 51 | M.M. | M.M. | — |
| 5 | Trauma (explosión pólvora) | 46 | P.L. | 20/100 | — |
| 6 | Quemadura química (álcali) | 42 | P.L. | 20/200 | — |
| 7 | Opacificación trasplante | 42 | M.M. | 20/100 | — |
| 8 | Leucoma (ulcera corneal) | 41 | M.M. | 20/100 | — |
| 9 | Opacificación de trasp. | 39 | M.M. | 20/50 | — |
| 10 | Ojo seco simblefaron total | 38 | M.M. | 20/80 | — |
| 11 | Quemadura química (álcali) | 27 | P.L. | M. M. | — |
| 12 | Queratoptia bullosa | 16 | P.L. | 20/40 | — |

In operations where the prosthesis transverses the eyelid, exposing it to the air, drying of the surface results, and vision is useful, but does not extend beyond 20/80.

Complications

The most usual complication in the past has been erosion of the tissue around the cylinder and the subsequent extrusion of the prosthesis in 25% of the cases. This has not occurred in any of the twelve cases which have been operated with this new technique. However, in three cases it was necessary to reoperate the patient to add an additional layer of fascia lata where the first layer had dissolved. These cases were a chemical burn, a transplant failure in the third degree, and a scar trauma produced by gunpowder explosion. In one case, where the patient had a chemical burn complicated by secondary glaucoma (pre-op), vision did not improve.

Conclusion

This technique seems to offer a solution to the problem of extrusion of the prosthesis. The technique has been simplified greatly, and improved so that it is the same for both prototypes of prostheses.

The prototypes have been simplified to one standard type which can be used in all cases. There are two variations to this type and they are the clear flange model, which is generally used in through the eye lid operations or for chemical burns, and a colored flange model which immitates the iris to give a more aesthetic appearance to the eye. This model is mostly used in advanced bullous keratopathy and third transplant failure. However, either model can be interchanged.

Finally, it is no longer necessary to use special instruments. The only specific requirement is the use of a straight 3.5 or 3.0 mm. trephine.

PROSTHOKERATOPLASTY

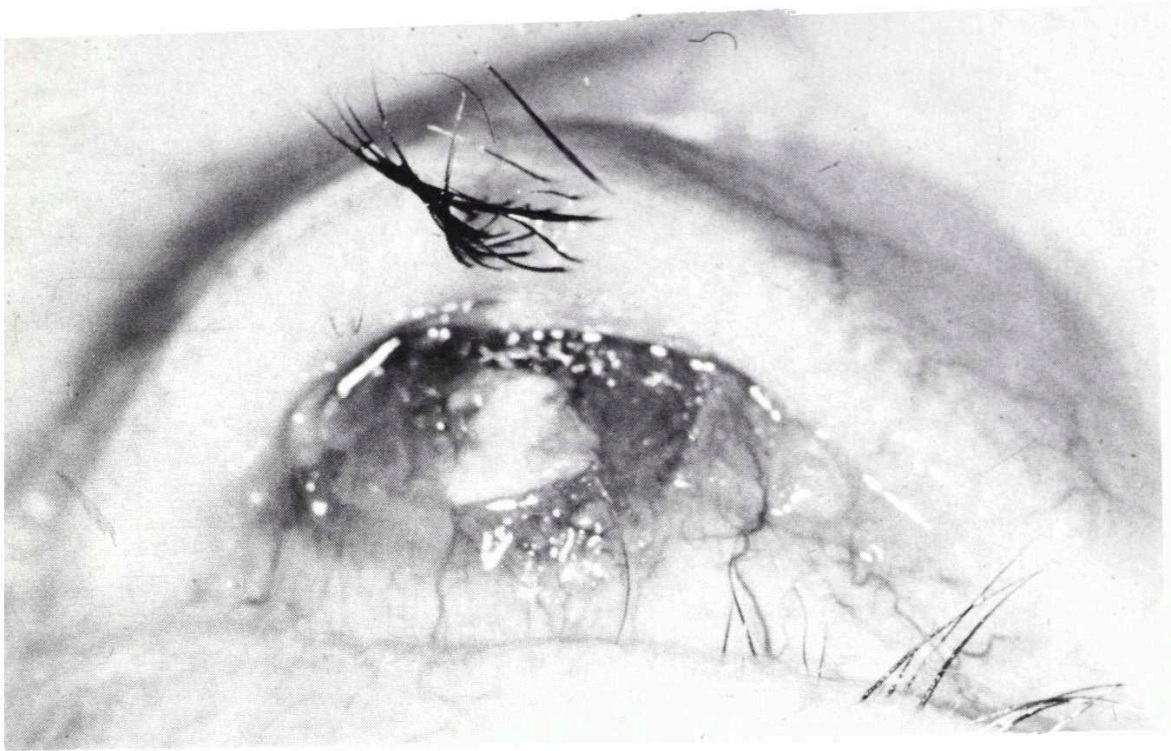


FIGURA 5 A

Ojo penfigoide antes de la operación. A.V. Mov. de mano.

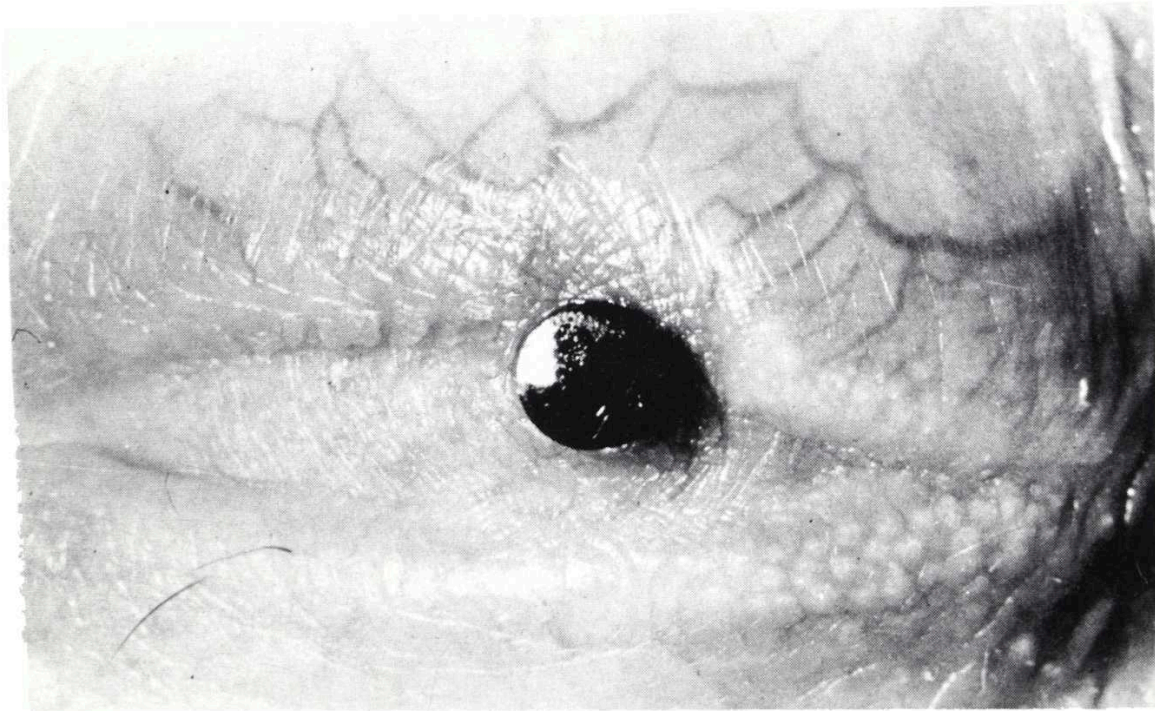


FIGURA 5 B

Después de la operación 4 años de observación, visión mejora a 20/60. Queratoprótesis implantada en medio de los párpados.

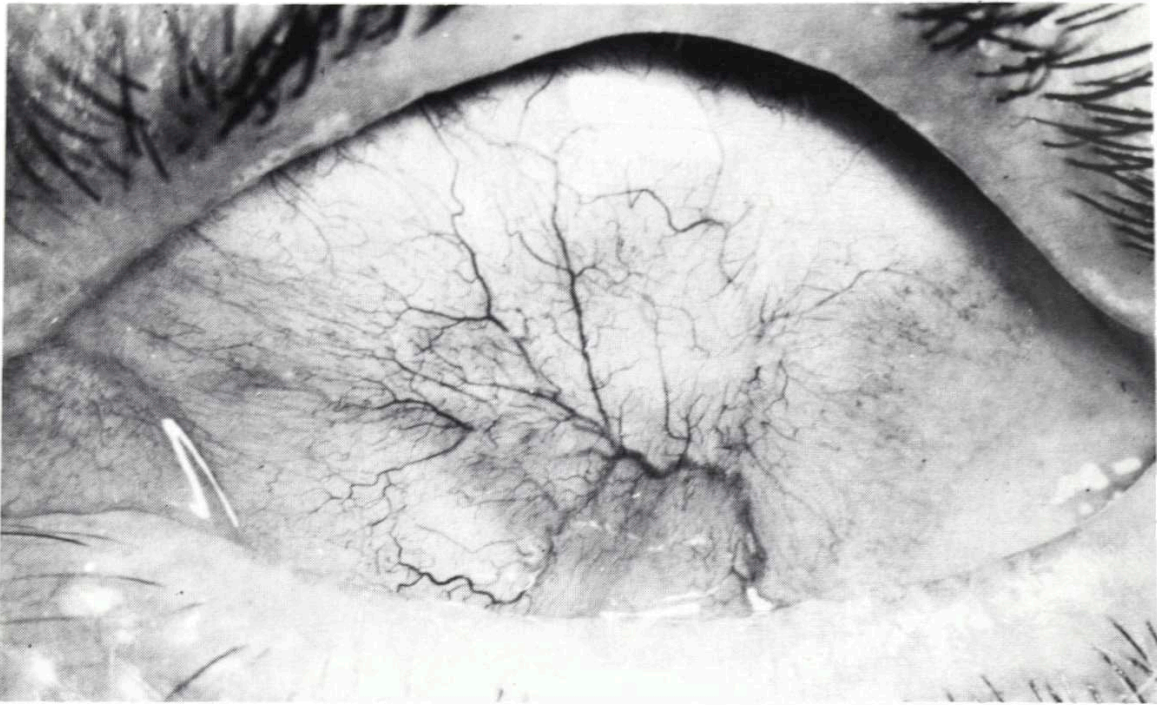


FIGURA 6 A

Quemadura química antes de la operación A.V. Percepción luminosa.

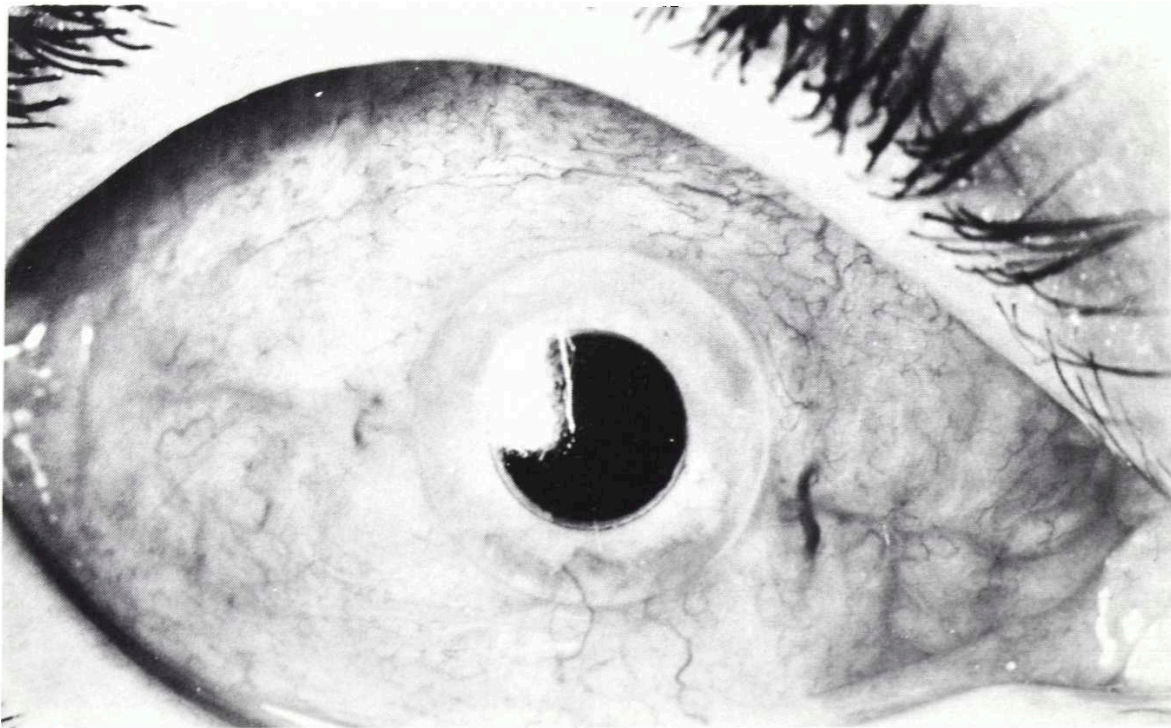


FIGURA 6 B

Dos años después, A.V. mejora a 20/40.

PROSTHOKERATOPLASTY

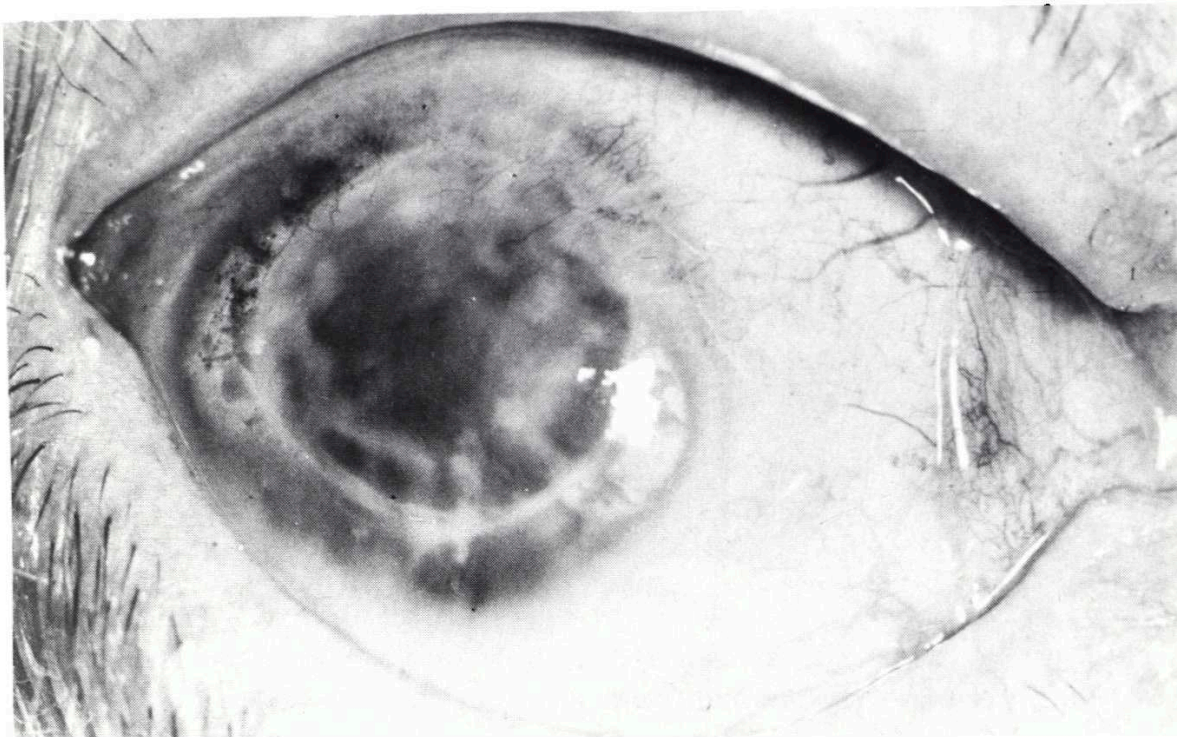


FIGURA 7 A

*Queratopatía bullosa avanzada tratada con trasplante de córnea, 3o. rechazo. A.V.
Percepción luminosa.*

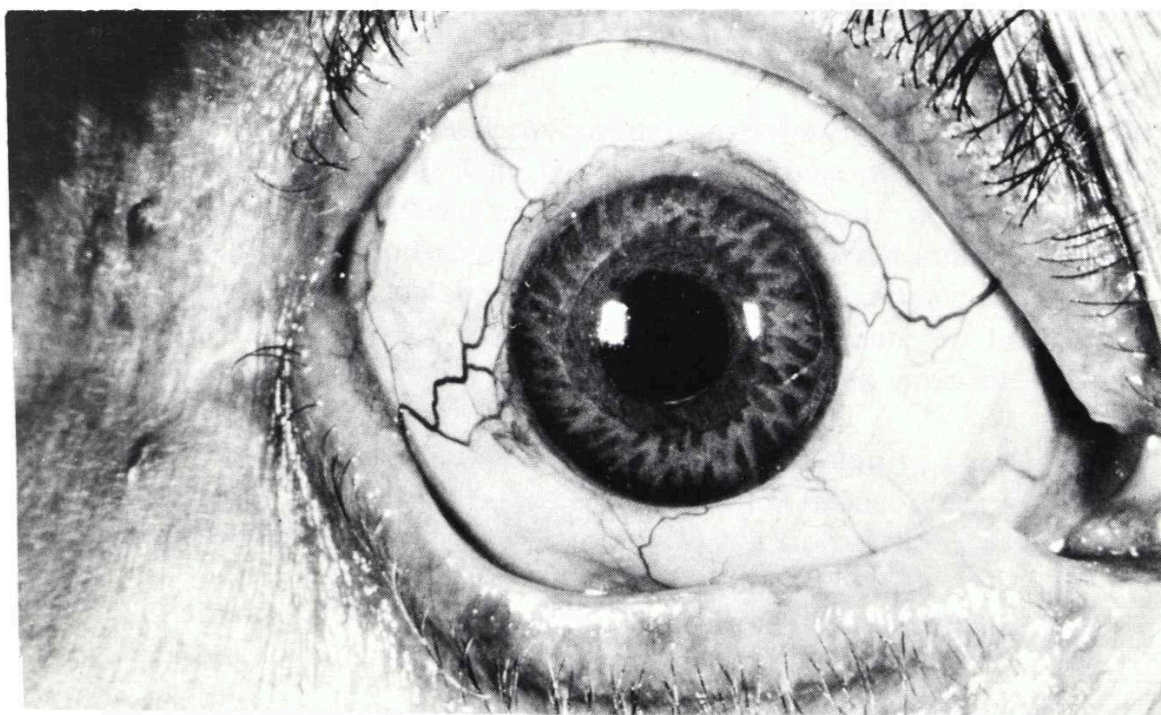


FIGURA 7 B

Después de la operación, cuatro años después visión mejora a 20/30.