

# Archivos de la S. A. O. O.



1. EDITORIAL .....	97
2. ARTICULOS ESPECIALES	
Complicaciones en la motilidad palpebral secundarios a traumatismos orbitarios <i>Enrique Alemán Hurtado</i> .....	101
Dificultades diagnósticas en neuro-oftalmología <i>Zoilo Cuéllar Montoya</i> .....	103
3. INVESTIGACIONES CLINICAS	
Quantitative evaluation of the effects of artificial tears on the corneal epithelium <i>Michael J. Doughty</i> .....	107
The turnover of cells of the Corneal Epithelium <i>Graeme Wilson</i> .....	117
Cambios refractivos inducidos por el uso de aceite de silicón en cirugía vitreo-retiniana <i>Hernando Camacho - Fabián Martínez - J. Fernando Arévalo - Zoilo Cuellar, Jr.</i> .....	119
The practice of Low Vision Care <i>Edward Goodlaw</i> .....	125
Corneal stability and topography after different refractive procedures <i>M. Kohlhaas - J. Draeger - A. Böhm</i> .....	129
4. INVESTIGACIONES QUIRURGICAS	
Lamellar Keratoplasties - First results with a new automatic microkeratome <i>M. Kohlhaas - J. Draeger</i> .....	134
Should we consider clear lens extraction for routine refractive surgery <i>Theodore P. Werblin</i> .....	139

# Archivos de la S. A. O. O.

Extensión del uso de la operación de Fasanella y Servat <i>Javier Servat U.</i> .....	142
Manual Extracapsular Surgery Mini Nuc Technique <i>Michael Blumenthal</i> .....	147
Estudio prospectivo del uso de heparina intraocular en cirugía vitreorre- tiniana con aceite de silicona <i>Gustavo Alvira Escovar - Camilo Jaramillo Villamizar - Fernando Arévalo Colina - Vilma María Mesa</i> .....	154
Cirugía convencional de desprendimiento de retina: Complicaciones <i>Ricardo Infante de Germán Ribón - J. Fernando Arévalo</i> .....	162
5. RESUMENES	
Mechanical arcuate keratome for naturally occurring astigmatism <i>Kalil Hanna - Dr. Culbertson</i> .....	172
Queratomileusis miópica por congelación, 10 años de experiencia <i>Iris Estrada Rodríguez</i> .....	173
Epimacular proliferation <i>Steve Charles</i> .....	174
6. ANUNCIOS .....	179

# Complicaciones en la motilidad palpebral secundarias a traumatismos orbitarios

Dr. Enrique Alemán Hurtado (\*)

Los traumatismos órbito-oculares representan el 0,5% del total de los traumatismos corporales, la frecuencia creciente de los accidentes de automóviles explica el incremento de los traumatismos faciales.

En el período comprendido entre 1975 a 1985 estudiamos en el Centro Oftalmológico Barraquer a un conjunto de traumatismos orbitarios con complicación palpebral que clínicamente diagnosticamos de:

Contusión orbitaria en 90 pacientes, los cuales presentaron como signo principal edema y hematoma palpebral de grado diverso, siendo por regla general la regresión simple, en algunos casos persistió una ligera ptosis que desapareció antes de 1 mes.

En 10 pacientes se observó la existencia de una ptosis secundaria permanente pasados seis meses de la contusión, siendo las causas:

La desinserción de los fascículos aponeuróticos del músculo elevador en cuatro pacientes, incidiendo especialmente con la contusión del borde orbitario superior en su tercio interno. Únicamente se observó la presencia de un tejido conectivo conjuntival que surge por detrás del reborde libre del párpado superior al intentar levantar el párpado; la ptosis es importante y existe una ausencia total de función en el músculo elevador.

Por lesión directa de la rama superior del III Par por afección neurológica se supone existió en seis

pacientes en los cuales no se apreció ninguna lesión palpebral que explique la ptosis que fue de grado variable, existiendo en todos los casos una hipofunción del músculo elevador del párpado.

**Heridas palpebrales sin pérdida de sustancia**, para este estudio las clasificamos en:

**Heridas superficiales** (afectan el plano cutáneo orbicular) las observamos en 37 pacientes y la conducta quirúrgica depende de la dirección de la herida. Cuando está en dirección horizontal (plano paralelo al pliegue cutáneo) la restitución muscular no es necesaria, debe suturarse la piel directamente con puntos separados de seda 7/0.

Si la dirección es vertical (plano perpendicular a la dirección de las fibras musculares y a los pliegues cutáneos) la reposición muscular es indispensable utilizando una sutura reabsorbible de 6/0. La piel es suturada independientemente con puntos sueltos de seda 7/0.

**Heridas profundas** (afectan el plano tarsal y conjuntival) recibimos 21 pacientes en esta situación y en todos existía la interrupción del borde libre palpebral.

La conducta quirúrgica en estas heridas palpebrales no complicadas está muy tipificada: la importancia del cierre por planos y la necesidad de material de sutura fino.

La técnica utilizada es la reposición en tres planos; la sutura debe iniciarse en el reborde palpebral, dando un punto a nivel de la línea gris y otro a nivel de la línea de las pestañas.

El plano tarsoconjuntival se cierra con puntos sueltos de material reabsorbible de 7/0, los nudos deben realizarse en la superficie anterior. El plano muscular se cierra mediante otros puntos sueltos de material reabsorbible de 6/0, y el plano cutáneo se sutura separadamente con seda de 6/0. Algunas heridas profundas no complicadas de los párpados producen lesiones por desgarro, en estas circunstancias es necesario alinear los bordes de los desgarros tarsal y cutáneo sacrificando tan poco tarso como sea posible.

**Arrancamiento y avulsión palpebral**  
tratamos dos pacientes provocados uno por accidente de circulación y otro por mordedura de un perro. El factor más importante en la reconstrucción de estas heridas es la identificación del muñón del tendón comisural. El tendón comisural debe reinsertarse por dentro del reborde orbitario y no en el reborde orbitario, para obtener una buena tensión palpebral y la sutura se realiza con material de sutura no reabsorbible o alambre fino del número 30.



# Dificultades diagnósticas en neuro-oftalmología

Zoilo Cuéllar - Montoya, M.D.(\*)

*Se presentan dos casos con patología neuro-oftalmológica en quienes, debido a errores clínicos, se retrasó el diagnóstico definitivo. No se puede afirmar que dicho retraso intervenga, en estos casos, en el pronóstico final, pero como hecho docente considero de gran importancia su discusión, con el fin de concientizarnos, nosotros los oftalmólogos, de la importancia de tener siempre en cuenta el componente neuro-oftalmológico de nuestro examen; el enfoque integral de cada caso.*

## Primer Caso

Mujer de 65 años que consultó por primera vez a los 63 años, a otro centro, por reducción de visión de su ojo derecho, miopía alta y ptosis del párpado superior izquierdo, aparecida dos años atrás. Se le encontró una ametropía miópica alta en los dos ojos, una catarata moderadamente densa en el ojo derecho y la ptosis del P.S.I., ya mencionada. Se intervino en ese centro de extracción extracapsular de catarata con implante de lente intraocular del O.D., con muy buenos resultados y, simultáneamente, se le practicó una resección externa del elevador del párpado superior del ojo izquierdo, también con buenos resultados. El 4 de enero de 1991 consultó de emergencia a un hospital general por cefalea súbita, intensa, de tres días de evolución, de predominio izquierdo, de tipo pulsátil. Se acompañaba de notoria diplopía horizontal y de importante endotropía del ojo izquierdo, las cuales habían aparecido al día siguiente de iniciarse la cefalea. Como antecedentes se encontró que se trataba de una paciente hipertensa, seguida durante los últimos

(\*)Sección de Oftalmología, Departamento de Cirugía, Fundación Santafé de Bogotá

15 años; fumadora; apendicectomizada y sometida a herniorrafia inguinal derecha.

Se internó en el hospital mencionado con un diagnóstico de impresión de parálisis del VI par izquierdo en estudio. Además de la parálisis mencionada se encontró que existía un síndrome de Horner del Ojo Izquierdo. Se practicó el estudio neurológico pertinente y, dentro de los exámenes realizados se encuentra el estudio de la motilidad ocular (Fig. 1), que muestra una ETI de 30 D.P. y una limitación total de la abducción del O.I.; y discreta ptosis del P.S.I.

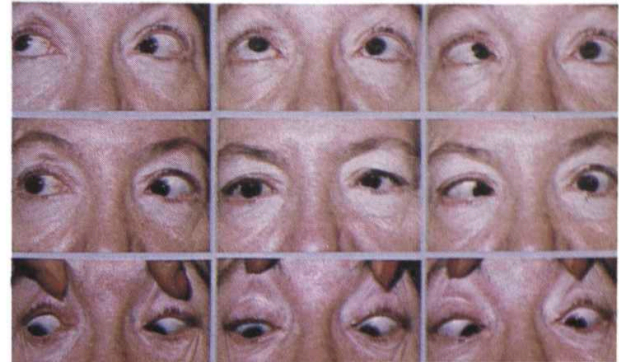


Fig. 1. Seriografía Primer caso. PP. ETI de 40 DP. Levoversiones: parálisis total del VI par izquierdo.

El *cover test* que muestra (Fig. 2) un ángulo secundario al fijar con el O.I. El estudio arteriográfico que muestra (Fig. 3) un aneurisma

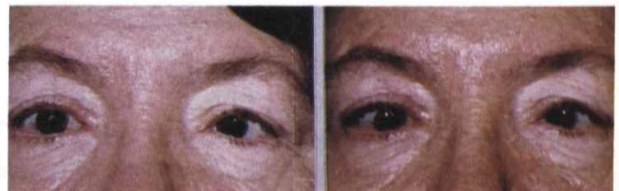

Fig. 2. "Cover uncover". Ángulo secundario fijando el Ojo izquierdo.

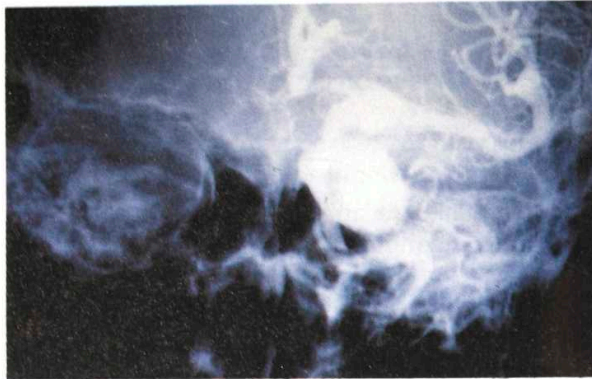


Fig. 3. Arteriografía. Aneurisma gigante de la carótida interna izquierda en el seno cavernoso.

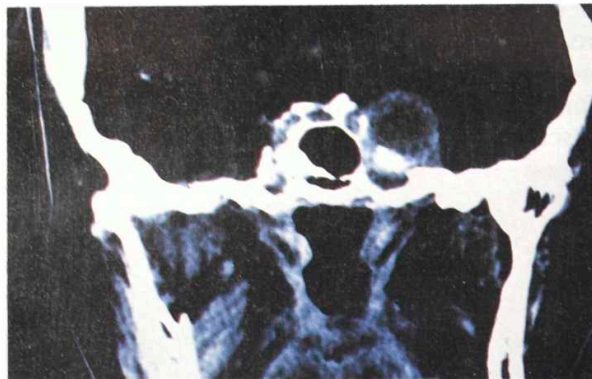


Fig. 4. T.A.C. Erosión notoria de la pared izquierda del seno esfenoidal y de las clinoides izquierdas.

gigante de la carótida interna izquierda en la región del seno cavernoso correspondiente, y la Tomografía Axial Computarizada (T.A.C.) (Fig. 4) que muestra la erosión que ocasiona el aneurisma en la pared lateral del seno esfenoidal y en las clinoides izquierdas.

## Discusión

Se trata de una paciente en quien aparece una ptosis del párpado superior izquierdo a los 61 años y en la que, si el estudio neuro-oftalmológico hubiera sido más cuidadoso, se hubiera encontrado que la ptosis hacía parte de un síndrome de Horner del Ojo Izquierdo. Constituye lo que se ha

denominado el segundo síndrome del sexto par caracterizado por lesión de esta estructura a nivel de su cruce con la carótida interna, que lleva el contingente simpático para el ojo, en la parte posterior del seno cavernoso<sup>1, 4, 6, 8</sup>. Al haber sido adquirido dicho síndrome después de los 60 años se hubiera podido pensar en la existencia de algún tipo de patología intracraneal que lo explicara. Aún sin el diagnóstico de síndrome de Horner y sólo con la aparición de ptosis de uno de los párpados en una persona mayor, se debía haber sospechado una patología neurológica. El VI par se halla incluido en el seno cavernoso y en la región posterior de esta estructura se encuentran las fibras simpáticas para el Ojo. En esta forma, la coexistencia de parálisis del VI par y Horner del mismo lado, indica la presencia de una lesión en la parte posterior del seno cavernoso. Al iniciarse el sangrado del aneurisma se precipitó, junto con la cefalea intensa, la parálisis del VI par del lado afectado. El pronóstico quizás no hubiera cambiado, pero también es posible que, ante un diagnóstico oportuno, un mayor control de la hipertensión arterial hubiera diferido la hemorragia y el accidente agudo.

## Segundo Caso

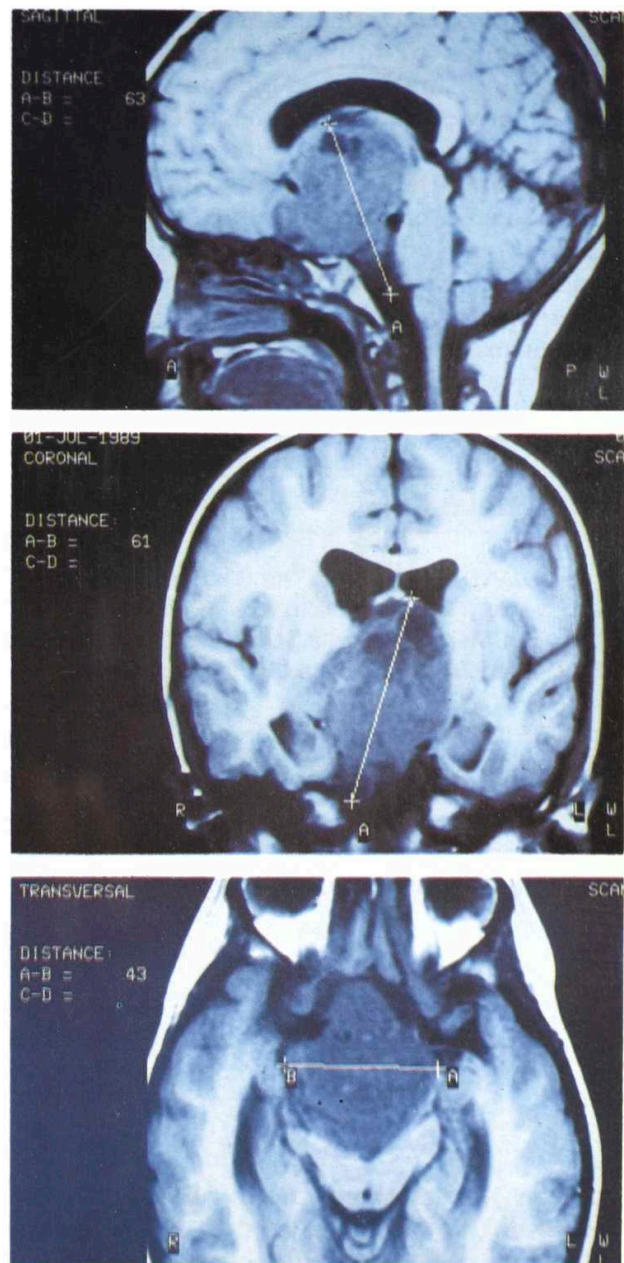
Niña que a los dos años de edad consultó por primera vez a otro centro por exotropía derecha y movimientos nistárgmicos del O.D. de tres meses de evolución. Como antecedentes reseña parto por cesárea y la existencia de estrabismo en un primo hermano. El examen funcional bajo cicloplejia muestra una hipermetropía de +2.50 en el O.D. y de +2.00 en el O.I. El examen estrabológico previo a la cicloplejia muestra una XTD con mala alternancia, ausencia de punto próximo de convergencia y nistagmus vertical del O.D. Se reporta una discreta palidez en los discos ópticos y una fijación paracentral, nistárgmica, en el O.D. Se ordena oclusión alternante de 1 x 1 y se controla nuevamente 4 meses después, anotándose en la historia clínica que no existe cambio en la situación



estrabológica. Un mes después es hospitalizada de urgencia en un centro neurológico por cefalea progresiva, cada vez más intensa, y por vómito fácil no relacionado con ingesta. En esta ocasión se encuentra una hipertensión endocraneal y la Resonancia Nuclear Magnética muestra (Figs. 5, 6 y 7) una inmensa masa en región quiasmática que deforma las estructuras vecinas. Es llevada a cirugía y el estudio anatomopatológico del espécimen obtenido demuestra que se trata de un astrocitoma anaplásico del quiasma óptico.

### Discusión:

Se trata de una paciente en quien se encuentra una exotropía derecha y un nistagmus monocular vertical de este ojo, adquiridos tres meses antes de la consulta y a quien se hace un diagnóstico de exotropía y se trata como tal, incluyendo oclusión. La aparición de un nistagmus monocular en un niño debió haber llamado la atención al oftalmólogo sobre la posible presencia de una patología neurológica que explicara el hecho. "Recomendamos - dicen Farmer y Hoyt en su artículo de octubre de 1984 - *que todos los bebés y niños pequeños con nistagmus monocular o las otras formas de spasmus nutans deben ser evaluados con TAC*"<sup>5</sup>. Dicha afirmación se debe a la similitud entre las dos entidades, sobre todo con aquellos casos de *spasmus nutans* en los cuales el nistagmus, en vez de ser bilateral y asimétrico, es claramente monocular. El *spasmus nutans* es una entidad absolutamente benigna, en tanto que el caso que nos ocupa es de pronóstico notablemente reservado. Estos autores, de 11 niños con nistagmus monocular evaluados por ellos, encontraron 6 que presentaban un tumor quiasmático. Dicha entidad, además, está asociada siempre a notoria reducción de la visión del ojo más afectado y la exotropía es frecuente por disociación de la fusión ocasionada por la reducción visual monocular en un niño previamente sano<sup>3,9</sup>. No debe ser confundida la manifestación nistágmica de esta entidad con las que se encuentra en la ambliopía - Fenómeno de



Figs. 5, 6 y 7.R.N.M.- Gigantesca lesión ocupando espacio en región de quiasma óptico.

Heimann-Bielschowsky-. Este fenómeno estrabológico puede ser confundido con un signo neurológico de lesión de fosa posterior o de tronco cerebral, o con el caso que nos ocupa. Se trata de

un movimiento estrictamente monocular, con oscilaciones pendulares verticales que se presentan solamente en el ojo ambliope de larga data. Aparece fundamentalmente en fijación de lejos y se inhibe al fijar en convergencia<sup>10, 2, 7</sup>. Nace la pregunta si, ante un diagnóstico adecuado realizado en la primera consulta, casi 6 meses antes del episodio agudo de hipertensión endocraneal, se hubiera podido actuar en forma más oportuna, permitiendo al cirujano realizar una ablación más completa de la lesión tumoral y dando a la pequeña paciente un pronóstico visual y de supervivencia algo mejor que el actual.

## Referencias

1. BAJANDAS, Frank J. The Six Syndromes of the Sixth Nerve. *Neuro-ophthalmology Update*. J. Lawton Smith, Edit. Masson Publishing USA, Inc. New York - Paris - Barcelona - Milan. 1977; pp. 54 - 58.
2. BEILSCHOWSKY, A. Die einseitigen und gesinnigen ("Dissoziierten") vertikalbewegungen der augen. *Arch. Ophthalmol.* 125: 439 - 553. 1931.
3. DONIN, J.F. Acquired monocular nystagmus in children. *Can. J. Ophthalmol.* 2:212. 1967.
4. DUKE-ELDER, S. Sir. and SCOTT, G.I.(b) The cavernous syndrome...IV. Trunk Palsies. Acquired Ocular Motor Paralysis. Ocular Dissociations. The motor System. *Neuro-Ophthalmology*. In: *System of Ophthalmology*. Sir Stewart Duke-Elder, ed. Henry Kimpton, London. Vol. XIII. 1971. p. 744.
5. FARMER, J. y HOYT, C.S. Monocular Nystagmus in Infancy and Early Childhood. *Am. J. Ophthalmol.* 98(4): 504-509. October, 1984.
6. GUTMAN, L., LEVARTOVSKI, S., GOLDHAMMER, Y., TADMOR, R. and FINDLER, G. Sixth Nerve Palsy and unilateral Horner's Syndrome. *Ophthalmology.* 93(7): 913-916. July, 1986.
7. HEIMANN, R. Einseitiger Nystagmus. *Klin. Monatsbl. Augenheilkd* 49: 99-105. 1902.
8. RUSH, J.A. and YOUNGE, B.R. Paralysis of cranial nerves III, IV and VI. Cause and prognosis in 1000 cases. *Arch. Ophthalmol.* 99: 76 - 79, 1981.
9. SCHULMAN, J.A., SHULTS, W.T. and JONES, J.M., Jr. Monocular vertical nystagmus as an initial sign of chiasmal glioma. *Am. J. Ophthalmol.* 87(1): 87 - 9. January, 1979.
10. SMITH, J.L., FLYNN, J.T. and SPIRO, H.J. Monocular Vertical Oscillations of Amblyopia. *J. Clin. Neuro-Ophthalmol.* 2(2): 85 - 91. June, 1982.

# Quantitative evaluation of the effects of artificial tears on the corneal epithelium

Michael J. Doughty(\*)

---

## Abstract

---

Two drops of a chlorobutanol --or benzalkonium chloride-- preserved artificial teardrops were instilled in to the right eye of six female grey rabbits (2 kg) at 21.00 and 09.00. A group of six control animals received no eyedrops. The animals were euthanized at 15.00 h and the central region of the corneal epithelium assessed by scanning electron microscopy using a digitizer pad/computer system. After recovery from the exposure to artificial teardrops, there were up to 2% exfoliating cells evident at the ocular surface but with no difference between the two products; controls had no cell exfoliation. After recovery from the chlorobutanol-preserved artificial tears, the distribution of surface areas of the squamous cells (n = 500 cells evaluated) was shifted to slightly larger values compared to controls but the number of epithelial cell craters /cell was unchanged from controls. Following recovery from benzalkonium chloride-preserved artificial tears, the cell areas were shifted to significantly smaller values than controls and there were fewer epithelial cell craters/cell. The methods and assessment protocol are presented as a basis for objectively comparing different types of eyedrops on the corneal surface where there is no overt cytotoxicity.

---

---

## Introduction

---

The use of artificial tear pharmaceuticals in patients with irritated or dry eyes is commonplace<sup>1</sup>. Those pharmaceutical products that are intended to be used many times by a patient (e.g. 5 mL multi-use bottles of eyedrops) will usually contain pre-

\* University of Waterloo, School of Optometry, Waterloo, Ontario, Canada N2L 3G1.

servative agents. These preservative agents are included so as to reduce the risk of substantial multiplication of most microorganisms should the container or the actual solution become accidentally contaminated with microorganisms such as bacteria or fungi. A large number of these chemical preservative agents have been tried over the last 40 years<sup>2,5</sup>. Several of these agents have become widely used and have an acceptable record of effi-

efficacy in maintaining the sterility of eyedrops<sup>6,8</sup>. Significant microbial growth can occur however, presumably if the level of pathogen contamination is high or there is repeated exposure of the eyedrop container to the pathogen(s).<sup>6,8</sup> As a consequence, it is necessary that the concentrations of chemical preservative agents included in the pharmaceuticals be sufficiently high so as to be able to effect as rapid inactivation or destruction of the microorganisms as possible. However, in deciding on the concentration of the preservative agent that is to be included in the eyedrops, consideration must be given to the potential cytotoxic effects of the preservative agent on the tissues of the eye, especially the corneal and conjunctival epithelia. As a result of these considerations, it can be stated that the overall toxicity risk, with the most commonly used concentrations of these preservative agents, is very low. That this statement is a valid reflection of the use of preserved eyedrops comes from the overall scarcity of reports on complications (that could be attributed to cytotoxic effects or even microbial contamination) arising from the use of such eyedrops. This overall situation needs to be carefully distinguished from the occasional occurrence of allergic or hypersensitivity reactions to preservatives (e.g. thimerosal<sup>9</sup>) or any other ingredients of the eyedrops.<sup>10</sup> Despite this repeated use of multiple-use eyedrop products without consequence, preservative agents continue to receive adverse publicity. Part of the reason for this situation is that there is only limited information on the effects of these preservatives on the ocular surface of the living eye.

Scanning electron microscopy has been used for many years to evaluate the effects of numerous chemicals (including preservative agents), drugs and pharmaceuticals on the surface of the corneal epithelium.<sup>11,12</sup> For the most part, the technique has been used to provide high magnification images of the actual cells at the epithelial surface.

The images have been only subjectively assessed in most cases. Furthermore, the technique has

been largely used to only document the cellular damage or cell exfoliation that can occur within an hour of application of the test substance to the ocular surface. Scanning electron microscopy can however also be used to provide images of the mosaic of cells at the epithelial surface that can then be subjected to a quantitative analysis by planimetry. Discrete cell changes and low levels of cell exfoliation associated with artificial tear use have been quantified in this way<sup>13,14</sup>.

Overall however, despite the large number of published papers reporting the effects of preservative agents on the corneal epithelium (as assessed by scanning electron microscopy<sup>12</sup>), few of the studies compare preservative agents under conditions resembling clinical use of eyedrops and none of these comparative studies has been quantitative.

In the present study, an objective comparison was made of the effects of an exposure of the corneal epithelium *in vivo* to two different preservative agents included in the same type of polyvinyl alcohol-based eyedrop. Particular attention was given to the extent of cell exfoliation,<sup>14</sup> the surface areas of the residual squamous cells<sup>13</sup> and a cell surface feature that is often called the epithelial hole or crater.<sup>15-18</sup>

---

## Materials and methods

---

### *Animals and treatment protocols*

Female grey (Dulch Belt) rabbits were housed individually in Canadian Council for Animal Care (CCAC) -approved cages and quarters and provided with unrestricted access to food and water. All procedures were reviewed by and approved by the local, CCAC -approved animal care committee. The animals were first acclimatized to the University facilities for 7 to 9 days after receipt from a local supplier. An artificial light: dark cycle of 14:10 h was imposed with the light cycle starting at 06.00. After acclimatization, the animals (2.0 to 2.2 kg) were checked by slit-lamp biomicroscopy

and assigned to control or test groups. The test animals received two drops of an artificial tear solution in the right eye only at 21.00 local time and the eyedrop instillation was repeated at 09.00 the following morning. Control animals received no eyedrops. At 15.00 h (i.e. 6 h after the instillation of the second set of eyedrops for the test animals), the rabbits were euthanized with an overdose of T-61 euthanasia solution (0.5 mL/kg) administered via a peripheral ear vein. The right eye was used for the electron microscopy studies.

#### *Preparation of corneas for scanning electron microscopy*

Immediately after euthanasia, all neck blood vessels were severed and the animal drained over a sink about 30 s. With the animals then placed on their left side, two drops of a glutaraldehyde fixative solution were carefully applied to the surface of the right eye. The lids were then resected to the orbital rim, two more drops of fixative applied and the eyeball carefully enucleated. The corneas were then prepared for scanning electron microscopy as previously detailed<sup>12</sup>. In brief, the technique involves the occasional application of drops of the fixative solution to the surface of the eyeball over a period of 70-80 min at room temperature before the aqueous humor of the eye was replaced with fixative solution and the cornea excised on a scleral rim. The fixative was a freshly prepared solution of 2% w/v glutaraldehyde in 80 mM sodium cacodylate buffer and was warmed to 35 to 36°C just before use. The pH was adjusted to 7.2 to 7.4 with a few drops of dilute hydrochloric acid. The final solution osmolarity was 330-340 mOsm/kg and ultraviolet absorbance spectroscopy was routinely used to check that the polymer content of the fixative was less than 5%<sup>19</sup>.

#### *Scanning electron microscopy and image analysis*

Six corneas were successfully processed for each of the three experimental groups (controls, chlorobutanol-preserved eyedrops and benzalko-

nium chloride-preserved eyedrops). From three of the corneas in each group, the inferior-nasal quadrant was taken for analysis and the superior-temporal quadrant was taken from the other three corneas in each group. Scanning electron microscopy was performed using a Hitachi S570 microscope operating at 15kV. From each quadrant, a series of micrographs were taken at a position close to the apex of the quadrant, i.e. within 1.5 mm of the true apex of the corneal surface. The micrographs were all taken at a working distance of 8 mm and with the epithelial surface normal to the electron beam (to within  $\pm 5^\circ$ ). All micrographs were identified only by a number code at the time of the assessments being made. Micrographs were taken at 200 X at-stage magnification and printed at 10 x 8 inches to allow assessments of approximately 0.35 mm<sup>2</sup> portions of the corneal surface. From these micrographs, assessments were made of any regions of the ocular surface where any form of cell damage or abnormality was evident. These regions of approximately 0.06 mm<sup>2</sup> were quantitatively assessed by manual planimetry<sup>13</sup> using a commercial digitizer pad and computer software (Bioquant IV, R & M Biometrics, Nashville, TN). Micrographs were also taken at 500 X at-stage magnification (and also printed at 10 x 8 in) from the same portion of the corneal surface. These micrographs were used to measure the surface area of a total of 500 to 550 squamous cells from each experimental group (i.e. approximately 90 cells/corneal quadrant) by use of the digitizer pad system<sup>13</sup>. All surface area values were corrected for fixation and processing related tissue shrinkage as previously detailed<sup>13</sup> and only groups of fully tessellated cells were used in these morphometric analyses. Finally, from micrographs taken at 500 X magnification, a count was made of the number of crater-like surface structures on the surface of the 500 to 550 cells used for surface area measures. Only those crater-like structures that had a conspicuous collar or rim<sup>16,17</sup> were included in the counts.

#### *Chemicals and pharmaceuticals*

All chemicals used for the electron microscopy were of the highest purity grade available and were



obtained from J.B.E.M. Inc, Larval, Quebec. All solutions were prepared in double-distilled water. The artificial tear products were kindly provided by Allergan Inc (Canada). The LIQUIFILM TEARS™ products contain 1.4% polyvinyl alcohol and were preserved with either chlorobutanol or benzalkonium chloride.

## Results

### *Scanning electron microscopy evaluation of the corneal surface at 1000 X at-stage magnification*

Illustrated in (Figure 1) are representative micrographs showing the appearance of the normal corneal epithelial surface at 1000 X and 5000 X at-stage magnification. These magnifications were chosen since they allow resolution not only of the cell-cell borders and epithelial craters but also the actual surface features of the cells. The epithelial surface can be seen to be composed of a continuous mosaic of cells that appear to be in very close contact or apposition to one another. The cell surfaces are decorated both with a uniform mosaic of microplicae (with only occasional solitary microvilli) and the epithelial craters. These micrographs are presented to show that the epithelial

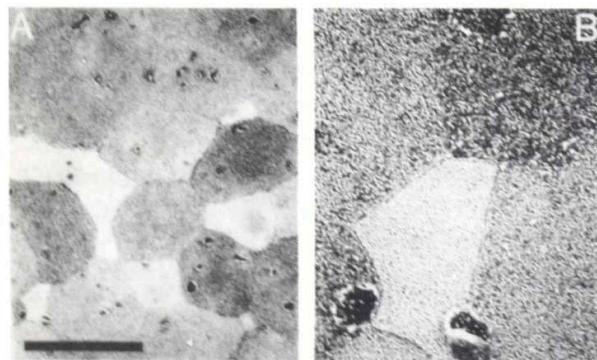


Figure 1 Representative scanning electron micrographs taken from the close to the apex of the normal rabbit corneal epithelial surface in the superior-temporal quadrant. (A) 1000 X, (B) 5000 X, bar indicates 42 and 8.4 μm respectively in A and B (corrected for tissue shrinkage)

surface is qualitatively similar when compared with eyedrop-treated epithelia. The micrographs are representative not only of the samples studied for each group but also of the corneal surface at mid-peripheral and peripheral sites as well.

### *Quantitative evaluation of cellular exfoliation or other alterations of the epithelial surface evaluated at 200 X and 500 X magnification.*

Micrographs taken at 200 X magnification were used to assess the presence of any gross alteration in the epithelial surface. The results are presented in (Table 1). The analyses show that the corneal surface appeared to be largely uncompromised by the exposure to the preservative agent-containing eyedrops. The incidence of exfoliating or otherwise abnormal cells averaged only 3.5% and did not exceed 5%. No difference was seen between the two treatments. From micrographs taken at 500 X magnification, occasional exfoliating cells were evident in addition to the occasional cell that showed evidence of partial surface disruption

	DAMAGED REGIONS (Percentage of epithelial surface analyzed)	NUMBERS OF EXFOLIATING CELLS (Percentage of cells analyzed)
Controls	0.26 ± 0.11	0.42 ± 0.07
Chlorobutanol	2.36 ± 0.95	1.70 ± 0.26
Benzalkonium	1.07 ± 0.72	2.11 ± 0.34

6 micrographs were evaluated for each set of data (means ±SD)

nucleus changes or had uplifted edges (suggestive of the initial phases of exfoliation). Three examples are illustrated in (Figure 2) and the numbers of such cells detailed in (Table 1). For control corneas, only 1 of 510 cells analyzed was designated as being abnormal. Both of the treatments with



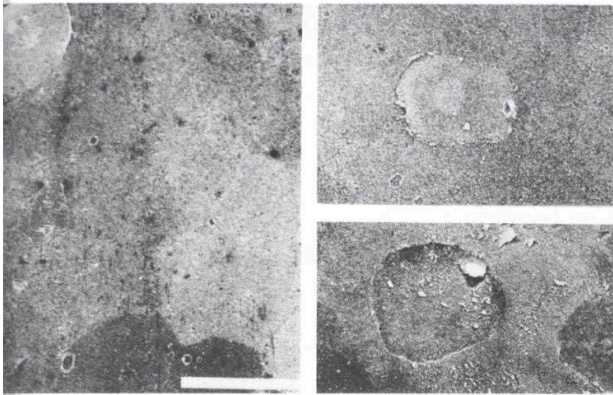


Figure 2 Scanning electron microscope images of the corneal surface to illustrate the appearance of isolated exfoliating cells observed after treatment with either of the eyedrops. For quantification, see Table 1. Bar indicates 42  $\mu$ m (corrected for tissue shrinkage).

artificial tears resulted in the appearance of small numbers of exfoliating or abnormal cells. The relative incidence of these cells was however very low when assessed as a percentage of the approximately 500 cells that were analyzed from the 6 micrographs of each test group, i. e., 1.7% and 2.1% respectively for the chlorobutanol and benzalkonium preserved artificial tears respectively

*Qualitative evaluation of the appearance of the epithelial surface after exposure to artificial teardrops.*

In Figure 3 and 4 are illustrated representative scanning electron micrographs of the corneal epithelial cells obtained 6 h after the exposure to artificial tears containing chlorobutanol (Figure 3) or benzalkonium chloride (Figure 4). For the chlorobutanol - exposed epithelia, the electron microscope image was routinely of relatively low contrast compared to controls (compare Figure 1A with Figure 3A) but the cell - cell borders were still evident and there was little evidence of cell damage etc. The main reason for the low contrast image is that the surface of many of the cells was routinely found to be covered with small to large quantities of an amorphous material. However, that

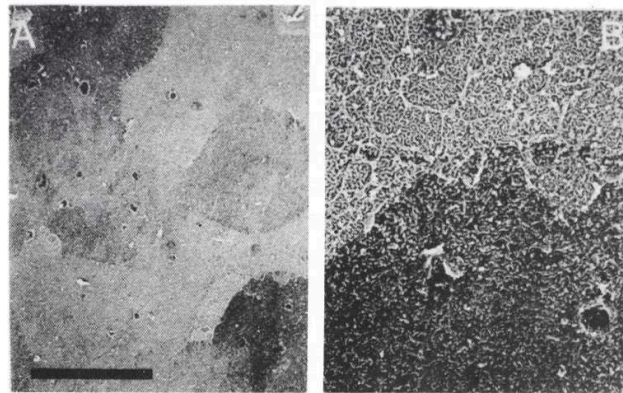


Figure 3 Representative scanning electron micrographs taken from close to the apex of corneas 6 hours after exposure to two sets of eyedrops preserved with chlorobutanol. Other details as Figure 1.

this is just a superficial coverage (perhaps of degraded mucins) is evident from the higher magnification images (Figure 3B) which clearly show the presence of normal - appearance microplicae on the cell surface. Following recovery from the benzalkonium chloride treatment, the electron images all showed less contrast than controls (compare Figure 1A with figure 4A) but the image quality was generally superior to that seen following the chlorobutanol exposure. The cell - cell borders were well resolved and the cell surface features such as the microplicae largely unchanged (Figure 4B)

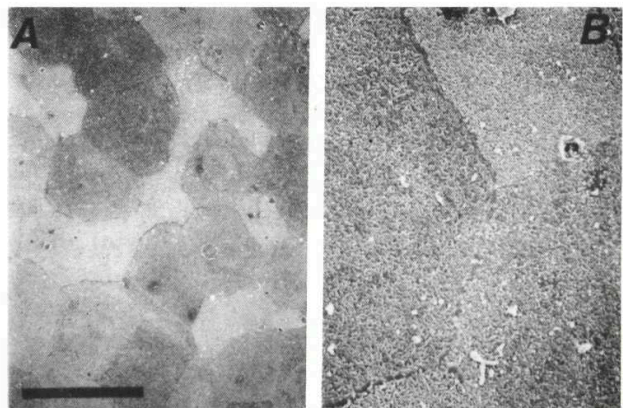


Figure 4 Representative scanning electron micrographs taken from close to the apex of corneas 6 hours after exposure to two sets of eyedrops preserved with benzalkonium chloride. Other details as Figure 1.

*Evaluation of surface areas of squamous cells after exposure to artificial tears*

From each set of 6 micrographs of part of the central region of the corneal epithelial surface, a total of 500 to 550 cells were digitized. Examples of tracing overlays of the cell borders are given in (Figure 5) to illustrate the overall effect observed. The squamous cells appear to have a similar range of sizes when the control micrograph (Figure 5A) is compared to the micrograph from a chlorobutanol-treated epithelium (Figure 5B). The squamous cell of the corneal epithelium treated with benzalkonium chloride however were generally smaller (Figure 5C).

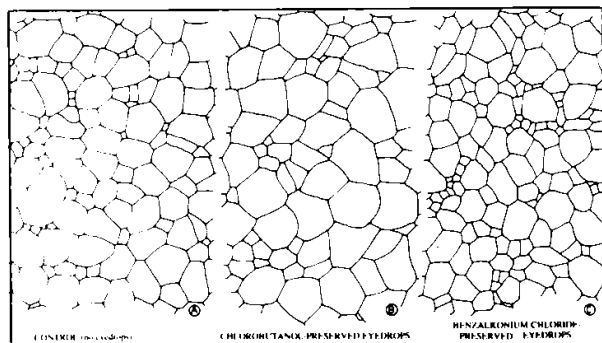


Figure 5. Representative tracing overlays made from scanning electron micrographs to illustrate differences in cell sizes between controls (A; from Figure 1A), Chlorobutanol -exposed epithelia (B; from Figure 2A) and benzalkonium chloride-exposed epithelia (C; from Figure 4A).

Morphometric measures and analyses provide an unambiguous documentation of the change in surface areas of the squamous cells. These results are presented in (Figure 6). For each group of corneas, the cell area data was pooled. A histogram of the cell surface areas from the control group (Figure 6A) reveals a wide range of cell sizes from  $<50 \mu\text{m}^2$  to  $2127 \mu\text{m}^2$ . The distribution is clearly skewed to larger cell areas and is clearly non-Gaussian. The average cell area ( $n = 510$ ) was  $525 \mu\text{m}^2$  and the median cell area was  $388 \mu\text{m}^2$ . Following recovery from the two sets of exposure to the chlorobutanol-preserved artificial teardrops, a similar range of cell sizes was observed, i.e.  $<50$

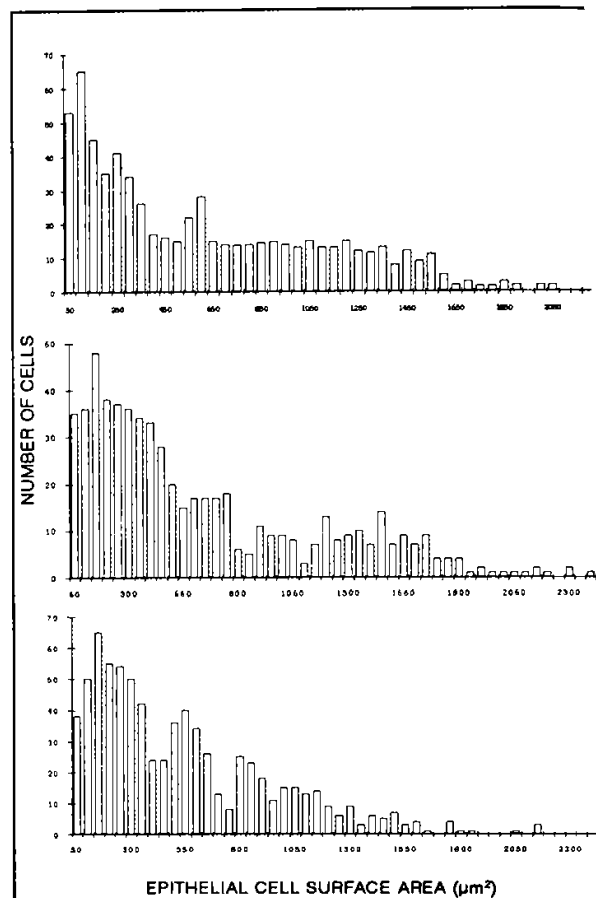


Figure 6. Histograms to illustrate distributions of squamous cell sizes at the corneal epithelial surface. The data was pooled from 6 corneas for each group and the cell surface area values are corrected for tissue shrinkage. (A) control corneas, (B) chlorobutanol - exposed corneas, (C) benzalkonium chloride - exposed corneas. Other details as Figure 1

to  $2410 \mu\text{m}^2$  (Figure 6B). However, the distribution was now not only skewed to larger areas but showed clear indications of bimodality with peaks at both  $150 \mu\text{m}^2$  and around  $1500 \mu\text{m}^2$ . The number of cells with surface areas of  $199 \mu\text{m}^2$  or smaller was clearly less than that seen in the control group. The mean cell area ( $n = 536$ ) was slightly larger than controls at  $537 \mu\text{m}^2$  but the median cell area was  $353 \mu\text{m}^2$ . A rather different histogram was obtained for the squamous cell surface areas after recovery from two exposures to the benzalkonium

chloride-preserved artificial teardrop (Figure 6C). While essentially the same range of cell sizes was observed (i.e.  $<50$  to  $2179 \mu\text{m}^2$ ), there were fewer cells with areas over  $1100 \mu\text{m}^2$ . This change was accompanied by the appearance of a higher number of cells with areas between  $200$  and  $899 \mu\text{m}^2$ . As an overall result, the average cell surface area was smaller than that for the control corneas (i.e.  $482$  compared to  $525 \mu\text{m}^2$ ). A small decrease in the median cell area resulted from the change in the distribution (i.e.  $372$  compared to  $388 \mu\text{m}^2$  in the controls).

#### *Quantitative assessment of the epithelial cell surface craters.*

With the special preparative methods used in this study, crater-like structures with an encircling collar or ring were evident on all cell types in all three of the experimental groups of corneas (i.e. controls, chlorobutanol-and benzalkonium chloride - exposed corneas). It can be qualitatively noted that the epithelia exposed to benzalkonium chloride (Figure 4A) clearly had fewer craters than the chlorobutanol - exposed or control corneas. In order to quantitatively assess the occurrence of these features on the cells, a count was simply made of the number of craters on each of the cells that was digitized for the cell surface area measures. The results of these counts are presented in histogram form in (Figure 7). For control corneas,  $140$  of  $510$  cells (i.e.  $27.5\%$ ) did not have any obvious crater-like structure on their surface. Similarly, for the chlorobutanol-exposed epithelia,  $159$  of  $536$  cells ( $29.1\%$ ) did not have obvious craters. In contrast, following recovery from the exposure to the benzalkonium chloride-preserved artificial teardrops,  $42.9\%$  ( $219$  of  $511$ ) of the cells did not have obvious crater-like structures on them. For all of the rest of cells, one or more crater-like structures were evident. The distributions of crater numbers was very similar for control cells and those exposed to chlorobutanol-containing eyedrops  $6$  hours previously (compare Figures 7A and 7B), e.g.  $144$  cells had  $1$  crater in both these groups while

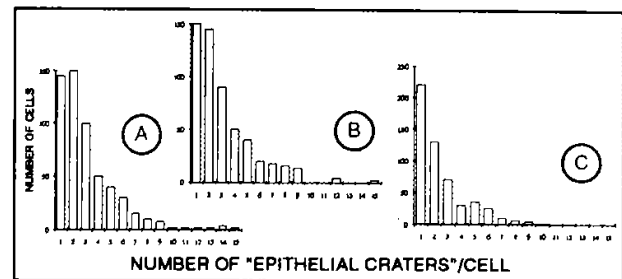


Figure 7. Histograms to show incidence of cells with different numbers of epithelial craters (holes). The cells analyzed with the same as those in Figure 4. (A) control corneas, (B) chlorobutanol - exposed corneas, (C) benzalkonium chloride - exposed corneas. See text for criteria for counting of epithelial craters.

$94$  and  $90$  cells respectively had  $2$  craters. However, these numbers were rather lower for those cells that had been exposed to the benzalkonium chloride, e.g.  $137$  cells with  $1$  crater and only  $79$  cells with  $2$  craters etc. (Figure 7C). The cells observed after benzalkonium chloride exposure thus have a lower incidence of crater-like structures on their exposed surfaces.

## Discussion

In this study, the effect of preservative agent-containing artificial teardrops on the surface cells of the corneal rabbit epithelium has been objectively assessed. Measures of cell cytotoxic effects (assessed by estimates of the number of exfoliating cells), non-toxic cell changes (assessed by cell surface area measures) and surface membrane-related phenomena (assessed by counts of cell craters) are all presented as methods of quantitative evaluation of the effects of artificial teardrops on the scanning electron microscope image of the ocular surface. Such methods are time-consuming but provide an objective means of comparing chemicals, drugs or pharmaceuticals. Such quantification is clearly necessary since even control epithelia (where such micrographs have been presented) have often been different both between studies from the same laboratories and between laboratories.<sup>12</sup> The most likely reason for these

differences is a lack of standardization of fixation protocol, even in studies from the same group of researchers in some cases.<sup>12</sup> Subjective grading schemes have been proposed<sup>20,21</sup> and used by some investigators<sup>20,22</sup> and may well be sufficient to distinguish between effects at the gross level, e.g. cell exfoliation or conspicuous cell damage. The assessments however appear to require that the electron micrographs be taken at very high magnifications (e.g. 2000 X to 3000 X magnification) so that the microplacae (or microvilli) on the cell surfaces can be seen. As a result, a large number of separate micrographs need to be taken to obtain a representative sample<sup>21</sup>.

The study was designed only to assess the effects of occasional use of an artificial teardrop on the corneal epithelial surface in a healthy eye. It was not intended as a cytotoxicity evaluation neither was the interest in documenting the acute cellular or ultrastructural changes that clearly can occur when the ocular surface is exposed to single or multiple drops of preservative agent-containing ophthalmic solutions. Numerous other studies have provided documentation of the acute effects (i.e. within 30 min) of the effects of higher concentrations of benzalkonium chloride-containing solutions on the ocular surface; gross cell exfoliation has been reported in several scanning electron microscope studies.<sup>11, 22-27</sup> Similar results have been obtained from light microscope<sup>24, 28, 29</sup> or transmission electron microscope studies.<sup>30</sup> While the concentrations of benzalkonium chloride used in some of the studies have been close to those commonly used in commercially-available eyedrops, the exposure has either been intense (i.e. 10-15 drops administered over several minutes to an hour) or continuous (i.e. the continuous application over many minutes or even immersion of the globe for a few minutes in preservative agent-containing solution)<sup>22,28,30</sup>. The present studies provide information on the state of the epithelial surface well after the eyedrops were instilled and were designed to show that the exfoliation that can be seen with benzalkonium chloride (or

even chlorobutanol<sup>14</sup>) is not progressive when just a couple of drops of the eyedrops are instilled.

The reason for the observed effects is not entirely clear at this time. Several tentative conclusions can however be drawn to provide a basis for further investigations. The overall lack of cell exfoliation seen after recovery from exposure to the chlorobutanol-preserved eyedrops reflects the probable fact that the peak exfoliation rate has not been realized. In a previous study,<sup>14</sup> it was observed that, at the same period of time after exposure of the epithelial surface to these eyedrops, the percentage exfoliating cells was maximal at some time between 3 and 5 days of twice daily use. The shift to slightly larger squamous cells presumably reflects a reduced rate of exfoliation of squamous cells, at least in the short term. For the benzalkonium chloride-exposed epithelia, while little cell exfoliation was evident at 6 hrs after the last set of eyedrops, the occurrence of higher numbers of smaller cells suggests that significant cellular exfoliation had occurred during the period after the eyedrop instillation; the surface being viewed by scanning electron microscopy would thus reflect a newly uncovered layer of cells.<sup>31</sup> The kinetics of these changes, over the 6 h period, thus need to be studied in more detail both with the dosage used in these studies and with more frequent instillation of the eyedrops. The significantly reduced numbers of well-formed epithelial craters (epithelial holes) after recovery from benzalkonium chloride exposure can be taken both as an indication that the most superficial layer of cells has been lost after the treatment<sup>21</sup> and that the nature of the tear film and epithelial surface interaction is immature.<sup>18</sup> It remains to be established if these craters reflect exocytosis (of intracellular vesicles<sup>17</sup>) or an ongoing process of endocytosis and exocytosis of surface mucin.<sup>18</sup>

---

#### ACKNOWLEDGEMENTS

This study was made possible by a research operating grant from the Natural Sciences and Engineering Research Council (NSERC) of Canada.

Allegan Inc is thanked for their generous provision of samples of the commercially available eyedrop products but the study was not financially supported by the company. The author has no proprietary interest in these or any other artificial tear formulations.

---

## References

1. Volker-Dieben HJm Kok-Van Alpen CC, Hollander J, Kruit PJ, Battenburg K. The palliative treatment of the dry eye. *Doc Ophthalmol* 1987; 67: 221-7.
2. Klein M, Millwood EG, Walther WW. On the maintenance of sterility in eye drops. *J Pharm Pharmacol* 1954; 6: 725-32.
3. Lawrence CA. Chemical preservatives for ophthalmic solutions. *Am J Ophthalmol* 1955; 39: 385-94
4. Riegelman S, Vaughn DG. A rationale basis for the preparation of ophthalmic solutions. *Surv Ophthalmol* 1958; 3: 471-92.
5. Mullen W, Shepherd W, Labovitz J. Ophthalmic preservatives and vehicles. *Surv Ophthalmol* 1973; 17: 469-83
6. Aslund B, Oslon OT, Sandell E. Studies on in-use microbial contamination of eye drops. *Acta Pharm Suec* 1978; 15: 389-94.
7. Coad CT, Osato MS, Wilhelmus KR. Bacterial contamination of eyedrop dispensers. *Am J Ophthalmol* 1984; 98: 548-51
8. Schein OD, Hibberd PL, Starck T, Baker AS, Kenyon KR. Microbial contamination of in-use ocular medications. *Arch Ophthalmol* 110: 82-5.
9. Wilson-Holt N, Dart JKG. Thimerosal Keratoconjunctivitis, frequency, clinical spectrum and diagnosis. *Eye* 1989; 3: 581-7.
10. Wilson FM. Adverse external ocular effects of topical ophthalmic therapy: an epidemiological, laboratory and clinical study. *Trans Am Ophthalmol Soc* 1983; 81: 854-964.
11. Burstein NL. Corneal cytotoxicity for topically applied drugs, vehicles and preservatives. *Surv Ophthalmol* 1980; 25: 15-30.
12. Doughty MJ. On the evaluation of the corneal epithelial surface by scanning electron microscopy. *Optom Vis Sci* 1990; 67: 735-56.
13. Doughty MJ. Effect of the use of artificial tears on the size of squamous cells of the rabbit corneal epithelium evaluated by scanning electron microscopy. *Optom Vision Sci* 1992; 69: 451-7.
14. Doughty MJ. Twice-daily use of a chlorobutanol-preserved artificial tear on rabbit corneal epithelium assessed by scanning electron microscopy. *Ophthalm Physiol Opt* 1992; 12: 457-66.
15. Amemiya T, Yoshida H, Yoshida M, Kawaji H. A study of the corneal surface with special reference to the so - called epithelial hole [JPN]. *Acta Soc Ophthalmol Jpn* 1980; 84: 157-62.
16. Sugita A, Horita K, Sakisaka H. Scanning electron microscopic observation of the corneal epithelium in the rabbit with special reference to the surface ultrastructure of craters [JPN]. *Acta Soc Ophthalmol Jpn* 1982; 86: 81-86.
17. Brewitt H. Tranenersatzmittel. Experimentelle und klinische Beobachtungen. *Klin Monatsbl Augenheilkd* 1988; 193: 275-82.
18. Hazlett LD, Wells P, Spann B, Berk RS. Epithelial desquamation in the adult - mouse cornea. A correlative TEM-SEM study. *Ophthalmic Res* 1980; 12: 315-23.
19. Anderson PJ. Purification and quantification of glutaraldehyde and its effects on several enzyme activities in skeletal muscle. *J Histochem Cytochem* 1967; 15: 652-61.
20. Burstein NL. Preservative cytotoxic threshold for benzalkonium chloride and chlorhexidine digluconate in cat and rabbit corneas. *Invest Ophthalmol* 1980; 19: 308-13.

21. Begley CG, Waggoner PJ, Hafner GS, Tokarski T, Meetz RE. Effect of rigid gas permeable contact lens wetting solutions on the rabbit corneal epithelium. *Optom Vis Sci* 1991; 68: 189-97.

22. Berdy GJ, Abelson MB, Smith LM, George MA. Preservative-free artificial tear preparations. Assessment of corneal epithelial toxic effects. *Arch Ophthalmol* 1992; 110: 528-32.

23. Tonjum AB. Effects of benzalkonium chloride upon the corneal epithelium studied with scanning electron microscopy. *Acta Ophthalmol (Kbh)* 1975; 358-66.

24. Dormans JAMA, Van Logten MJ. The effects of ophthalmic preservatives on corneal epithelium of the rabbit: a scanning electron microscopical study. *Toxicol Appl Pharmacol* 1982; 62: 251-61.

25. Ichijima H, Petroll WM, Jester JV, Cavanagh HD. Confocal microscopic studies of living rabbit cornea treated with benzalkonium chloride. *Cornea* 1992; 11: 221-25.

26. Muadgal PC, Cornelis H, Missotten L. Effects of commercial ophthalmic drugs on rabbit corneal epithelium. A scanning electron microscopic stud. *Von Graefes Arch Klin Exptl Ophthalmol* 1981; 216: 191-203.

27. Duprat P, Conquet P. Predictive value of ocular irritation tests. *Adv Vet Sci Comp Med* 1987; 31: 173-95.

28. Gasett AR, Ishii Y, Kaufman HE. Cytotoxicity of ophthalmic preservatives. *Am J Ophthalmol* 1974; 78: 98-105.

29. Durand - Cavagna G, Delort P, Duprat P, Bailly Y, Plazonnet B, Gordon LR. Corneal toxicity studies in rabbits and dogs with hydroxyethyl cellulose and benzalkonium chloride. *Fund Appl Toxicol* 1989; 13: 500-8.

30. Lopez Bernal D, Ubels JL. Quantitative evaluation of the corneal epithelial barrier: effect of artificial tears and preservatives. *Curr Eye Res* 1991; 10: 645-56.

31. Thoft RA, Friend J. The X, Y, Z hypothesis of corneal epithelial maintenance. *Invest Ophthalmol Vis Sci* 1983; 24: 1442-43.



# The turnover of cells of the Corneal Epithelium



Graeme Wilson O.D., Ph.D.

The corneal epithelium is an extraordinary structure. It must survive in an environment almost as hostile as that of the skin. At the same time it must remain transparent and optically smooth. It does this by having a high rate of cell renewal and by the rapid removal of damaged cells from the epithelial surface. This is accomplished in the absence of a blood supply.

The epithelium is described as having layers made up of basal cells, wing cells and superficial cells. The healthy corneal epithelium has the following properties

1. It is highly transparent
2. It serves as a barrier to the entry of fluid into the corneal stroma.
3. It is resistant to shear forces.
4. It produces new cells and sheds old cells at a normal rate.

In this presentation I want to concentrate on the shedding of cells. There are at least four terms which describe this act: shedding, exfoliation, desquamation, and sloughing. They are generally used as synonyms without difference in meaning. The maintenance of cells is dependent on a balance between new cells produced by mitosis and old cells shed. In addition there is a centripetal movement of cells from the corneal limbus towards the corneal apex. This is necessary because the corneal stem cells are located at the limbus. These are the immortal mother cells of the corneal epithelium- the cells which can repopulate the epithelium even after every other cell is removed. The location of stem cells at the limbus protects them from ultraviolet damage.

Areas of shedding cells are visible clinically by means of stains such as fluorescein. It might be assumed that such areas of staining are sites where shedding has occurred, but more likely they are

areas where shedding is about to occur. Once shed, cells are removed by the precorneal tears. However, not all cells in tears are ocular in origin. For example, first thing in the morning there are white blood cells - leukocytes. These can be obtained by irrigating the corneal surface with a corneal irrigating chamber.

What causes a cell to shed? Using the corneal irrigating chamber, we have shown in the human eye that a topical anesthetic (proparacaine) causes an increase in the number of cells shed. However, this is not immediate, it requires several hours before there is an actual increase.

To investigate the factors which cause shedding in a controlled environment we had developed a procedure for maintaining rabbit corneas in isolation. This is necessary because it is likely that blinking is a major factor in the final removal of cells from the epithelial surface. By removing the effects of blinking we can study other factors which might influence shedding. Tear hyperosmolality has been suggested as one of the main causes of damage to the ocular surface in keratoconjunctivitis sicca (KCS) and dry eye. Is this damage caused by accelerating the shedding rate? When measured using the isolated cornea procedure we found no increase in cells shed - even with osmolalities as high as 420 mOsm/kg. Tear osmolality in KCS is only slightly higher than normal tears. Hence, there is no evidence that such relatively small differences could cause the magnitude of changes associated with dry eye - at least through the mechanism of increased shedding.

How about contact lens wear? Does anoxia affect the shedding rate? It does initially, but over a period of six hours there is no difference between a normoxic eye and an anoxic eye. Anoxia cannot

be the cause of the effect reported by Lemp et al. They reported that cells on the epithelial surface appeared larger in extended wear when viewed by specular microscopy.

One factor which is believed to increase shedding is over exposure to ultraviolet radiation. It is clear from the slide that the latent period for this shedding is very similar to the onset of discomfort. This suggests that shedding and discomfort

are related, and fits with the widespread belief that the pain is due to exposure of nerve endings to prematurely shed cells.

In summary we can say that cells do shed in the absence of blinking. The shear force exerted by the lids is not the only factor which causes cells to shed. Cell shedding is influenced by contact lens wear. There is no evidence that the discomfort of dry eye is due to an increase in cell shedding.



# Cambios refractivos inducidos por el uso de aceite de silicón en cirugía vitreo-retiniana

Hernando Camacho, M.D (\*)  
Fabián Martínez, O.D.(\*)  
J.Fernando Arévalo, M.D.(\*)  
Zoilo Cuellar, jr, M.D.(\*)



---

## Resumen

---

Los autores comunican los resultados de un estudio retrospectivo realizado en 50 ojos a los cuales se les practicó cirugía vitreoretiniana con aceite de silicón y posterior extracción en el Instituto Barraquer de Bogotá, Colombia, desde 1985 a 1992. Se trata de un grupo de pacientes afacos en un 90% y con un silicón de 5.000Cs.

Encontramos que la hipermetropía disminuye con el aceite de silicón intraocular de +3.87 a +1.18 (equivalente esférico promedio) y que se hipermetropisa a +5.54 al extraer el silicón, esta diferencia fue estadísticamente significativa (P= 0.0001).

---

---

## Introducción

---

El aceite de silicón en cirugía vitreoretiniana fue utilizado por vez primera por Cibis(1) para el tratamiento de desprendimientos de retina complicados con proliferación vitreoretiniana (PVR) severa. Sin embargo, para convertirse en el elemento de gran importancia, que es actualmente la cirugía vítrea de este tipo de patología, debió

pasar por una disminución importante del entusiasmo inicial despertado por esta técnica, debido principalmente a reportes de varios autores sobre la alta incidencia de complicaciones y la "toxicidad" relacionada con su uso (2) (3) (4) (5).

Fue gracias a las contribuciones de Scott (6) en Inglaterra, la introducción de la vitrectomía por Machemer (7) y a la combinación de estas técnicas por Zivojnovic (8) (9) que el uso del aceite de silicón se ha establecido para el tratamiento de desprendimiento de retina complicados. Por otra parte, el aceite de silicón tiene un índice de refracción (1.405) mayor al del vítreo (1.336) lo que va a llevar a cambios significativos en la óptica

Presentado Durante el FORUM IN XXV ANNIVERSARIO de la CLINICA BARRAQUER en Bogotá, Colombia (MARZO 21 -26, 1993)

Correspondencia dirigirse a Hernando Camacho, M. D. CLINICA BARRAQUER Avenida 100 No. 18 A - 51. Apartado Aéreo 90404 Santafé de Bogotá, Colombia.

del globo ocular una vez que este reemplazo vítreo es utilizado (10), por lo tanto su presencia intraocular va a implicar efectos notables en la corrección refractiva necesitada por el paciente.

Cibis, et al (1) notaron que la hipermetropía inducida por el aceite de silicón en ojos fájicos era de entre 3 y 7 dioptrías, y que la hipermetropía era menor en ojos afacos llenos de silicón; Stefansson, et al (11) determinaron que la corrección refractiva puede variar de 5 a 9 dioptrías, los ojos afájicos se hacen menos hipermetrópicos al estar llenos de silicón mientras que los ojos fájicos se hacen más hipermetrópicos cuando la cavidad vítreo esta llena de silicón.

El objetivo de este trabajo es entonces analizar los cambios refractivos ocurridos en ojos sometidos a cirugía vitreoretiniana y aceite de silicón, durante la permanencia intraocular de esta sustancia y luego de su retiro.

## Material y métodos

Se revisaron en forma retrospectiva las historias clínicas de 115 ojos de 113 pacientes a los cuales se les realizó extracción de aceite de silicón luego de cirugía vitreoretiniana exitosa desde marzo de 1985 a marzo de 1992 en el Departamento de Retina y Vítreo del Instituto Barraquer de América.

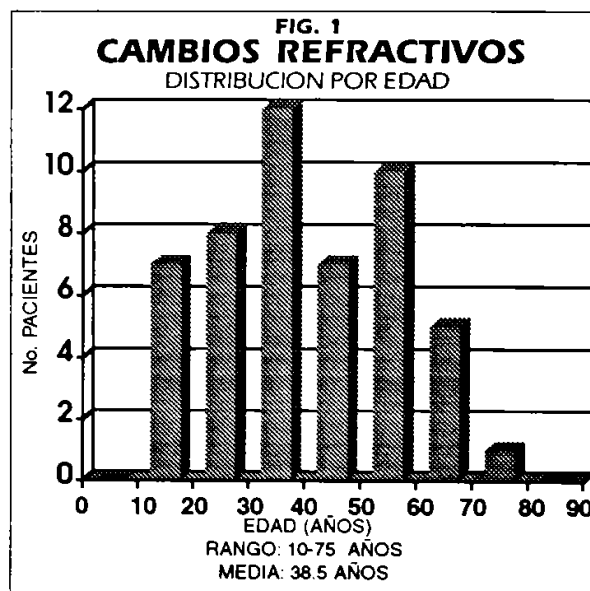
Se excluyeron de este estudio aquellos ojos con Retinopatía Diabética Proliferativa (RDP) y aquellos en los que no se lograron recopilar todos los datos exigidos por nuestro protocolo, debido a que muchos de nuestros pacientes provienen de otros países y en numerosas oportunidades no regresan para los controles postoperatorios.

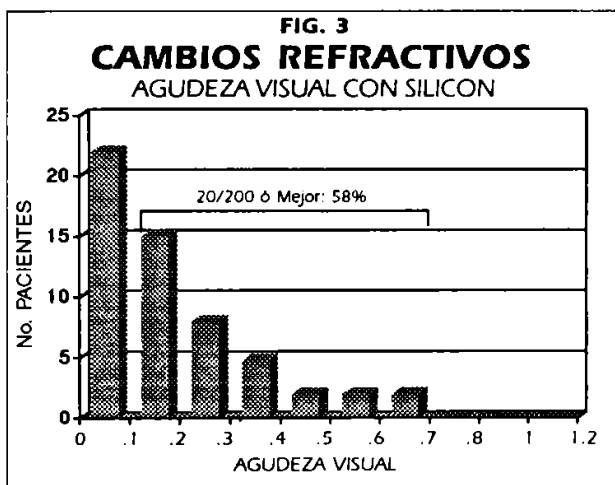
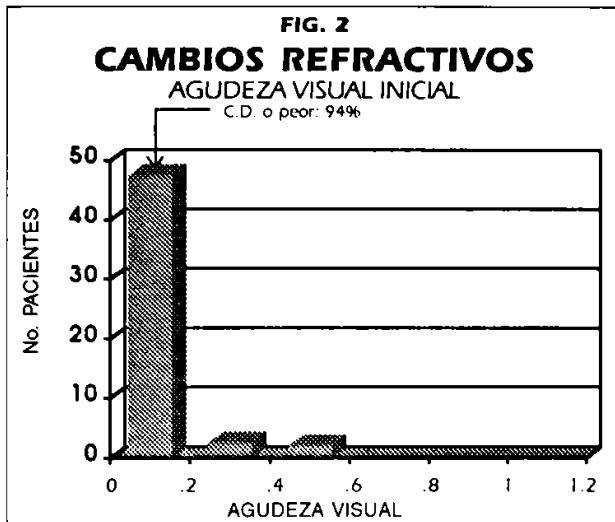
Quedaron 50 ojos de 50 pacientes que fueron operados y seguidos por uno de los autores (H.C.) y la valoración refractiva o funcional fue realizada por otro de los autores (F.M.). Se analizaron parámetros como la agudeza visual (AV) inicial, con

silicón y sin silicón; refracción inicial, con silicón y sin silicón (equivalente esférico); estado de cristalino; viscosidad del aceite de silicón; estudio de población y ojo afectado. En 40 ojos (80%) se utilizó un aceite de silicón de 5.000Cs y en 10 ojo (20%) un aceite de silicón de 1.000Cs. 46 ojo (92%) eran afájicos y 4 ojos (8%) eran pseudofájicos con lente intraocular de cámara posterior. Las indicaciones para la utilización de aceite de silicón en nuestros casos ya han sido descritas (12).

## Resultados

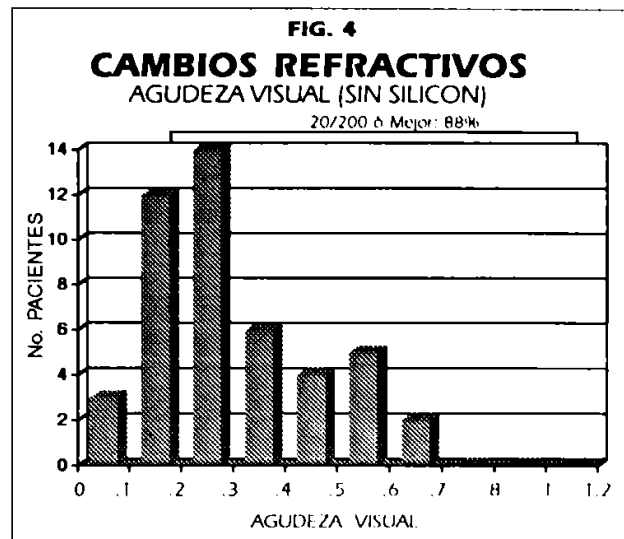
Se trataron 27 ojos derechos (54%) y 23 ojo izquierdos (46%) de pacientes con las siguiente características: 43 pacientes del sexo masculino (86%) y 7 pacientes del sexo femenino (14%), con un rango de edad de 10 a 75 años con una medida de 38.5 años ( Fig. 1). El 94% de los ojos tenían una AV inicial de cuenta de dedos (CD) o peor (Fig 2). El 58% de los ojos tenían un AV con el aceite de silicón de 20/200 o mejor ( Fig. 3). El 88% de los ojos lograron una AV al extraer el aceite de silicón de 20/200 o mejor (Fig. 4).





La diferencia encontrada entre el AV con silicón y la encontrada al retirarlo fue estadísticamente significativa ( $P= 0.0001$ ) mediante análisis de regresión simple (Test de Fisher).

En general, el promedio de equivalente esférico encontrado inicialmente fue de +3.87 con un rango de -14.00 a +20.00. El promedio del equivalente esférico con silicón fue de +1.18 con un mínimo de -14.75 y un máximo de +8.00. El equivalente esférico promedio al retirar el aceite de silicón fue de +5.54 con un rango de entre -16.5 a +16.75. La hipermetropización de 4.36 dioptrías observada



al retirar el silicón fue estadísticamente significativa ( $P= 0.0001$ ).

Los pacientes en los cuales se utilizó un aceite de silicón de 1.000Cs tuvieron una hipermetropización al retirarlo de 1.92 dioptrías y aquellos en los cuales el silicón utilizado tuvo una viscosidad de 5.000Cs mostraron una variación de 4.97 dioptrías en el mismo signo al retirarlo.

En cuanto al estado del cristalino, los pacientes afacos mostraron una variación promedio de 4.43 dioptrías de hipermetropización al retirar el silicón, mientras que los pseudofacos variaron en promedio 3.56 dioptrías en el mismo sentido. Estas diferencias relacionando el equivalente esférico con la viscosidad del aceite de silicón y el estado del cristalino no fueron estadísticamente significativas utilizando un Test Anova de un factor.

### Conclusiones

El resultado de este estudio nos indica que un importante número de nuestros casos con desprendimiento de retina complicado pertenecen al sexo masculino y se encuentran en una edad

altamente productiva, lo que implica la necesidad de una pronta recuperación visual.

La AV de nuestros casos mejoró de CD o peor en el 94% al ingreso, a 20/200 o mejor en el 58% de los ojos con el aceite de silicón intraocular y mejoró aún más al extraer el silicón a 20/200 o mejor en el 88% de los casos. Esta diferencia encontrada al extraer el silicón fue estadísticamente significativa ( $P= 0.0001$ ) lo que indica que este procedimiento es beneficioso ya que elimina la fluctuación de la visión asociada al movimiento de la burbuja y elimina el trastorno visual causado por la emulsificación. Encontramos una disminución de la hipermetropización en pacientes (afacos en el 90% de los casos) con el silicón en la cavidad vítrea y una hipermetropización, al extraer el aceite de silicón, de +5.54 como promedio.

Se ha determinado que el aceite de silicón en la cavidad vítrea es responsable de importantes cambios ópticos del ojo, esto lleva a un ojo afáquico previamente emétrepe a ir de 10 - 12 dioptrías de hipermetropía a 4 - 6 dioptrías de hipermetropía cuando el aceite de silicón está en el ojo. Lo que ocurre en el ojo afaco es que la superficie anterior de la burbuja de silicón forma una superficie convexa que actúa como un lente positivo y por lo tanto hace menos hipermetrópico el ojo ( Fig. 5).

En el ojo fáquico, la burbuja de silicón forma una superficie cóncava detrás del cristalino y esto actúa como un lente negativo y hace al ojo entonces más hipermetrópico ( Fig. 6).

Si bien en los estudios reportados previamente se estima una variación promedio de unas 7 dioptrías de disminución o aumento de hipermetropización según el ojo esté lleno o no de silicón, las variaciones con nuestro estudio se explican con factores que influyen este resultado final como son: un llenado incompleto de la cavidad vítrea con el aceite de silicón, generalmente preferimos no dejar el globo ocular

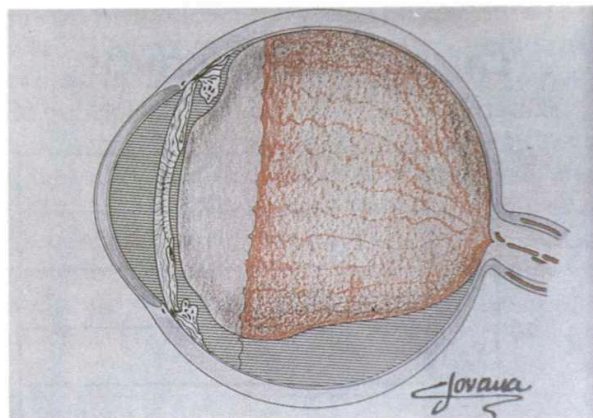


Fig. 5 El dibujo muestra un ojo afaco con silicón intraocular; la superficie anterior de la burbuja de silicón actúa como un lente positivo.

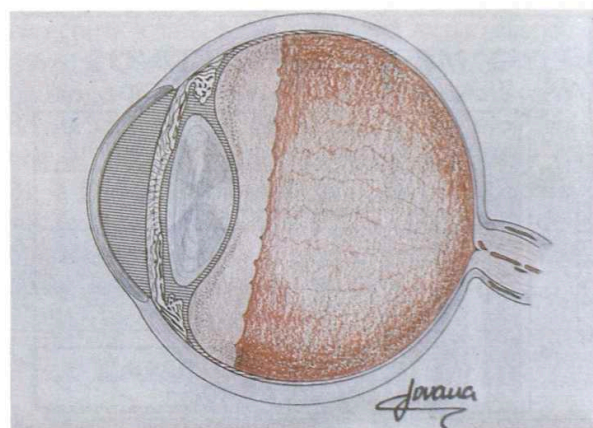


FIG. 6 El dibujo muestra un ojo fáquico con silicón intraocular; la superficie anterior de la burbuja de silicón actúa como un lente negativo.

lleno de silicón para evitar la hipertensión ocular inmediata por exceso de esta sustancia; el estado refractivo inicial del ojo a tratar, procedimientos asociados que cambian el eje axial anteroposterior del globo ocular como una queratoplastia penetrante o un cerclaje escleral que realizamos con mucha frecuencia.

Aunque no fueron estadísticamente significativas las diferencias, observamos una clara tendencia a una mayor hipermetropización al extraer el aceite de silicón de una viscosidad de

.000Cs; por otra parte, observamos que hubo una hipermetropización de +3.56 dioptrías al retirar el silicón en pacientes pseudofacos a pesar de que en teoría en un ojo lleno de silicón la superficie en contacto con el lente intraocular de cámara posterior es plana y no debe llevar a cambios refractivos; sin embargo, nuestro resultado se explica por el llenamiento subtotal que hacemos de la cavidad vítrea.

Para finalizar, queremos llamar la atención del cirujano de vítreo con respecto a los importantes

cambios ópticos que ocurren al estar presente el aceite de silicón intraocularmente y al retirarlo, de manera de tomar en cuenta estas variaciones al corregir refractivamente estos pacientes. Por otra parte, recordar que los reflejos retinoscópicos son muy variables y brillantes, por lo que lo hemos denominado adiamantados; por lo tanto, la dificultad para realizar una retinoscopia y refracción precisa disminuye en forma considerable si conocemos los cambios que podemos esperar sean inducidos por la presencia o el retiro del aceite de silicón intraocular.

---

### Summary

---

The authors communicate the results of a retrospective study made in 50 eyes in which silicone oil vitreoretinal surgery and later silicone oil removal was performed at the Barraquer Institute of Bogotá, Colombia, from 1985 to 1992. This is a group of aphakic patients in 90% of cases and with 5.000Cs silicone oil.

We found that Hyperopia diminishes with silicone oil inside the eye from +3.87 to +1.18 (mean espheric equivalent) and that this eyes become more hyperopic to +5.54 after silicone oil removal this difference was statistically significant (P= 0.0001).

---



---

### Referencias

---

1) Cibis, P.A.; Becker, B.; Okun, E.; Canaan, S: The use of liquid silicone in retinal detachment surgery. Arch Ophthalmol. 1962, 68: 590-599.

2) Cockerham, W.; Schepens, C.L. and Freeman, H.M: Silicone injection in retinal detachment. Modern problems Ophthalmology 1969, 8: 525-540.

3) Grey, R.M.B. and Leaver, P.K: silicone oil in treatment of massive preretinal retraction. I results in 105 eyes. J. Ophthalmol. 1979, 63: 355-360.

4) Okun, E: Intravitreal surgery utilising liquid silicone: long term follow-up. Transactions of the pacific coast Ophthalmological society. 1968, 49: 141-159

5) Watzke, R.C: silicone retinopexis for retinal detachment: A long-term clinical evaluation. Arch. Ophthalmol. 1967, 77: 185-196.

6) Scott, J.D: A rationale for the use of liquid silicone. Trans. Ophthalmol. Soc. U.K. 1977, 97: 235.

7) Machemer, R: Massive periretinal proliferation: A logical approach to therapy. Trans. Am. Ophthalmol. Soc. 1977, 75: 556-586.

8) Zivojnovic, R.; Mertens, D.A.E. and Baarsma, G.S: Das Flussige Silikon in der amotiochirurgie. Klin. Monatsbl. Augenheilk 1981, 179: 17.

9) Zivojnovic, R.; Mertens, D.A.E. and Peperkamp, E: Das Flussige Silikon in der amotiochirurgie (II) Bericht 280 Falle-Waitere Entwicklung der Technik. Klin. Monatsbl. Augenheilk 1982, 181: 444.

10) Stefansson, E. and Tiedeman, J: Optics of the eye with air or silicone oil. Retina 1988, 8: 10-19.

11) Stefansson, E.; Anderson Jr, M.M.; Landers III, M.B.; Tiedeman, J.S. and Mc Cuen II, B.W: Refractive changes from use of silicone oil in vitreous surgery. Retina 1988, 8: 20-23.

12) Camacho, H.; Arévalo, J.F: Extracción de ace de silicón en cirugía vitreoretiniana. Presentado durar el XXV Congreso Nacional Colombiano de Oftalmolog julio 26-30, 1992.

# The practice of Low Vision Care

Edward Goodlaw

When full visual performance is not available to the patient either from birth defects, injury, or the ravages of disease, where all possible medical care can no longer cure, the optometrist with low vision ability can do a great deal to rehabilitate this otherwise handicapped patient. The first step is a thorough case history to establish the onset of the visual impairment, congenital, sudden or gradual. Is the impairment progressing and at what rate, and what curative procedures have been extended as well as will further curative measures be helpful, and at what risk. Is genetic council indicated?. How does the visual impairment prevent the patient from achieving in whatever fashion desired? What are the lifestyle needs of the patient, and what will it take in optical gadgetry, training, environmental changes, support, understanding and cooperation from family, friends, and or co-workers to aid the patient in achieving these needed goals. What are the patients interests, and what visual abilities are needed in fulfilling these interests. What is his chief complaint?. Then comes an analysis of the patient's visual system. A most important requirement is a good refraction including any extraocular muscle malfunction as well as qualitative field analysis, media impairment, optical surfaces distortion, and retinal and visual tract involvement.

What do I mean by "qualitative field analysis"? Actually measuring quantitatively functional field vs field lost is very helpful, but time consuming, and indicated when definitive information is needed. A good confrontation technique can provide a concept of peripheral field loss. Visual acuity and Amsler Grid testing can give a good idea of central field involvement. A confrontation technique I described many years ago has worked well for me, and has fulfilled the need to gather information quickly to avoid patient fatigue. I sit directly in front of the patient, and with one hand covering the patient's non tested eye. With his other eye the patient fixates on my eye. When the central field loss is large, seeing my eye may be

difficult, but the position of the eye in the context of the large field occupying area of a face usually serves to maintain fixation adequately. The room illumination should be subdued, around 2 to 4 foot candles for more sensitive response .

To assure better contrast relationships, I use a wand created by cementing a 3 or 4 mm white circular spot cemented in the center of a black square about 3 inches on a side. This square is cemented on its back to a 1/8 inch dowel, 8 inches long. With the patient thus holding fixation, I can bring the black square from the non seeing area into the seeing area with wrist movement only. This avoids arm movement which would inform of target position. By noting the reported location of target visualization, I can derive a good idea of visual field size and shape. A good refraction to the point of best vision possible is a most important first step. I'll never forget the young man who came to my office wearing a pair of 4x plano bionic glasses with which he couldn't pass the drivers test. With his plus 14.00D refraction correcting glasses he immediately achieved 20/70 vision, and I am sure, with time his vision improved, though I never had the privilege of follow up. Aiding magnifying devices are added to this basic refraction. Now lets consider other conditions, and the helpful procedures. When visual acuity cannot be brought to normal even with a good refraction, the first suspicion might be A.R.M. because this is statistically a major cause of visual loss. Traquir's picture of an island of vision in a sea of blindness may be modified to depict macular degeneration as a hole right through the peak of the visual island. The rest of the visual island is left intact –the peripheral field is very good, but there is a central scotoma .

These patients respond best to head held magnification. Persons who suffer any field loss resist any further encroachment of remaining field. Hand held or stand magnifying glasses confine vision within their borders. Thus, the patient is project-



ing his scotoma into the confined area of the magnifier, so there are missing details from the scotoma blocked spaces. Lovie-Kitchen noted the closer to the eye the visual task the smaller the ratio of projected blocking area of the scotoma to the field area. That is one advantage. However, as one holds the reading material within focus of the head microscopic lenses, and attempts to read in usual manner by moving the eyes across the page or by moving the head, as Feinbloom pointed out, the magnifying device also magnifies the movement. He called this the optical lever. The print races by, and may induce nausea. The patient has to be taught how to use his new glasses. He or she has to be taught to hold the head still and move the reading material from right to left while reading (in the countries of the type of language we use) from left to right. The following of the print is now governed by the proprioceptor sense to which the patient is accustomed and can accomplish well.

In doing this another wonderful thing happens. As the patient moves the tried to be seen material towards the blind area it is necessary seen by poorer seeing areas peripheral to the non seeing macula, but is magnified by the microscopic lens sufficiently to enable perception. As that group of letters slips into the blind scotoma area, a new group of letters still in the seeing area is visualized. Reading is very much easier, and becomes faster with development of this skill. Eccentric viewing is accomplished without effort. How do we know how much magnification is needed? Kastenbaum suggests as a start to invert the fraction. For instance: if the patient can only read the 20/200 letter, and wants to read newsprint.

News print can usually be perceived with about 20/40 vision. Inverting the fraction, we have  $200/20$  or  $10x$ .  $40/20 = 2$   $10/2 = 5$ . We try with the +5.00. maybe it is too strong or too weak, but it is a start. Because reference is usually to 25 cm distance, magnification of 1x is by a four diopter lens, 6x would be +24.00D. I usually look at it this way. If magnify 1x the 20/200 becomes 20/100. A sec-

ond magnification allows the patient to see 20/50. A third 20/40. A fourth 20/25. Fudge a little to assure accomplishment the first time and you have 5x to start with. These rules of thumb give a starting point. The final decision is by exposing the patient and watching performance against need. When so much of retinal tissue has been destroyed that optical devices cannot produce enough magnification for accomplishing tasks, we now have electronic magnification equipment which may provide adequate rehabilitation .

There are a few other considerations for macular non function. First, when of recent occurrence, the patient experiences shock and will not respond to therapy. Then the angry stage, why me to be singled out for such a catastrophe. It takes time for final recognition of the need for help, and the willingness to accept the help, which is now not as good as before, and requires the effort to master the device. Further, a major role for the macula is a binocular lock. Even though field is preserved, depth perception may become impaired. Proprioception brought in can often be very helpful. A cane may warn the patient where uneven surfaces can cause a fall.

Reading is not the only application that is impaired with macular disfunction. If the task is farther and greater distance is required such as seeing cards on a table, looking at the computer screen, shopping where magnification may be required to see markings on shelved products, reading music, etc., then a combination of a telescopic device either focusable or with reading caps as a telemicroscope can be employed . However, remember the point I made before. When field is lost further encroachment of field is not easily accepted. Necessity may demand, but it will be more difficult to train even though final acceptance can be achieved.

What about distance requirements? The inability to drive an automobile can be devastating to a lifestyle. Bioptic units are successfully employed



in which magnification is supplied by telescopes, and the curtailed field of the telescope is bypassed by raising the head a bit to view the road with the prescribed carrier lens. Telescopes and binoculars have their place in theaters, classrooms, as well as seeing distant street markers and house numbers.

Media opacities and irregularities can seriously impair visual performance. The scattered light masks retinal images.

A prominent example is cataract, also recognized as a major cause of blindness the world over. Enlarging the pupil to allow light to pass around opacities can be very helpful. This can be done with cyclopegic drops, but it is also helpful to avoid the effects of light scatter with typoscopes, various filtering tints, varying illumination intensity and direction, and combinations such as the G & G light which Sam Genensky and I designed a number of years ago. Of course, cataractectomy with new surgical techniques, which are even stitchless, combined with implant optics, have made this a very acceptable remedy. Nevertheless, recent discoveries have implicated the high energy end of the sun's radiation as a major cause, so blue absorbing tints, easily available, can indeed be preventative or at least postpone the need for surgery. Prescribing such protective tints is urged.

Contact lenses may offer complete rehabilitation for corneal irregularities. The junction of cornea and air is the site of greatest index change of the refractive media of the eye. Slight variation of curvature can represent large refractive changes, so irregularities or segment variations in curvature in the protrusion, as in keratoconus, is not optically corrected by spectacles, but with contact lenses full 20/20 vision may be restored. In some instances, where the protrusion is very great, a corneal transplant may be necessary, but skillful fitting techniques may make this procedure unusual. Soft lenses, which bend to the corneal shape, are not an adequate correction, but this may be overcome with a firm lens piggy back.

The approach I have found successful has been to prescribe a short radius back surface thick lens of high oxygen transmitting material. Then with increasing radii tools monitored by the fluorescent pattern of the lens on the eye, I have ground out the periphery until there is just light touch on the cone, a good contour fit in the periphery, and good edge clearance to assure quality tear exchange. The small index change between plastic and tears has not induced enough optical distortion to degrade the retinal image. To avoid lid irritation I have rounded off the front edge, monitored by observing the attack angle of the lid as it rolls over the edge of the lens. There are many approaches to aid patients with large field loss. The overall collapse of the peripheral field of Glaucoma is a major challenge. High minus lenses hand held several inches from the eye can produce a reduced image to warn the patient of otherwise unseen peripheral obstacles. Of course the reduced image degrades details, so poor visual acuity can be a problem. This same effect can be achieved with a reserve telescope called a field expander. Again the use of a cane to provide proprioception input of surfaces not seen with such field loss should be considered in traveling. There are rumors of electronic canes for the future.

Dr. Feinbloom developed a lens system, using cylindrical components instead of spherical as field expanders. These characteristically expand the field in the horizontal direction without shrinking the vertical dimension. This was to provide peripheral input yet still retain habitual vertical visual sensation.

In Retinitis pigmentosa where the major field collapse results from reduced illumination, new wide angle flash lights or spot lights to provide illumination seem to work best.

There have been numerous historical reports of aiding patients with half of field gone, known as hemianopsias. Prisms were used mechanically held or cemented to spectacle lenses with base towards

the blind area to shift the seeing area to replace some of the lost area. These were unsightly and produced color distortion as they were made stronger. Attempts were made to use prisms as mirrors to reflect information from the blind areas. These also were difficult to adjust to provide input from the most needed areas. The major problem I have alluded to earlier. Those who have lost field do not want to give up any of their remaining functional field. Prisms used in this fashion block areas of the seeing field to reflect information from the

nonseeing field. Similarly, numerous attempts were made to use plane opaque mirrors to reflect from the blind areas of field into seeing area. While these permitted better adjustment for reflecting preferred area, they did cut off some areas of the seeing field, which was cause for rejection (Slide 24). When the fresnel wafer vinal stick or prism was introduced, higher powers could be used to provide greater field shift. They could be placed in they did cut off some areas of the seeing field, which was cause for rejection.

# Corneal stability and topography after different refractive procedures

M. Kohlhaas(\*)

J. Draeger(\*)

A. Böhm(\*)

---

## Summary

---

30 subjects with myopia, hyperopia and emmetropia, 30 subjects after Radial Keratotomy and 20 subjects after Excimer-Laser-Ablation were examined in this study. A TMS photokeratoscope was used to measure the changes of corneal topography due to a rapid increase of the intraocular pressure which was achieved with a 180 degree tilting table.

It could be shown that intact corneae react in a central and peripheral steepening of the corneal curvature whereas corneae after radial keratotomy react with a central flattening and a peripheral steepening. Subjects after Excimer-Laser-Ablation showed concerning the ablation depth almost no steepening of the corneal curvature.

**Key words:** Corneal stability - Corneal topography - Tilting table - Refractive surgery.

---

---

## Introduction

---

Refractive corneal surgery e.g. radial keratotomy or Excimer-Laser-Ablation means destruction of one of the two stabilizing membranes of the cornea. This means destabilizing the structure withstanding the continuous force of the intraocular pressure like in keratoconus, where it takes years and years to bulge the thinning centre

(\*)Department of Ophthalmology University of Hamburg Martinistraße 52 2000 Hamburg 20 Germany

forward, changing refractive power to myopia and finally to irregular astigmatism (2, 3, 6). Fluctuating visual acuity, progressive hyperopia after RK, regression of the refractive effect after Excimer-Ablation are well known.(1, 5) Does the physiological or daily changes of the intraocular pressure influence the corneal stability and topography? We know that the intact corneal curvature is stable the whole life. The cornea withstands the daily intraocular overpressure without any changes. A relaxed steady state is between corneal stability and intraocular pressure.

However, what happens to the corneal stability if the intraocular pressure changes? Even v. Helmholtz noticed a correlation between corneal curvature and intraocular pressure. However, his attempt to measure an increased intraocular pressure by measuring the corneal curvature with his ophthalmometer failed.

## Method

To prove our hypothesis of destabilization of corneal structure after refractive procedures an *in vivo* technique was applied for the first time. A change of corneal stability was measured by changes of the corneal topography induced by an increase of intraocular pressure. (Fig. 1)

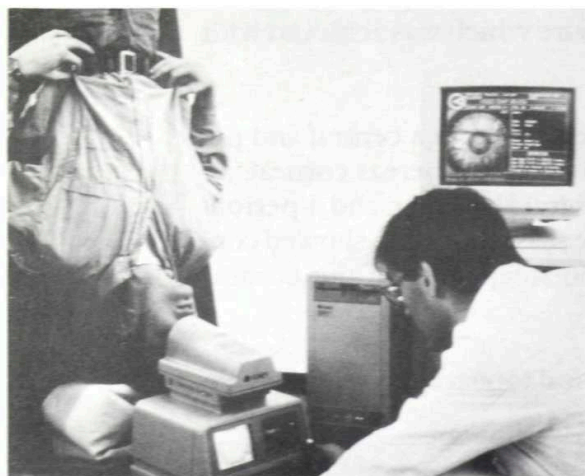


Fig. 1. Patient on tilting table.

A rapid increase of the intraocular pressure up to 40 mmHg without any external deformation of the eye can be achieved with a 180 degree tilting table due to the fluid shift and to hydrostatic pressure changes (4). We used the TMS photokeratoscope before and during increasing the intraocular pressure. The intraocular pressure of the examined subjects ranged between 8 and 15 mmHg in an upright position and between 30 and 40 mmHg in a downright position. (Fig. 2)

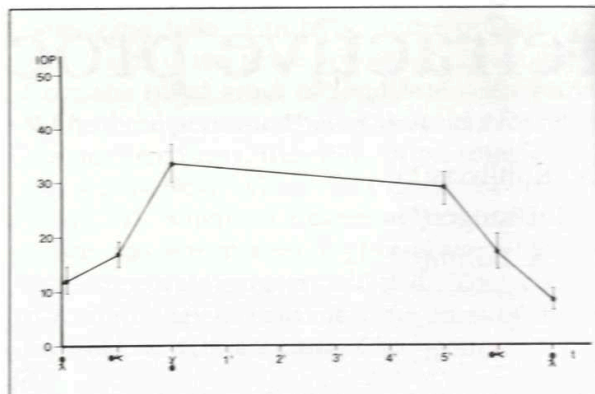


Fig. 2. Changes of IOP during tilting.

## Patients

In our study we examined 10 emmetropic, myopic and 10 hyperopic subjects.

30 subjects after radial keratotomy with 4 to 8 corneal incisions and 20 subjects after Excimer-Laser-Ablation with a preoperative myopia between -1,5 and -24,0 dpt were examined.

## Results

We examined each subject in an upright and in a 180 degree downright position on the tilting table. The image, (Fig. 3) describes the topography of a healthy cornea in upright position. The image, (Fig. 4) describes the topography in a downright position. Due to the rapid intraocular pressure increase each image of normal subjects with intact corneas showed during tilting a peripheral and central steepening of the corneal curvature. A difference between emmetropic, myopic and hyperopic subjects could not be observed. The mean values of subjects with intact corneas show that the periphery steepens more than the corneal center. (Fig. 5)

Completely different, however, react subjects after radial keratotomy. (Fig. 6) describes the topog-

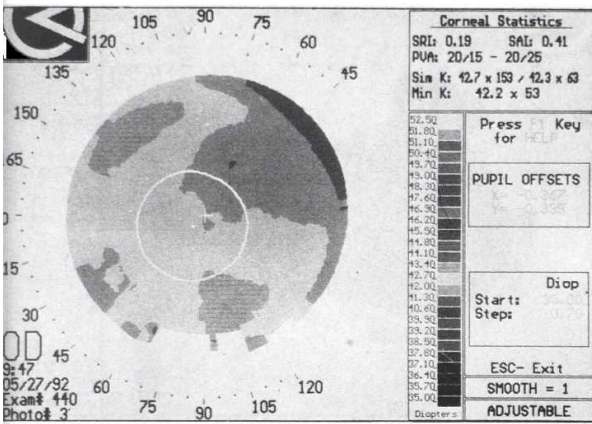


Fig. 3. Intact cornea upright.

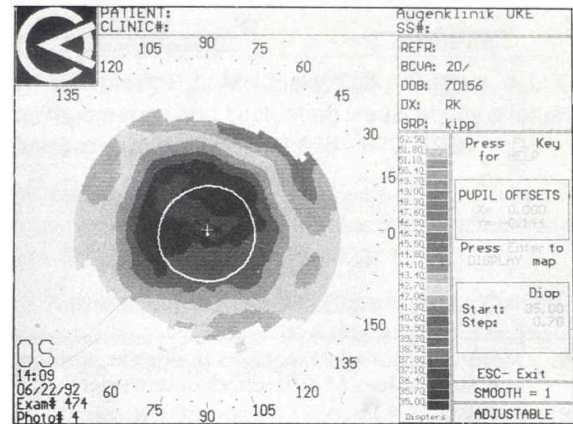


Fig. 6. Patient, 3 years after RK in upright position.

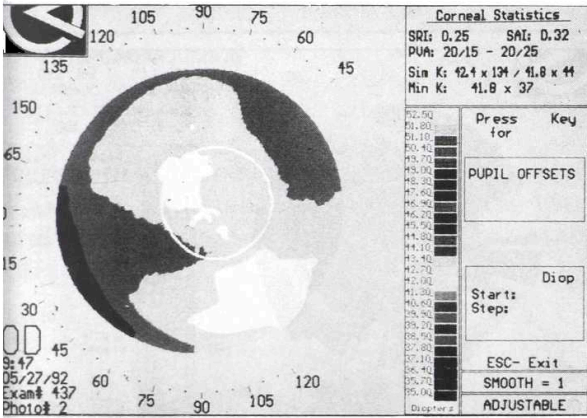


Fig. 4. Intact cornea downright.

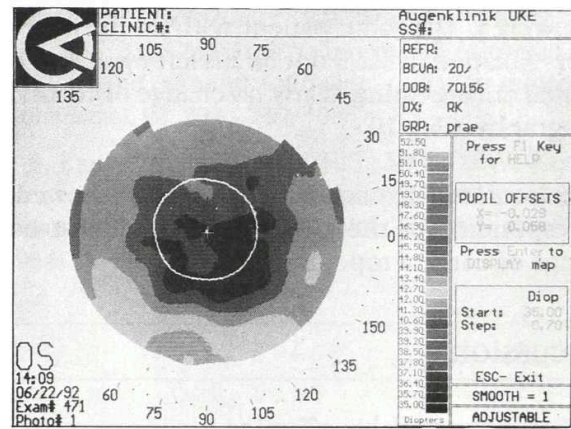


Fig. 7. Same patient in downright position.




Fig. 5. Statistical values.

raphy of a cornea 3 years after RK in an upright position,(Fig. 7) in a 180 degree downright position. A peripheral steepening and a central flat-

tening of the corneal curvature could be observed at the corneal topographies. Each cornea of our subjects after RK showed a central flattening during the tilting manoeuvre and intraocular pressure increase. The statistical mean values of all examined subjects prove these findings. (Fig. 8)

Only minimal steepening of the corneal centre could be observed after Excimer - Ablation. The central corneal curvature steepens less than intact cornea.

This right eye of a patient with a myopia of - 22,0 dpt showed during tilting a normal steepening of the central curvature. Fig. 3 and Fig. 4.



MEAN REFRACTION (DIOPTERS) OF CORNEA AFTER LASER ABLATION										MEAN REFRACTION CHANGE (DIOPTERS) OF CORNEA AFTER LASER ABLATION (DOWNRIGHT POSITION)										
Upright					Downright					Upright					Downright					
11.80	11.80	11.80	11.80	11.80	11.80	11.80	11.80	11.80	11.80	11.80	11.80	11.80	11.80	11.80	11.80	11.80	11.80	11.80	11.80	11.80
11.80	11.80	11.80	11.80	11.80	11.80	11.80	11.80	11.80	11.80	11.80	11.80	11.80	11.80	11.80	11.80	11.80	11.80	11.80	11.80	11.80
11.80	11.80	11.80	11.80	11.80	11.80	11.80	11.80	11.80	11.80	11.80	11.80	11.80	11.80	11.80	11.80	11.80	11.80	11.80	11.80	11.80
11.80	11.80	11.80	11.80	11.80	11.80	11.80	11.80	11.80	11.80	11.80	11.80	11.80	11.80	11.80	11.80	11.80	11.80	11.80	11.80	11.80
11.80	11.80	11.80	11.80	11.80	11.80	11.80	11.80	11.80	11.80	11.80	11.80	11.80	11.80	11.80	11.80	11.80	11.80	11.80	11.80	11.80
11.80	11.80	11.80	11.80	11.80	11.80	11.80	11.80	11.80	11.80	11.80	11.80	11.80	11.80	11.80	11.80	11.80	11.80	11.80	11.80	11.80
11.80	11.80	11.80	11.80	11.80	11.80	11.80	11.80	11.80	11.80	11.80	11.80	11.80	11.80	11.80	11.80	11.80	11.80	11.80	11.80	11.80
11.80	11.80	11.80	11.80	11.80	11.80	11.80	11.80	11.80	11.80	11.80	11.80	11.80	11.80	11.80	11.80	11.80	11.80	11.80	11.80	11.80
11.80	11.80	11.80	11.80	11.80	11.80	11.80	11.80	11.80	11.80	11.80	11.80	11.80	11.80	11.80	11.80	11.80	11.80	11.80	11.80	11.80

Fig. 8. Mean values of all RK-patients in upright position and mean values of differences in downright position.

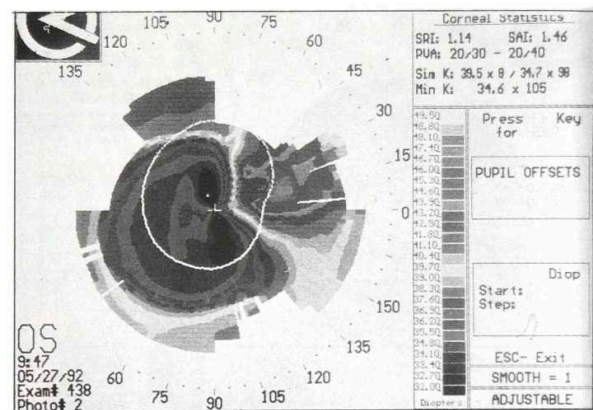


Fig. 9. Left eye after an Excimer-Laser correction of myopia of -22,0 dpt in upright position.

However, the same patient with an Excimer-Laser-Ablation of -22,0 dpt on his left eye, (Fig. 9) showed during tilting nearly no change of corneal topography. (Fig. 10)

Subjects after Excimer-Laser-Ablation showed, corresponding to the ablation depth, almost no change of corneal topography.

## Discussion

The major variable affecting long-term refractive stability after RK is the slow wound healing of the unsutured, not well adapted avascular incisions. We know from histological findings that even 7 years after surgery an active wound healing at these incisions can be found. Bowman's Membrane and the peripheral circular running collagen fibres are still fractured.

Other forces also tend to flatten the central cornea. Due to the pressure of the eyelids with each blink and daily changes of the intraocular pressure in lying and upright positions, the weakened cornea is exposed to a permanent stretching stress. This stress at a tissue with weak stability and prolonged wound healing causes in 20% of the cases a permanent progressive hyperopia.

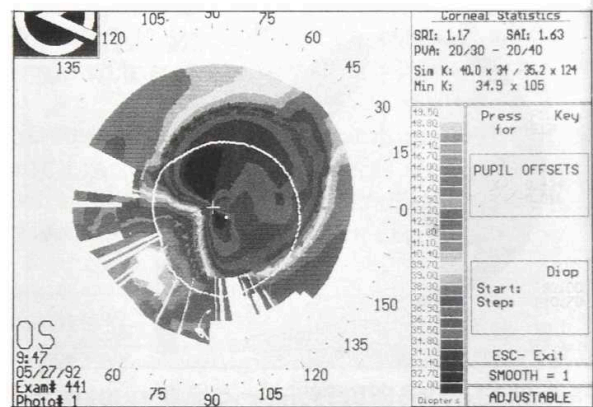
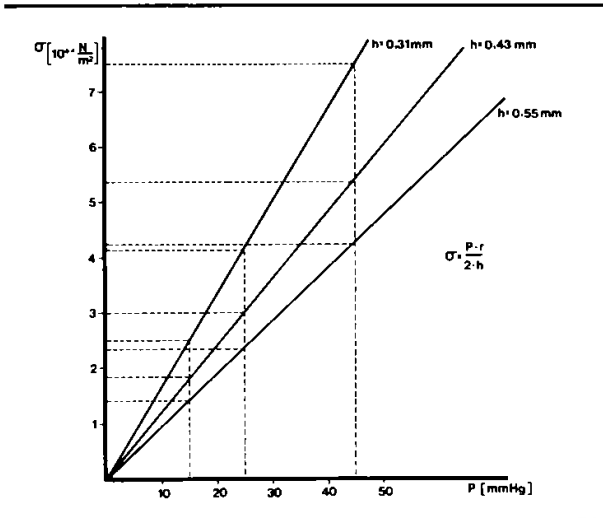


Fig. 10. Same cornea in downright position.

This finding can be brought into line with the Laplace equation (Fig. 11). The intraocular pressure causes a counter-acting tangential stress inside the cornea. This stress depends not only on the intraocular pressure, but also on the corneal radius and the corneal thickness. This stress stands for the tension the corneal stroma is exposed to. By elevating the intraocular pressure, by flattening the corneal radius and by decreasing the corneal thickness, this tension will be decreased.

Long-term studies about corneal stability must show if the ablated cornea, in particular higher



ig. 11 Laplace equation

degrees of ablation, with decreased elasticity is able to withstand the physiological intraocular pressure in order to guarantee a stable refraction.

## References

1. McDonell, P.J.; McIlusky, D.J.; Garbus, J.J.: Corneal topography and fluctuating visual acuity after radial keratotomy. *Ophthalmol.* 96:665 - 670, 1989
2. Nash, I.S.; Greene, P.R.; Foster C.S.: Comparison of mechanical properties of keratoconus and normal corneas. *Exp. Eye Res.* 35, 413 - 423, 1982.
3. Andreassen, T.T.; Hsorth Simonsen, A.; Oxlund, H.: Biomechanical properties of keratoconus and normal corneas. *Exp. Eye Res.* 31, 435 - 441, 1980.
4. Hanke, K.; Draeger, J.; Kirsch, K.: Untersuchungen des Augeninnendruckes in Abhängigkeit von der Körperhaltung und Hydratation. *Fortschr. Ophthalmol.* 81, 596 - 600, 1984.
5. Deg, J.K.; Zavala, E.Y.; Binder, P.S.: Delayed corneal wound healing following radial keratotomy. *Ophthalmol.* 92, 734 - 740, 1985
6. Krachmer, J.H.; Feder, R.S.; Belin, M.W.: Keratoconus and related non-inflammatory corneal thinning disorders. *Survey of Ophthalmol.*, Vol. 28, No 4, Jan./Febr. 1984.

# Lamellar keratoplasties - First results with a new automatic microkeratome

M. Kohlhaas, J. Draeger(\*)

---

## Summary

---

Since more than 100 years theoretical and practical reports are published about lamellar dissection techniques. Results after heterologous transplantation were because of decompensation of the lamellar transplant partially discouraging. First progresses were achieved by using homologous tissue. Immunological reactions of the eye e.g. decompensation of the transplants are hereby nearly out of question. With modern dissection techniques plano and smooth wound surface can be obtained which is advantageous for optical results. We present the results of our first 12 lamellar keratoplasties performed with the new automatic microkeratome. Results and woundhealing complications are discussed.

**Key words:** Lamellar keratoplasty - Automatic microkeratome - Corneal lamellar woundhealing

---

Phillip von WALTER was the first in the early 19th century who recommend the lamellar keratoplasty technique (14). His disciple Franz-Naver MÜHLBAUER reported 1840 in a prize winning publication about triangle lamellar transplants on rabbit eyes (13). DÜRR performed with rabbit corneas 1877 the first rectangular heterologous lamellar keratoplasties on human eyes (14). With the invention of the first clockwork-trephine 1877 von HIPPEL improved the important congruity between transplant and woundbed for his heterologous lamellar keratoplasties (11). However, PAUFIQUE deserves the honour for establishing a simple operation technique for lamellar procedures (15). Because of his good results he propa-

(\*) Hamburg University, Dep. of Ophthalmology (Head: Prof. Dr. J. Draeger)

gated 1948 the lamellar dissection techniques for optical and curative indications (15). Lateron HALLERMANN developed a simple device for manual dissection of lamellar lenticles (9, 10). However, BARRAQUER established a microkeratome for lamellar dissection on patient and donor eye which worked with an oscillating blade (2). The optical results after heterologous transplantation were because of decompensation and cloudiness of the lamellar transplant partially discouraging. By using lyophilized or desiccated heterologous transplants the results were more successful and could be improved. This indicates the most important point in corneal lamellar surgery. Immunological reactions of the uveal tract or an immunological decompensation of the transplant are nearly out of question. Especially by us-



ing homologous or autologous tissue for lamellar or lamellar refractive procedures. As opening of the anterior chamber is not necessary intraocular inflammations and other complications can be avoided. Thereby postoperative treatment is safer and easier. After lamellar dissection techniques a big woundbed regarding the chosen diameter is obtained. In comparison with penetrating keratoplasties the surface for woundhealing is up to four times bigger. Woundhealing in lamellar keratoplasties is different at the edges anterior and posterior surface of the transplants. Fibrocytes of the host and probably of the donor migrate at the edges and produce a circular stabile colagene scar at Bowman's membrane. The epithelium of the donor is rejected and replaced by the host. This epithelial growth is more important for the transplant stability than the adhesion forces in the woundbed. It's healing is prolonged the stroma might be affected. There is nearly no scar formation in the woundbed. Even years after lamellar dissections transplants can be removed easily from the woundbed. However, in the literature and in our own cases we never observed any wound ruptures or traumatic wound dehiscence like after penetrating keratoplasty or radial keratotomy (1, 3, 7, 8, 12, 17, 18).

One of the most important points regarding optical results and quality woundhealing is to achieve an absolutely plano and in particular smooth wound surface. However, these demands cannot be accomplished with manual dissection or microkeratomes with oscillating blades. Therefore we developed a microkeratome with high speed blade rotation which dissects automatically a lamellar under sufficient lubrication within 20 seconds on the patient's eye and even on the donor eye (4, 5, 6,). (Fig. 1).

During two years a lamellar keratoplasty were performed 12 times. The patient age ranged between 13 and 59 with a mean age of 35 years. The indications were 4 patients with keratoconus, 2 patients with recurrent pterygium, 2 patients af-




Fig. 1. Automatic microkeratome on patient's eye during dissection.

ter superficial chemical burning, 2 patients after herpetic keratitis and bacterial ulceration, 1 patient with epithelial dystrophia.

The lamellar dissection was performed in the same way on patient and donor eye with the automatic microkeratome.

## Results

The corneal woundbed showed after each dissection an absolutely plano and smooth surface. The wound edges were circular round and symmetric. Lenticles dissected from donor eyes showed the same morphological features, (Table 1). Due to the corneal thickness of our keratokonus patients we dissected lenticles of 9 mm diameter and a thickness of 2 - 3 mm: We performed 8 - 12 single knots. The post corrected preoperative visual acuity of 0,4 - 0,8 was not reached even 4 months after operation. The single knots were removed after 2 - 3 weeks. The postoperative astigmatism ranged between 0,5 and 3 cylinders. Even 4 months after operation we observed moderate rinces of descemet's membrane which decreased by time and caused moderate blurring sensation, like it is known after epikeratophakia for keratokonus. In patient No. 1 we observed epithelial disturbances decreasing visual acuity. In all

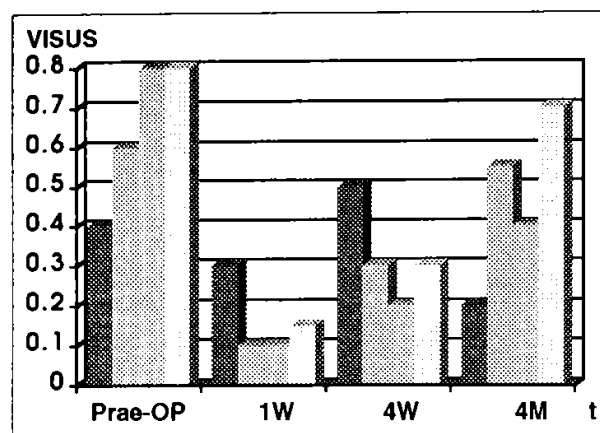


Table 1. Visual acuity of keratokonus patients before and after lamellar keratoplasty after 1 week, 4 weeks, 4 months.

cases the lamellar interface was almost invisible after 4 months. (Table 2).

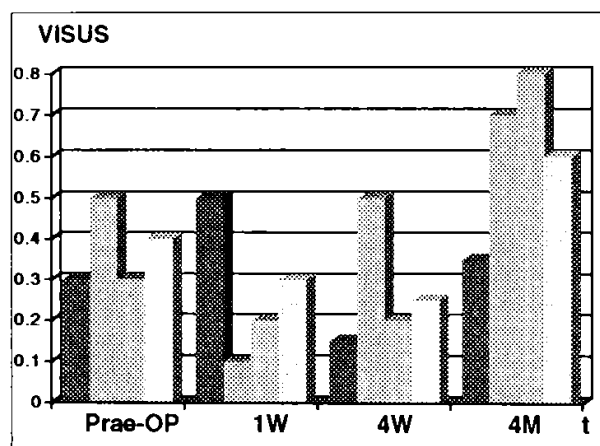


Table 2. Results after lamellar keratoplasty for epithelial dystrophia patient 1, patient 2, 3, 4, lamellar keratoplasty after chemical burning.

Lamellar transplants with a diameter of 9 mm and a thickness of 0,35 mm were performed with running sutures in the above cases. The postoperative visual acuity was much better than the preoperative. After removing the sutures the astigmatism ranged between 1 and 2,5 Dp. of cylinder. An epithelial metaplasia was observed in patient 1 which only slowly decreased under intensive local treatment.

The lamellar interface was almost invisible. (Table 3).

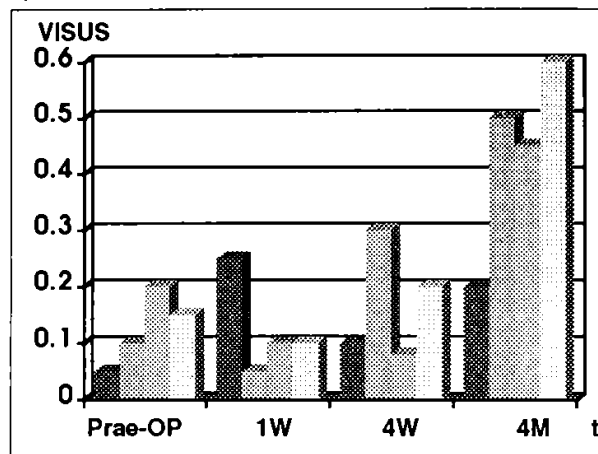


Table 3. Results after lamellar keratoplasty, patient 1 and 2 with recurrent pterygium and affected optical centre, patient 3 and 4 with corneal ulceration and herpetic keratitis.

In the above cases we dissected lenticles of 9 mm diameter and 0,3 mm thickness. The running sutures were removed after 2 weeks. In patient No. 1 we observed a stromal edema of the host cornea and a fluid in the interface mostly in nasal corneal parts but reaching the optical centre and decreasing the visual acuity. Patients 2, 3 and 4 showed a normal woundhealing and an enormous increase of visual acuity 4 months later.

This patient (fig. 2) with keratokonus showed 4 months after lamellar keratoplasty a clear cornea, the wound edges are smooth and almost invisible. The best corrected visual acuity was 0,7 and the patient complaint a little bit about blurring due to really moderate ripples at Descemet's membrane. The above picture (fig.3) showed a 65 year old lady 3 weeks after lamellar keratoplasty for treatment of recurrent pterygium with affected optical centre. A stroma edema and some deposits in the interface are visible. This might be a sign for low endothelial function and low corneal metabolism that in this case probably a penetrating keratoplasty could have been better.

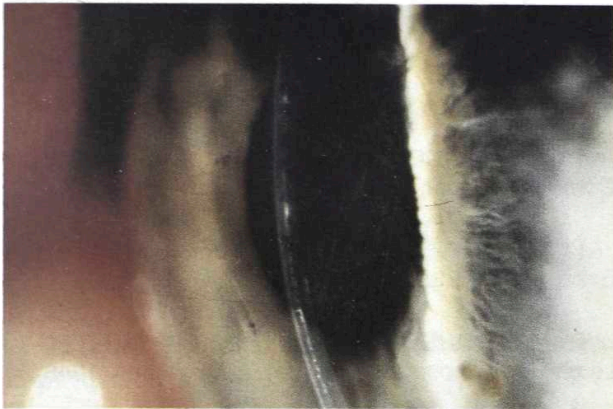


Fig. 2. Lamellar keratoplasty of keratoconus 4 months after operation.

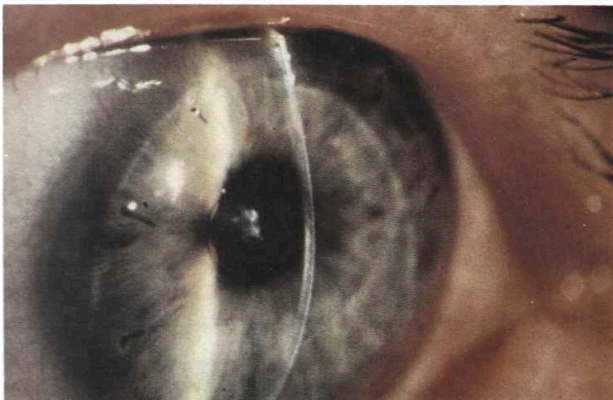


Fig. 3. Lamellar keratoplasty of recurrent pterygium 3 weeks after operation.

## Discussion

One aim in lamellar keratoplasty is to dissect a regular and smooth surface. If a surface is not regular or if blood vessels and stromal opacities remain after dissection lipoids, calcium crystals and hyaline degenerations could be sedimentated in the interface. These deposits might grow and impact considerably the optical result. An intact corneal metabolism and an excellent woundbed and op-

eration technique might be helpful to avoid these complications.

Because of the mechanical flattening of keratokonus eyes during suturing the corneal tissue is compressed, which leads to rinckles at Descemet's membrane. However these rinckles disappear by time and the visual acuity increase.

The automatic rotor microkeratome is a simple and precise surgical instrument. It is possible to dissect plano and round lenticles with smooth surface on the patient eye and even on the donor eye. By using this microkeratome for anterior stromal scars, opacification, vascularisation or surface irregularities lamellar keratoplasties might be less complicated faster and safer than penetrating keratoplasties.

## References

1. AHRENDSON, J.J., MORGAN, B., GREEN, W.R.: Changing indications for keratoplasty. *Am. J. Ophthalmol.* 81: 313 (1978).
2. BARRAQUER, J.: Technique of lamellar keratoplasty. Presented at the Interamerican Symposium on corneal and external eye diseases, Gainesville, Florida, Okt. (1969).
3. BUXTON, J.M.: Lamellar keratoplasty: Indications. In: King, J.H., McTeeg, J.W. (Eds.) *The Cornea World Congress*, London (1965), Butterworth & Co.
4. DRAEGER, J.: Ein halbautomatisches elektrisches keratom für die lamelläre keratoplastik. *Klin. Mbl. Augenheilkd.* 167: 353 (1975).
5. DRAEGER, J., GRABNER, G., BÖHNKE, M., BAUMGARTNER, I., SLEZAK, H., NAUMANN, G.O.H.: Überlegungen für eine optimierte lamelläre Schneidtechnik. *Fortschr. Ophthalmol.* 85: 251 (1988).
6. DRAEGER, J., BÖHNKE, M., KLEIN, L., KOHLHAAS, M.: Experimentelle Untersuchungen zur



Präzision lamellärer Hornhautschnitte. Fortschr. Ophthalmol. 86: 272 (1989).

7. GASSET, A.R., DOLEMAN, C.H.: The tensile strength of corneal wounds. Arch. Ophthalmol. 79: 595 (1968).

8. GLASGOW, B.J., BROWN, H.H., AIZUSS, D.H., FOOS, R.Y.: Traumatic Dehiscence of Incisions 7 Years after Radial Keratotomy. Am. J. Ophthalmol. 106: 703 (1988).

9. HALLERMANN, W.: Indikation und Ergebnisse der lamellierenden Keratoplastik, Entwicklung und Fortschritt in der Augenheilkunde. Fortbildungskurs für Augenärzte, Hamburg (1962), Ferdinand-Enke-Verlag, Stuttgart (1963).

10. HALLERMANN, W., SCHROEDER, G.M., SALEHI, A.N.: Ergebnisse der lamellären Keratoplastik bei rezidivierenden Pterygien. Klin.Mbl. Augenheilkd. 171: 191 (1977).

11. von HIPPEL, A.: Über die operative Behandlung totaler stationärer Hornhauttrübungen. Graefe's Arch. 23, II, 79: (1977).

12. MALBRAHM, E.: Lamellar keratoplasty in keratoconus. In: King, S.H., McTeag, J.W. (Eds): World Congress on the Cornea. Washington D.C., (1965).

13. MÜHLBAUER, F.X.: Über die Transplantation der Cornea. Lindauer, München (1840).

14. MÜNCHOW, W.: Geschichte der Augenheilkunde. Enke. Verlag, Stuttgart (1984).

15. PAUFIQUE, L., SOURDILLE, G.P., OFFRET, G.: Le grave de la cornée. Masson, O. Cie. Paris (1948).

16. PEARLMAN, G., SUSAL, A.L., HUSHAW, J.: Recurrent pterygium and treatment with lamellar keratoplasty with presentation of a technique to limit recurrences. Ann. Ophthalmol. 2: 763 (1970).

17. RABER, I.M., AHRENDSEN, J.J., LEIPSON, P.R.: Traumatic wound dehiscence after penetrating keratoplasty. Arch. Ophthalmol. 98: 1407 (1980).

18. O-WOOD, T.: Lamellar transplants in keratoconus. Am. J. Ophthalmol. Vol. 83: 543 (1977).

# Should we consider clear lens extraction for routine refractive surgery?

Theodore P. Werblin, M.D., Ph.D.(\*)

Traditionally refractive surgeons have regarded the cornea, the strongest refracting element in the eye, as the primary target for surgical modification. Despite decades of work generally concerned with reshaping or remodeling this surface, major repetitive problems continue to plague these concepts; unpredictable wound healing, less than total safety, loss or instability of refractive effect, and generally less than perfect predictability, all remain as unsolved and perhaps insoluble problems.

In order to satisfy the ultimate requirements for refractive surgery, we must develop a procedure(s), whose accuracy is comparable to that of prescribing eyeglasses, whose reversibility is comparable to that of contact lenses and whose safety is reasonably assured. In actuality, the most common refractive procedures involve the crystalline lens, not the cornea - i.e., cataract surgery. The technical requirements of lens surgery are within the grasp of most ophthalmic surgeons. What prevents us from utilizing the removal of the crystalline lens as a routine refractive surgical procedure? Specifically the correction of myopia, hyperopia, astigmatism (excluding irregular corneal astigmatism) and even presbyopia theoretically may be possible with lens extraction and intra ocular (IOL) implantation. Although lens extraction in high myopia may have an unavoidably high morbidity because of retinal detachment<sup>1</sup> and IOL implantation without crystalline lens extraction (phakic IOL) may also create long-term corneal pathology,<sup>2,3,4</sup> lens

extraction in relatively normal eyes by experienced cataract surgeons may have an acceptable risk/benefit ratio.

How can one define the relative risk and benefit of the removal of the crystalline lens with intraocular lens implantation for *routine* refractive surgery? The major risks of intraocular surgery are obvious. Retinal detachment, cystoid macula edema, endophthalmitis, and retrobulbar hemorrhage would be all characterized as major risk factors for most intraocular procedures. However, in the refractive surgical population some of these risks may prove to be somewhat less significant than what is routinely seen in cataract surgery. The most frequent intraoperative complication is rupture of the posterior capsule and vitreous loss, complications generally associated with a dense nucleus and/or a poorly dilating pupil, which rarely occur in refractive surgical patients aged 21 to 50. Nevertheless, even with uneventful cataract surgery, there appears to be an increased risk of retinal detachment, estimated at 1%<sup>5</sup>, although my personal experience with 2000 consecutive cases, suggests that routine uncomplicated phacoemulsification surgery has less than 0.1% risk. Even with retinal detachments following cataract surgery, the ability to repair the detachment will yield a satisfactory visual outcome (greater than 20/50) in 55% of cases.<sup>6,7,8</sup> Also, it is possible that the careful preoperative evaluation of the retina by a retinal surgeon with prophylactic treatment of retinal holes, etc., as is done for intraocular lens surgery in high myopia<sup>9</sup>, may reduce postoperative retinal detachment in both high risk and "normal"

(\*) Associate Clinical Professor of Ophthalmology, University of Virginia, Charlottesville, VA  
The author has a proprietary interest in the IOL device discussed in this article.

eyes. Therefore one would expect that in this patient population the risk of retinal detachment with significant visual loss following intraocular surgery would be well below one percent.

Other complications related to intraocular surgery are significantly less frequent than that of detachment, such as cystoid macular edema, endophthalmitis, and retrobulbar hemorrhage. Refractive complications such as induced astigmatism and refractive problems associated with tilt are theoretically correctible. Other technical complications such as decentration and dislocation would be significant complications, but occur at such an infrequent rate, that they would not significantly affect the overall risk. I would therefore conclude that in experienced hands the incidence of permanent visual loss resulting from an intraoperative or postoperative complication of intraocular lens surgery would be at most between 0.50 and 1.00 percent.

What would be the benefit of an intraocular lens for refractive surgery? Current IOL technology, yields a refractive accuracy of plus or minus one diopter<sup>10</sup> which would indicate that conservatively 65% of patients would be 20/40 or better uncorrected, postoperatively. Corneal surgery, such as radial keratotomy *with enhancement procedures* yields an accuracy of plus or minus 0.6 diopter suggesting that roughly 97% of patients are 20/40 or better uncorrected<sup>11</sup>. There are, in varying stages of development, intraocular lenses whose postoperative refractive results can be modified, and these lens systems will theoretically generate a refractive accuracy of at least plus or minus 0.25D sphere and cylinder resulting in at least 95% of patients 20/25 or better uncorrected<sup>(\*)</sup>. The MC-IOL additionally should have capabilities for accurately correcting induced, regular astigmatism and reversibly introducing a multifocal component if desired, thus negating the loss of accommodation.

(\*) Currently under development are intraocular lenses where multiple interchangeable components (MC-IOL) allow modification of postoperative sphere, cylinder and multi-focal capabilities.

Since most refractive patients, (mean age 38 years), are at the end of the 4th decade of life, their ability to accommodate will soon deteriorate, with or without refractive surgery and therefore the potential of generating pseudo accommodation for these patients is an additional and almost mandatory feature. Although multi focal lens development is in its infancy, the largest single problem with these procedures in relation to cataract surgery appears to be inaccuracies in the refractive result, which are inherent in current intraocular lens design and intraocular lens surgery. Again, the MC-IOL system where refractive parameters can be modified with additional postoperative surgical or enhancement procedures will obviate this problem.

In conclusion, it appears that the risk of loss of significant visual function as a result of intraocular surgery for refractive purposes may be, at most, between one half and one percent. The benefit of intraocular surgery, given the new technology described above, could yield refractive accuracies of 20/25 or better in at least 95% of patients. There is no question that the risk of visual loss from intraocular surgery is slightly greater than from refractive corneal surgery. However, the risk in corneal procedures is not insignificant. In addition, all of the visual side effects, variable vision, starbursting, etc., would be obviated by leaving the cornea intact and using an intraocular lens for the refractive modification of the eye which historically has far fewer problems with visual distortion. Although the risk in intraocular surgery is somewhat greater, risks equal to or greater than this are taken routinely by patients in every day life. For example, on an accumulative basis, there is roughly a 1.6% chance of developing corneal ulceration during a lifetime of contact lens usage<sup>12,13</sup>, and there is roughly a 0.5% life time chance of an individual being killed driving his automobile<sup>14,15</sup>. Therefore the risk of significant visual loss from intraocular surgery, which is within this order of magnitude, is acceptable for most people, and should not detract from the benefit of this proce-

sure, life-long, spectacle free, distance and near vision. The author wishes to express his appreciation for commentary on this article by the following physicians who read and critiqued this work prior to its publication. Space did not permit publication of their commentaries.

Perry Binder, M.D.

Charles Casebeer, M.D.

Dave Delaney, M.D.

Daniel Durrie, M.D.

Paul Fechner, M.D.

Buol Heslin, M.D.

Jorg Krumeich, M.D.

Akira Momose, M.D.

Charlie Moore, M.D.

J.J. Rowsey, M.D.

John Sheppard, M.D.

Franco Verzella, M.D.

Bruce Wallace, M.D.

Also the author wishes to acknowledge Dr. Dan Krider, Chairman of the Mathematics Department, Concord College, Athens, WV for his assistance with the statistical analysis used in this paper.

---

## References

---

1. Goldber, M.F. Clear lens extraction for axial myopia. *Ophthalmol.* 1987; 94: 571-582
2. Peiffer, R.L., Porter D.P., Eifrig, D.E. and Boyd, J. Experimental evaluation of a phakic anterior chamber implant in a primate model. Part 1. Clinical observations. *J Cataract Refract Surg.* 1991; 17: 335-341.
3. Fechner, P.U., Strobel, J. and Wichmann, W. Correction of myopia by implantation of a concave worst-iris claw lens into phakic eyes. *Refract Corneal Surg.* 1991; 7: 286-298.
4. Saragoussi, J.J., Cotinat, J., Fenard, F., Savoldelli, Abenhaim, A. and Pouliquen, Y. Damage to the corneal endothelium by minus power anterior chamber intraocular lenses. *Refract Corneal Surg.* 1991; 7: 282-285.
5. Kraff, M.C., Sanders, D.R., Incidence of retinal detachment following posterior chamber intraocular lens surgery. *J Cataract Refract Surg.* 1990; 16: 477-480
6. Burton, T.C. Postoperative factors influencing anatomic success rates following retinal detachment surgery. *Trans AAO and Otolar.* 1977; 83:499-505.
7. Burton, T.C. Recovery of visual acuity involving the macula. *Trans AOS.* 1982; 80: 475-597
8. Hilton, G.F., et al. *Ophthalmology monograph: Retinal detachment.* AAO. 5th Edition. 1989.
9. Verzella F. High myopia; in-the-bag refractive implantation. *Ophthalmic Forum* 1985; 3: 174 - 5.
10. Werblin, T.P. Lamellar refractive surgery: Where have we been and where are we going? *Refract Corneal Surg.* 1989; 5: 167-176.
11. Werblin, T.P. Radial Keratotomy in the US: An evolving procedure. In *Preparation Ophthalmol.* 1993.
12. Schein, O.D., and Poggio, E.C. Ulcerative keratitis in contact lens wearers. *Cornea* 1990; 9: S55-61.
13. Glynn, R.J., Schein O.D., et al. The incidence of ulcerative keratitis among aphakic contact lens wearers in New England. *Arch Ophthalmol.* 1991; 109: 104 - 107.
14. Accident Facts. The National Safety Council, 1991: 90-91.
15. Auto and Traffic Safety. National Highway Transportation Safety Association. U.S. Department of Transportation. Vol 1: 1 Summer 1991.



# Extensión del uso de la operación de Fasanella y Servat

Javier Servat U. (\*)

## Resumen

La técnica quirúrgica original para ptosis mínimas, de Fasanella y Servat (1961), ha sido en los últimos años ligeramente modificada para poder ser usada en las ptosis moderadas y severas. Las técnicas son denominadas OFS 1, OFS 2 y OFS 3. Los resultados con la OFS 3 para las ptosis severas son espectaculares con ejecución muy fácil y con ella se suprime la mortificante lagofthalmía en el post-operatoto.

## Introducción

La operación de Fasanella y Servat (OFS) es considerada como una resección en bloque de tres estructuras importantes de la elevación: conjuntiva, tarso y musculo de Müller.

El presente trabajo tiene por objeto demostrar que la conjuntivo-tarso-müllerectomía original, con ciertas modificaciones (resección pequeña o moderada del elevador), permite tratar la mayor parte de casos de ptosis. A nuestra manera de entender, ptosis es el descenso manifiesto (mayor de 1 mm) de uno de los cuatro párpados en relación a la cornea.

Con fines didácticos vamos a designar a los cuatro párpados con la siguiente nomenclatura: P1, P2, P3, P4, siguiendo el sentido de las agujas del reloj, empezando en el párpado superior derecho.

Para entender el uso extensivo de la OFS, debemos considerar los siguientes grados de ptosis:

Minimas: 1.5 a 2 mm.

(\*) Director del Instituto de Oftalmología de la Universidad Nacional de Trujillo, España

- Moderadas: 2.5 a 3.5 mm.
- Severas: 4 mm ó más.

## Descripción de la técnica

A continuación, pasamos a describir la técnica original y las modificaciones creadas en nuestro instituto (OFS 2 y OFS 3).

### OFS 1 (Fasanella y Servat)

Conjuntivo - tarso - müllerectomía.

### Indicaciones:

- Ptosis congénitas y adquiridas mínimas;
- Surco palpebral superior (SPS) presente bueno, moderado o ausente.
- Test de neosinefrina preoperatorio: positivo (2 mm).
- Función del elevador: 5 mm. ó más.

### Anestesia: Local o general

*Local:*

- Colocar a 1.5 cm del canto externo y por debajo de la ceja 1.5 a 3 cc ó 0.5 a 1 cc,

subconjuntival de lidocaína 2% sin epinefrina, en el fondo de saco superior con el párpado evertido.

*Instrumental:*

- Jeringa descartable (5 cc).
- Aguja G-25 de 5 cm de longitud.
- Regla oftálmica del servicio (con doble evertor, dermatómetro y regla de ptosis).
- Dos pinzas "mosquito" curvas "mochas" o "truncas" (Arch Oftal Nor Perú 22: 57, 1989).
- Tijeras tipo Stevens.
- Mango de bisturí Bard Parker, hoja No. 15.
- Portaaguja
- Cauterio
- Nylon 5-0 ó 6-0.

*Técnica:*

- Eversión simple de P1 ó P2.
- Medir la altura del tarso.
- Atricción del borde convexo del tarso a 1/3 de la altura con los mosquitos "mochos" con la curvatura opuesta a dicho borde superior.
- Resección del tarso con bisturí Bard Parker hoja No. 15, por debajo de los mosquitos.
- Cauterización del borde cruento con los mosquitos aún colocados.
- Sutura continua a 1 mm. sobre los mosquitos con nylon 5-0 ó 6-0 cada 3 mm.
- Los cabos quedan colgando en los cantos: interno 2 cm, externo 4 cm.
- Retirar la sutura a las 48 ó 72 horas.

*Ventajas:*

- No se traumatiza el párpado, evitando la formación de hematomas.
- Los mosquitos "truncos" evitan el sangrado en el centro de la atricción y la deformación post-operatoria de la apertura palpebral.
- La sutura puede ser retirada muy rápidamente y con facilidad.

**OFS 2**

Conjuntivo-tarso-müllerectomía con inclusión y resección del elevador plegado.

*Indicaciones:*

- Ptosis congénitas y adquiridas moderadas.
- SPS presente, atenuado o ausente.
- Test de neosinefrina preoperatorio: positivo
- Función de elevador: 5 mm ó más.

*Instrumental*

- Jeringa descartable (5 cc).
- Aguja G-25 de 5 cm de longitud.
- Regla oftalmológica del servicio (con doble evertor, dermatómetro y regla de ptosis).
- Dos pinzas "mosquito" curvas "mochas" o "truncas" (Arch Oftal Nor Perú, 22: 57, 1989).
- Depresor del elevador (Dr. Pérez).
- Tijeras tipo Stevens.
- Pinza con dientes, fuerte.
- Portaaguja.
- Cauterio.
- Nylon 5-0 ó 6-0.

*Técnica:*

- Eversión simple de P1 ó P2.
- Medir la altura del tarso.
- Plegamiento del elevador con el depresor.
- Atricción del borde convexo del tarso a 1/3 de su altura con los mosquitos "truncos" con su curvatura opuesta a dicho borde superior.
- Resección del tarso con bisturí Bard Parker, hoja No. 15, por debajo de los mosquitos aún colocados.
- Sutura continua alta a 2 ó 3 mm sobre los mosquitos con nylon 5-0 ó 6-0.
- Los cabos quedan colgando en los cantos: interno 2 cm, externo 4 cm.
- Retirar la sutura a las 48 ó 72 horas.

*Ventajas:*

Mediante una simple maniobra logramos incluir al elevador en una OFS simple, creando un efecto mayor que nos permite corregir aproximadamente 3 mm de caída, que es suficiente para la corrección de una ptosis moderada.

**OFS 3 (Servat - Manrique)**

Conjuntivo-tarso-müllerectomía con resección moderada del elevador a través de una OFS sin suturas.

*Indicaciones:*

- Ptosis severas y paralíticas.
- SPS ausente.
- Test de neosinefrina preoperatorio: nulo.
- Función del elevador: menos 4 mm (4 a 0).

*Instrumental:*

- Jeringa descartable (5 cc).
- Aguja G-25 de 5 cm de longitud.
- Regla oftalmológica del servicio (con doble evertor, dermatómetro y regla de ptosis).
- Dos pinzas mosquito curvas "mochas" ó "truncas" (Arch Oftal Nor Perú, 22: 57, 1989).
- Gancho especial semejante al usado en cirugía de estrabismo (20 mm) creado en nuestro servicio.
- Dos pinzas rectas con dientes cada 3 mm (Arch Oftal Nor Perú, 22: 57, 1989).
- Aguja para suspensión con nylon calibre 0, confeccionada en nuestro servicio (Arch Oftal Nor Perú, 22: 57, 1989).
- Tijeras tipo Stevens.
- Mango de bisturí Bard Parker, hoja No. 15.
- Portaaguja.
- Cauterío.
- Pinza de Berke para ptosis.
- Nylon 5-0 ó 6-0.

*Técnica:*

- Eversión simple de P1 ó P2.
- Medir la altura del tarso.
- Atricción del borde convexo del tarso a 1/3 de la altura con los mosquitos "mochos" con su curvatura opuesta a dicho borde superior.
- Resección del tarso con bisturí Bard-Parker, hoja No. 15 por debajo de los mosquitos aún colocados.
- Prescindimos de la cauterización.
- Retiramos los mosquitos "mochos".
- Colocamos las pinzas rectas especiales, en forma vertical hasta el fondo del saco, paralelas, a 18 mm. de distancia.
- Damos una doble voltereta al tarso con las pinzas rectas especiales puestas hacia el cirujano o frente del paciente.
- Hacemos un ojal en la conjuntiva por dentro del borde de las pinzas rectas.
- Pasamos el gancho especial a través de la inserción del elevador.
- Ampliamos la incisión de la conjuntiva hasta los fondos del saco.
- Levantamos la conjuntiva con el músculo de Müller adherido a ésta.
- Disecamos el elevador seccionando los alerones o cuernos.
- Retraemos al elevador doblado con el gancho especial, medimos 7 mm. desde la inserción (el doble: 14 mm).
- Pinzamos el elevador con un mosquito recto o la pinza de Berke a 7 mm (doblado).
- Seccionamos la inserción del elevador con tijeras de Stevens.
- Colocamos tres puntos de sutura con nylon 5-0 ó 6-0 reinsertando el elevador en su inserción original.
- Resecamos el elevador sobrante.
- Colocamos la conjuntiva replegada en su sitio original.
- Sutura continua con nylon 5-0 ó 6-0 con puntos cada 3 mm. (como en una OFS 1).
- Los cabos quedan colgando en los cantos: interno 2 cm. externo 4 cm.
- Retiramos la sutura a las 72 horas (tres días).

**Nota:** Llevar nylon quirúrgico calibre 0 y aguja G-22 de 5 cm. de longitud, por si hubiera ausencia de elevador y se requiere una suspensión.

#### *Ventajas:*

Las ptosis con ausencia de elevación han sido tratadas preferencialmente con suspensiones o con grandes resecciones del elevador vía cutánea más o menos 28 mm, siguiendo la idea de Blaskovics del acortamiento de las estructuras del párpado, para corregir la ptosis.

Estas suspensiones y grandes resecciones de una estructura, se complican en el postoperatorio con una "lagofthalmía" mortificante. La OFS 3 preconiza: la resección de todas las estructuras en cantidad proporcional, es decir:

Elevador: 14 mm.  
 Conjuntiva: 6 mm.  
 Tarso: 3 mm.  
 Müller recortado: 2 mm.  
 Müller avance: 3 mm.

Una OFS 3 de 28 mm, pero repartidos proporcionalmente entre todas sus estructuras, de allí que en el postoperatorio no exista la "lagofthalmía" descrita anteriormente y al contrario se presenta un cierre casi perfecto de los párpados. Lo que puede quedar es una redundancia de piel, que debe ser extirpada en el mismo proceder o en un segundo procedimiento con lo cual se completa una verdadera resección en bloque del párpado; hecho que difiere de la concepción de Blaskovics del acortamiento de una estructura, por la lógica del acortamiento proporcional de las estructuras sugeridas en nuestra técnica.

#### **PTOSIS - CASOS ESPECIALES**

Casos especiales en los cuales la OFS da muy buenos resultados:

- 1- Síndrome de Horner: OFS 1.
- 2- Marín Amat (inverso Marcus Gunn): OFS 1

- 3- Ptosis postoperatoria (catarata, D.R.): OFS 1
- 4- Miastenia gravis: OFS 2 u OFS 3.
- 5- Marcus Gunn (fenómeno masticación-parpadeo): OFS 2 u OFS 3.

La mayor parte de casos de ptosis pueden ser tratados quirúrgicamente mediante estas tres variantes de la OFS. Sin embargo, en caso de desinserciones de la aponeurosis del elevador de la cara anterior del tarso (inserción de Zinn) se utiliza la vía cutánea para su búsqueda y reinserción. En caso de no encontrarse o que hubiera ausencia del elevador, se procederá a realizar una suspensión con aguja G-22 de 5 cm. de longitud, a la que se le ha quitado el plástico y se le ha colocado nylon quirúrgico calibre 0. Esta aguja atraumática puede ser fabricada fácilmente en la sala de operaciones.

En los pacientes de edad avanzada se detecta con frecuencia exceso de piel, que puede ser extirpada previa medida con el dermatómetro (regla de ptosis) durante el mismo procedimiento de Fasanella y Servat o en una etapa posterior.

La presencia de hernias de grasa y flacidez de la piel de los párpados (dermatochalasis) requiere un tratamiento independiente de la OFS. Puede hacerse antes o después de ella, pero su corrección precisa de la extirpación de la grasa y cierre de las zonas debilitadas del septum.

En caso de ptosis simultánea superior e inferior de un lado P1-P4 ó P2-P3, o de una ptosis y una retracción del mismo lado, el segmento de tejido extirpado durante la OFS, puede ser utilizado para levantar el párpado caído en caso de ptosis del párpado inferior y bajar el párpado superior en caso de retracción (Quickert, Crawford).

Finalmente, si no existe un SPS, su creación se hace en forma muy satisfactoria mediante el método de Pang, descrito en nuestro Manual de Ptosis del Instituto de Oftalmología de la Universidad Nacional de Trujillo (1990).

---

## Referencias bibliográficas

---

1. Beard, C. Ptosis. 1st. ed. St. Louis: The C.V. Mosby Co., 1969.
2. Beard, C. Blefaroptosis repair by modified Fasanella-Servat operation. Am. J. Ophthalmol. 69: 850, 1970.
3. Beard, C. Ptosis, 3rd. ed. St. Louis: The C.V. Mosby Co., 1981.
4. Fasanella R., Servat J. Levator resection for minimal ptosis: another simplified operation. Arch Ophthalmol 65: 493, 1961.
5. Fox S. Modified Fasanella-Servat procedure for ptosis. Arch. Ophthalmol. 93: 639, 1975.
6. Isi C. Citado por Fasanella R: Surgical for minimal ptosis; the Fasanella-Servat operation. Trans Ophthalmol. Soc. Uk 95: 425-436, 1973.

# Manual Extracapsular Surgery Mini Nuc Technique



Michael Blumenthal (\*)

The many different technologies in cataract surgery and intraocular lenses available today leave some ophthalmologists confused. The proposed technique is one of the most cost effective procedures, while at the same time the outcome is considered to be of the highest quality cataract surgery.

Basic surgical principle is to perform cataract surgery under the following conditions:

1. Anterior chamber maintaining system, achieved by continuous BSS flow from BSS bottle through anterior chamber maintainer (ACM) to the eye.
2. The above system provides the ability to control intraocular pressure during surgery.
3. Availability of both these conditions provides a system for controlling any surgical technique.

This system opens new avenues for manual extra cap. It proves to be equally effective in countries where sophisticated instrumentation may not be available as well offering the possibility of reducing the constantly escalating surgical expenditures.

**First stage:** The first stage of the MINI NUC technique (mini nuc stands for mini nuc(leus)) is the preparation of two entries made by a 1 mm wide stiletto knife. The incision at 11 o'clock is used for introducing manipulation instruments like capsulotomy needle, hydrodissector cannula, as-

piration cannula, spatula for epinucleus manipulation and Sinsky hook for lens manipulation. The second entry is for introducing the anterior chamber maintainer (ACM) performed by the same stiletto knife at 5 o'clock, scleral tunnel-like incision. This entry is so designed for introducing the ACM and for stable fixation. The ACM is made like a cannula, 2.5 mm long, with small ring elevations on its outside surface. It has a 1 mm outside dimension and a 0.6 mm inner diameter (nearly approximating a 20 gauge needle). The ACM is connected by a silicone tube to a BSS bottle hung on a post where the bottle height can be changed according to the IOP selected during the different stages of the operation.

Positive IOP during cataract surgery is advantageous due the following reasons:

- a) From a surgical point of view the ACM system provides the best available controlled surgery, a condition in which any surgical maneuver will not disturb the normal internal anatomical relationship in the eye. These conditions are achieved by the ACM constantly irrigating the eye and simultaneously controlling the positive intraocular pressure. Any fluid lost is instantaneously recovered, due to the large internal diameter of the ACM, ensuring the mechanism of controlled surgery.
- b) There is constant flow from inside the eye out. This flow continuously washes out from the eye during surgery all debris of blood, pigment, and leftover cortical material. Practically this flow keeps the eye clean of any future inflammatory particles.
- c) Low turbulence and low fluctuation of AC depth during surgery result in low quantities of prostaglandin and low leukotriens, which

(\*) From the Chaim Sheba Medical Center  
Maurice and Gabriela Goldschleger.  
Eye Institute affiliated to the Tel-Aviv University Sackler School of  
Medicine Tel Hashomer Israel.

also indicates less post-operative inflammatory reaction.

- d) Bacteria is mostly prevented from entering the eye, and constantly washed out of the eye if it does enter.
- e) The BSS bottle can be used as a reservoir of pharmacological drugs to be continuously fed to the eye, such as adrenalin 1:1,000,000 to keep the pupil dilated, antibiotics, or any other drug of choice one wishes to have during surgery.

At present state, the art of planned extra cap does not follow this principle. Thus there are long periods of time when the eye is under hypotony.

Generally in planned extra cap without ACM or positive IOP there are long periods of time when the eye is under hypotony or low IOP, causing technical difficulties during surgery and at the same time increasing the possibility of post-operative inflammation.

**Capsulectomy:** To create a true capsular bag, it is obligatory to perform a round, continuous tear with smooth edges and no break at any point by capsulorhexis. The term round does not relate to a geometrical configuration but rather to any configuration without a protruding angle: a circle, ellipse, heart or clover leaf shape. Any radial tear at the capsulectomy margin would perform a false bag, causing the IOL loops (not necessarily the optic part) to find themselves to be in touch with uveal tissue and in due time could cause complications like hemorrhage, uveitis, macular edema, etc. The cystotome of preference is a 25 gauge needle. The bevelled tip which is 0.3 mm long is bent over at 90°, then twisted an additional 90° so that the cutting edge lies parallel to the main axis of the cystotome. Using a cystotome there is a need for only a 1.0 mm opening for the capsulotomy maneuver, while the anterior chamber is well maintained by the ACM. When using forceps an opening of 3.0 mm is needed, obviously

inducing an open system, which forces us to use viscoelastic material to maintain the AC during capsulotomy.

Collapse or shallowing of the AC is associated with an anterior movement of the lens. If this occurs during capsulectomy it might result in momentarily uncontrolled tear, often extending to the equator. It is essential to force the lens backward as much as possible by maintaining high IOP. High pressure in the anterior chamber pushes the lens zonule diaphragm backwards. This results in maximal relaxation of the anterior capsule, a manipulation which allows maximum control of the capsulectomy, and not depending on viscoelastic material. The propagation of the capsular tear is best evaluated in the presence of a bright red reflex. In its absence, even in mature cataract, one can use other guidelines such as capsule reflex, defraction at the capsule tear area, or by following the movement of the free capsule flap induced by the ACM flow.

It is ideal to create a capsulotomy not larger than 6.0 mm in diameter, to avoid the zonules which are attached 1.5 mm on the anterior capsule measured from the equator. A small capsular opening 5.0-6.0 mm limited to the zonule-free area inside the zonular frontier, means a difficult, sometimes impossible nucleus expression by conventional external pressure. The application of external pressure in such cases may result in vitreous loss through the torn zonules or in pushing the nucleus into the vitreous. In order to overcome this difficulty and avoid these complications, many surgeons perform one or more radial tears at the capsulotomy margin (relaxing incision, episiotomy). These radial tears, seemingly harmless, virtually convert a "true bag" into a "false bag" and all the efforts to perform a round capsulotomy by capsulorhexis were actually in vain. It is essential to save the round capsulotomy as this would keep the OIL isolated from the uvea, preventing



most complications due to loops touching the uvea.

How to achieve this goal of removing the nucleus while deepening the round capsulotomy intact? The following is the way:

***Nucleus Manipulation:*** Nucleus extraction is performed in two steps. The continuous small capsule margin stands a high degree of stretch without tearing. The adult nucleus diameter is usually larger than the diameter of the round capsulotomy. In manual ECCE with big limbal incision open eye system, the expression of the nucleus has to be induced by outside pressure on the eye. This pressure is transmitted to the inner structures of the eye, producing pressure differences between the induced high pressure in the eye and the atmospheric pressure outside the eye, thus pushing the whole zonule capsule diaphragm and the nucleus anteriorly. This pressure transmitted anteriorly is not directed to the nucleus specifically, but the pressure rather spread to the whole area of zonule capsule diaphragm. This may cause a possible complication such as vitreous loss, tear of zonules, tear of capsule, or even nucleus drop into vitreous, complications which all of us encounter and try to reduce to a minimum. The way to prevent these complications is explained as follows: The mini nuc technique is a closed system results in a steady fixed lens in the presence of deep AC which leads the way to dissect the crystalline lens in situ and isolate the smallest nucleus possible. The positive pressure in the AC pushes the zonule capsule diaphragm backwards and creates a counterforce to the resistance induced by the capsulotomy margin to the forward passage of the nucleus. The slow controlled delivery of the nucleus through the round capsulotomy can be achieved due to the ample space present in the deep AC. It is very important to remember that deep AC is a result of positive IOP and steady diaphragm. This makes it feasible to deliver the nucleus and not to break the round margin of the

\* Produced by Visitec

capsulotomy during this process. Viscoelastic material alone cannot play this role as the maneuver of the nucleus would tend to collapse the AC (some viscoelastic material would leave the eye) and prevent mostly the delivery of the nucleus to the AC, while with the ACM and BSS you can repeat nucleus delivery to the AC again with success.

The possibility to dissect the lens in situ in the closed eye during manual mini nuc extra cap technique led us to the recognition of a new division of the crystalline lens anatomy consisting of three components:

- a) Cortex, soft material (can be aspirated)
- b) Epinucleus, semi-soft (can be aspirated or expressed)
- c) Hard core nucleus, hard (can be expressed or mechanically broken and expressed)

The following is the way of extracting the nucleus from the eye:

***Hydrodissection:*** Crystalline lens separation to its three components in the closed system starts first with the aspiration by Anis cannula 0.4 mm pore size, of the anterior cortical and epinucleus material exposed after the capsulotomy is completed. The bottom of the formed crater is the anterior part of the hard core nucleus. To separate the crystalline lens to its components, and to facilitate their expression and removal, hydrodissection is performed, using a 1 cc syringe (do not use a 2 or 5 cc syringe as surplus accumulation of BSS in the crystalline lens might break the posterior capsule), and a specially designed cannula, in which the bent part is 4 mm in length and slightly conoidal at its proximal part, with slightly sharp pore edges. It is so designed to penetrate lens material with minimum amount of force and maximum accuracy. The cannula slides along the exposed hard core nucleus, to be inserted obliquely (at 12:00 o'clock) into the junction of the hard core nucleus and epinucleus, 0.1-0.3 cc BSS enforced by injection, engulfs the nucleus instan-

taneously and forms the hydrodissection. The BSS hydrodissection creates a demarcation line, usually clearly seen by the light reflection (golden ring) created between the nucleus and the epinucleus, or between the epinucleus and the cortex.

Hydrodissection, a general term, is commonly used to describe separation of cortical lamella in a non-specific location or between cortex and capsule. Hydrodissection introduced by the author 10 years ago was modified and improved to adjust it to our present technique under a closed system. We find anatomically guided hydrodissection a highly effective surgical technique to separate the lens lamella specifically between the hard core nucleus and the epinucleus, or any place the surgeon chooses. (Thus we call it selective hydrodissection of the lens). This technique enables the surgeon to perform selected hydrodissection in any lamella level he chooses. The continuous controlled ACM flow facilitates separation of the lenticular components during hydrodissection. The positive pressure in the AC using the ACM pushes the posterior capsule backwards and creates a counterforce to the anterior movement of the hard nucleus induced by the cannula from behind the nucleus. This way the smallest possible hard core nucleus is isolated, and is usually small enough to be delivered through the round capsulotomy. ***Bringing the nucleus into the anterior chamber:*** After hydrodissection the hydrodissector cannula is lodged in the newly created space between the epinucleus and the hard core nucleus, then introduced by slight force and small strokes up and down behind the hard nucleus. This part is performed usually at the 12:00 o'clock position where hydrodissection was started. The positive intraocular pressure in the anterior chamber (AC) pushes the posterior capsule and the cortex attached to the posterior capsule backwards and creates a counterforce to the anterior movements of the hydrodissection cannula which is now located behind the hard core nucleus. This maneuver is considered a key to the

success of mobilization of the nucleus before actually bringing the nucleus to the AC. One can use a Sinsky hook to rotate the nucleus. This facilitates the introduction of the hydrodissector cannula behind the nucleus. This way the smallest possible hard core nucleus is isolated and is usually small enough to be delivered through the round capsulotomy, even if some epinucleus is still attached to it, as is commonly seen. This part of the surgery is very important and not too difficult to perform. It is advisable to elevate the BSS bottle to 50-60 cm above the eye, and not to be afraid to push and manipulate the hydrodissector behind the nucleus; due to the hydrodissection this maneuver is not so difficult. Rupture of the posterior capsule by the cannula is quite rare. One has to be sure that the hydrodissection was properly done, using 0.1-0.3 cc of BSS only. Too much quantity might be lodged in the posterior part of the crystalline lens and break the posterior capsule. Without proper hydrodissection the nucleus does not separate from the epinucleus and from the cortex and form one unit. External pressure might on this occasion cause unintentional ICCE result.

#### ***Nucleus evaluation and scleral incision:***

The size of the hard nucleus is evaluated during its presence at this stage in the AC and helps determine the size of the scleral incision needed for that particular nucleus. This is even more true for those who still use limbal incision, as only at this stage do we judge the size of the incision. Thus it might be better to perform limbal incision before the nucleus is in the AC. The size of the nucleus will guide the surgeon as to the size to be performed at the limbus. Up until this stage the AC is closed, a true closed system. The scleral incision should be 1/2 thickness depth, performed 2.5 mm behind the limbus. The shape of the incision is curved slightly backwards. Its apex point is nearest to the limbus. It is recommended to have a symmetrical biconvex dissector knife angled 60°. It is essential to have sharp cutting edges on both sides. The straight diamond knife is not recommended

\* Produced by Visitec

For this procedure, a 60° angled one can do. The diamond knife is excellent but it is very sharp and needs much expertise to work with. Scleral dissection is performed at half thickness in a given amella until reaching clear cornea!

Be careful not to penetrate earlier into the AC, into the angle, otherwise the iris will tend to prolapse and you ask for complications and difficulties you really don't want to happen. A very sharp keratome is used to perforate to the AC, the line of descemet cut is observed through high magnification of the microscope on the anterior surface of the keratome. It is essential to follow the line of descemet while the incision is enlarged right and left, the inner incision should be larger than the outer scleral incision, forming a funnel-shaped scleral tunnel.

A plastic glide 3-4 mm wide, 0.3 mm thick and 1 cm long is introduced through the scleral incision to the AC directed under the nucleus. It is absolutely essential to have the glide, otherwise the nucleus will not be well guided to the incision. A slight external pressure is induced on the glide at the inner limbal area, forcing the nucleus to be engaged in the inner incision of the scleral tunnel-shape tunnel, preventing leakage of BSS through the scleral incision. When the nucleus is well lodged in the inner aspect of the incision, then external scleral pressure is induced moving the pressure gradually away from the limbus. The BSS bottle is located 60-70 cm above the eye, creating 40-50 mm of mercury IOP in the AC. This pressure helps to produce hydro-expression forcing the nucleus out by itself or aided by external pressure.

External pressure at this stage would not cause the AC to collapse as the AC is kept deep by the static pressure of the BSS bottle inflow, producing an internal pressure which is higher than the external induced pressure. During the nucleus passage through the scleral tunnel, it sheds itself from any remnant of epinucleus left attached to it into the AC; thus the smallest possible nucleus is

created, like a newborn baby, the remnants of epinucleus are observed as left over in the AC. The nucleus proper is much smaller than the adult nucleus we used to see while performing planned ECCE, thus the formation of small hard core nucleus led us to call the whole present surgical system a mini nuc(leus) system. The mini nuc manual system enables manipulation of a small nucleus through a 5.0-6.0 mm scleral incision. Thus no stitch is needed to hold the incision closed, if so desired. The end result is a small incision, no stitch, mini nuc technique.

**Handling the epinucleus and cortex:** After the nucleus is extracted the positive IOP creates an inflated capsular bag, facilitating the extraction or aspiration of the epinucleus and cortical material. The epinucleus extraction is performed as follows: -A spatula is introduced into the AC through the scleral incision, manipulating it smoothly right and left, freeing the epinucleus from any attachment to the cortex. The AC might get shallower during the manipulation which is advantageous for the purpose of freeing the epinucleus. The free epinucleus finds its way to the AC and is hydroexpressed out by slight pressure on the posterior lip of the scleral incision. This maneuver might take some time and need determination, as it has to be repeated as long as the epinucleus is still attached to the cortex. In stubborn cases the spatula might be introduced from the side tunnel entrance, penetrate the epinucleus and direct it to the AC. An aspiration cannula with 0.3-0.4 mm pore is introduced at the limbal side opening, not through the scleral incision. Thus the AC stays inflated and does not collapse during aspiration. The scleral incision is a self-sealed incision and does not tend to open during cortical aspiration through the side 1 mm opening. This is a very important advantage as aspiration is performed under controlled condition. This controlled condition is most dramatically appreciated, particularly when one has to handle a complication like posterior capsule tear while the cortex is still in its place. In most cases the vitreous face does not tear si-

multaneously and is pushed backwards by the ACM flow. It is essential to lower the BSS bottle to 10-20 cm above the eye. As only a small cannula is introduced for aspiration, there is no fluctuation of the AC depth during aspiration. A steady fixed depth of AC is a very important fact, it prevents enlargement of the posterior capsule tear, which usually is observed due to fluctuation in AC depth using I/A system, and prevents engagement of the vitreous during aspiration. In most cases one can comfortably finish cortex aspiration in the presence of a torn posterior capsule. If the tear is small, the tear can be converted by the principle of capsulorhexis to a round posterior capsulotomy, facilitating lens implantation, ensuring that it will be implanted in the bag with no vitreous involvement.

In cases when the vitreous presents itself in the AC, the low flow and low pressure in the AC facilitates controlled vitrectomy, again keeping the AC in constant depth, with no fluctuation. Towards the end of vitrectomy a spatula is used to feed the vitrectomy, with vitreous bands attached to the scleral wound.

The side 1 mm. entrance in the limbus enables me to perform this two-handed vitrectomy, exploring the vitreous strands engaged in the scleral incision by pulling them towards the vitrectome by the spatula. Controlled IOP during complicated conditions as such is most appreciated because it produces the most comfortable circumstances for controlled surgery in complications. This is true for any technique. Even in phacoemulsification technique it is advisable first to introduce an ACM and perform a 1 mm. entrance at 11 o'clock, before starting the phacomulsification. Thus one is always ready to confront any complication such as posterior capsule tear, with the best controlled condition to overcome the complication.

**Lens implantation:** Small incision induces new rules for manipulating the IOL into the eye. It is especially true for the scleral tunnel or corneal tunnel currently supposed to be the state of the art. There is a common misunderstanding corre-

lating the optical size of IOL to the scleral incision dimension. It is a commonly accepted fact that the 6 mm optic dimension IOL is the right size to introduce the IOL through 6 mm scleral incision, but this is not necessarily true. The loops base or extension from the optic part add up to 30% of the non-flexible portion of the IOL to be introduced through the scleral incision. That is the reason why a 6 mm IOL hardly can pass through a 6 mm scleral incision. The scleral tissues have viscoelastic properties which allow provisional extension of the scleral incision during forcing the IOL through the scleral tunnel. This fact facilitates IOL implantation under the above conditions, but in designing the new generation of IOLs this fact has to be taken into account. Soft IOLs overcome this problem by indicating a new principle of IOL implantation technique, but still most IOLs are made of PMMA. The only way to overcome the above problem is by designing the IOL: first to reduce the non-flexible loop base extension by a symmetrical design like the Blumenthal lens made by Domilens, or any other design which would consider reducing the extra mass to the optical part. Another important fact in manipulation of IOL into the eye is the following. Using only BSS fluid holding the AC depth steady, it is difficult to manipulate the second loop into the capsular bag by forceps through the scleral incision. It is much more preferable to introduce a lens hook from the 11 o'clock side entrance. This means that at least one hole extended out from the optic part would make this maneuver possible. Another general suggestion is to have in each apex of the lens loop a hole to facilitate loop manipulation in cases where the loop was not successfully introduced into the capsular bag. It is not uncommon to have the lower or upper loop to be found in the AC anterior to the iris. These holes would permit the surgeon (both experienced and inexperienced) to relocate the loop into its position in the bag without much difficulty. This type of lens where both loops have holes in the apex position is not common on the market. Hanita Lenses recently introduced this type of a lens loop. There are other lenses with

holes in the loop but mostly only in one loop. This type of lenses is an excellent desing for scleral fixation lenses where necessary.

**Suturing:** The mini nuc technique allows cataract extraction through a scleral incision 5.0-6.0 mm long, fashioned to need no sutures for closure. It is too early to conclude that the no stitch approach gives the best astigmatic ressults. With the positive IOP mini nuc technique another advantage is demonstrated during the act of suturing. The IOP is chosen to be 10 mmHg. This pressure provides the best condition for adaptation of the scleral wound lips of the scleral tunnel. Small bite sutures promise best adaptation, and probably best overall astigmatic results. No stitch with 6.0 mm scleral incision tends to move slightly against the roll in 3 months, but edge to edge adaptation with no overlapping prevenst the tendency of against the roll astigmatism in 3 months. The wound is tested for leakage by increasing the IOP (by raising the BSS bottle), another advantage of this technique.

A metal anterior chamber maintainer is currently available and now a new model is coming up made of plastic, which is easy to use. There is also a specific needle for capsulorherix which is bent 90°, and then another 90° on its axis. This needle makes capsulorherix simple to perform. A specific conoidal cannula is used for hydrodissection and a stiletto knife is used to perform the mini-tunnel for the ACM fixation. A 500 cc bottle is used for eight cases usually. Controlled surgery depends on a condition where any surgical maneuver will not disturb the basic normal internal anatomical relationship in the eye. The best way to achieve con-

trolled surgery is by continuously irrigating the eye and simultaneously controlling the intraocular pressure. Thus during my surgical maneuver the amount of fluid lost is instantly recovered. The use of viscoelastic material can achieve controlled surgery only at specific stages of the surgery but not at all stages, while the anterior chamber maintaining system with ACM provides the precondition for controlled surgery throughout all the time needed to complete cataract surgery.

Under positive IOP the BSS in the eye, with very low turbulence and steady flow rate, creates the best millieu to the point where the anatomical relationship in the eye is intact and offers the precondition for controlled surgery. Only 30-40 cc of BSS is used in this mini nuc technique. During phaco, even with a low flow technique, the amount of BSS used during the operation is from 10 to 20 times greater than that used in the mini nuc technique. The other advantage of the mini nuc technique is the freedom from the necessity to use viscoelastic material, as a steady flow of BSS ensures a constant depth of the anterior chamber.

In summary, the mini nuc technique is cost effective, the surgical time is very short. It is the most inexpensive procedure known today for cataract surgery. The learning curve is not too long. Getting used to the technique enables you to reduce surgical and post-operative complications to a minimum. No expensive sophisticated instruments are needed. One feels comfortable with this technique in any part of the world, in the affluent countries or in countries which cannot afford sophisticated instruments. With the leasst instrumentation, one has in hand a system with shich you can achieve surgery as good as anywhere in the world.

# Estudio prospectivo del uso de heparina intraocular en cirugía vitreorretiniana con aceite de silicona(\*)

Gustavo Alvira Escovar, MD (\*\*)  
Camilo Jaramillo Villamizar, MD  
Fernando Arévalo Colina, MD  
Vilma María Mesa, Ing.

---

## Resumen

---

Los autores reportan los resultados de un estudio prospectivo sobre el uso de la heparina intraocular como agente antiproliferante en casos de proliferación vitreo-retiniana (PVR), intervenidos quirúrgicamente mediante vitrectomía pars-plana e inyección de aceite de silicona en 51 ojos de 51 pacientes tratados en la Fundación Oftalmológica Nacional entre 1990 a 1992. Se realiza una comparación entre el grupo de heparina y un grupo control en cuanto a la agudeza visual, seguimiento, reintervenciones, intervalo entre cirugías, éxito anatómico y complicaciones. No encontrando una diferencia estadísticamente significativa entre ambos grupos.

---

---

## Introducción

---

Los resultados quirúrgicos en las enfermedades proliferativas de la retina aún en la actualidad y con las técnicas quirúrgicas más sofisticadas, dejan mucho que desear, pues si bien en un porcentaje considerable de casos logramos un resultado anatómico final aceptable, los resultados funcio-

nales en general son muy diferentes (1). Aunque el mecanismo fisiopatogénico exacto de la formación de las membranas en el PVR es desconocido, es aceptado por lo menos que intervienen distintos elementos como son: células de diversos orígenes, además de sustancias presentes en el espacio extracelular (2, 3, 4). Las células que generalmente se identifican en las membranas son:

1. Fibroblastos, que provienen de diferentes orígenes, como son células del epitelio pigmentario retiniano (EPR), fibrocitos y células gliales de la retina. 2. Fagocitos mononucleares, que pueden

(\*) Presentado durante el XXV Forum Oftalmológico del Instituto Barraquer de América. Bogotá, Colombia.

(\*\*) Correspondencia y reprints dirigirse al Dr. Gustavo Alvira Escovar a la Fundación Oftalmológica Nacional. Calle 50 # 13-30. Bogotá, Colombia.



derivarse de la sangre periférica, del EPR, microglía de otros fagocitos locales que no han sido terminados hasta el momento.

Los elementos del espacio extracelular implicados en el proceso, son:

1. La fibronectina y últimamente la vitronectina, proteína S, spreading factor, epibolin, conocidas como proteínas de tipo adhesivo, que tienen dentro de su secuencia de aminoácidos la tríada arg-gli-p, o área de especificidad celular. Estas proteínas interactúan con receptores específicos de la superficie celular, conocidos como citoadhesivos "integrins" (5).

Además se encuentra colágeno tipo III, como el llamado en el vítreo, o de tipo I y III producidos en proceso inflamatorio por las mismas células que intervienen en el proceso. También se han implicado algunos factores de crecimiento como: Factor B de Crecimiento Transformador (TGF- $\beta$ ) y el Factor de Crecimiento Derivado de plaquetas; así como la transferrina, factor de crecimiento esencial en las células cultivadas (6). Basados en los conocimientos anteriores, vemos que con la cirugía estamos enfrentando mecánicamente un proceso puramente biológico, como es la re proliferación. Este hecho ha llevado a muchos investigadores a buscar farmacológicamente nuevas posibilidades terapéuticas.

Fueron tal vez los esteroides la droga que se usó en un primer intento para inhibir la proliferación intraocular. El mecanismo probable de acción es disminuir la proliferación de la membrana celular, por inhibición de la formación de ácido araquidónico-precursor en la formación de leucocenos y prostaglandinas, que son mediadores del proceso inflamatorio. Tano y Machemer, en 1980, intentan la inhibición de la proliferación intraocular con la triamcinolona (8). En los últimos años, utilizando un modelo experimental diferente de PR en el cual el vítreo es comprimido y parcialmente desprendido-previa inyección intraocular

de fibroblastos heterólogos-el efecto de la triamcinolona fue nuevamente evaluado (9). Se encontró que a dosis 2 mg, se reducía la incidencia del desprendimiento de retina de 90% a 56%; este resultado, aunque significativo, no es tan prometedor al encontrado en la primera publicación. Más recientemente, Chandler no sólo aplicó el esteroide al momento de la inyección de las células sino 24 horas antes, logrando un mejor efecto; de lo que se concluye que la reducción de la re proliferación se alcanza parcialmente a través de un efecto directo sobre la inhibición de la mitosis, así como actuando a nivel de la reducción del proceso inflamatorio reactivo (10).

Si bien son muchas las drogas o sustancias que se han investigado con el ánimo de disminuir o abolir la proliferación, son sin duda los avances en el conocimiento de la fisiopatología del PVR lo que nos ha permitido explorar nuevas posibilidades terapéuticas. La fibronectina (11, 12) es una glucoproteína de alto peso molecular que ha sido llamada proteína "ancla", pues tiene en su estructura distintas áreas de especificidad, o "zonas de unión", entre otros, para el colágeno, la célula, DNA, actina y heparina.

La heparina es un grupo heterogéneo de mucopolisacáridos aniónicos de cadena recta cuyo peso molecular es de 15.000 daltons, conocidos también como glicosaminoglicanos (13); el sulfato de heparán producido en el hepatocito es un componente "ubicuo" de la superficie celular en los mamíferos. Fuera de la actividad antifibrinolítica y antiinflamatoria, características bien conocidas de la heparina, se sabe desde hace varios años que la fibronectina (14, 15) tiene un área de especificidad o zona de unión para la heparina en su molécula. Esta área específica tiene además una gran similitud bioquímica con la zona de unión para la célula y el colágeno. Se piensa, por lo tanto, que al aumentar la concentración de heparina en el espacio extracelular, competiría por las "zonas de unión" tanto de la célula como del colágeno a nivel de la molécula de fibronectina, impidiendo así la formación de la membrana.

La heparina se estudió primero a nivel de la polimerización del colágeno, lo cual se determinó espectrofotométricamente, midiendo los cambios en la turbiedad del mismo. Cantidades crecientes de heparina disminuyeron significativamente la polimerización del colágeno o su turbidez. La adición de 10 unidades USP aminoran la turbiedad en un 43.7% y cuando la concentración alcanza 50 unidades USP, ésta se reduce en un 75.35% (16).

El efecto de la heparina sobre la concentración del colágeno mediada por células se investigó utilizando el modelo experimental de Van Bockxmeer (17); se encontró que cantidades crecientes de heparina disminuyen la contracción del gel. En el análisis estadístico se observó una relación sigmoidea a la cual al aplicársele una transformación logística la regresión era estadísticamente significativa a niveles de  $P < .001$ . La heparina fue igualmente evaluada a nivel animal, en donde utilizando el modelo experimental descrito por Ophir (18) se observó que en los ojos tratados con heparina la incidencia del desprendimiento de retina de dos o más cuadrantes, era solamente del 25%, luego de 21 días de observación y, no se encontró toxicidad sobre la retina o sangrado.

Basados en estos datos experimentales, desde hace dos años se ha llevado a cabo un estudio prospectivo sobre el uso de heparina intraocular en pacientes con diferentes patologías, grupos de edad y PVR. En el momento el estudio no tiene el número suficiente de pacientes en los diferentes grupos para que el resultado sea estadísticamente significativo. Sin embargo, basado en nuestra experiencia hemos observado que no existen cambios que sugieran una diferencia evidente con los pacientes en los cuales no se ha usado la heparina. Por lo tanto hemos analizado nuestros resultados hasta la fecha, comparando el grupo de pacientes tratados contra un grupo control; seleccionando pacientes con diagnósticos preoperatorios

similares a los tratados con la droga; esto es, excluyendo patologías diferentes a traumas y PVRs para confirmar nuestra impresión clínica.

El objetivo de este trabajo es el de reportar el análisis de los resultados de los casos intervenidos por nosotros con el uso de heparina intraocular como agente antiproliferativo en cirugía vitreorretiniana y en la que se usó aceite de silicona como taponante interno.

---

## Material y métodos

---

Se revisaron las historias clínicas de 51 pacientes, 37 (72.5%) del sexo masculino y 14 (27.5%) del femenino, con un rango de edad entre 9 y 78 años y una media de 37.3 años. En éstos y en forma prospectiva se utilizó heparina intraocular como agente antiproliferativo, junto con el aceite de silicona en el manejo de los casos complicados de patología vitreorretiniana intervenidos en la Fundación Oftalmológica Nacional.

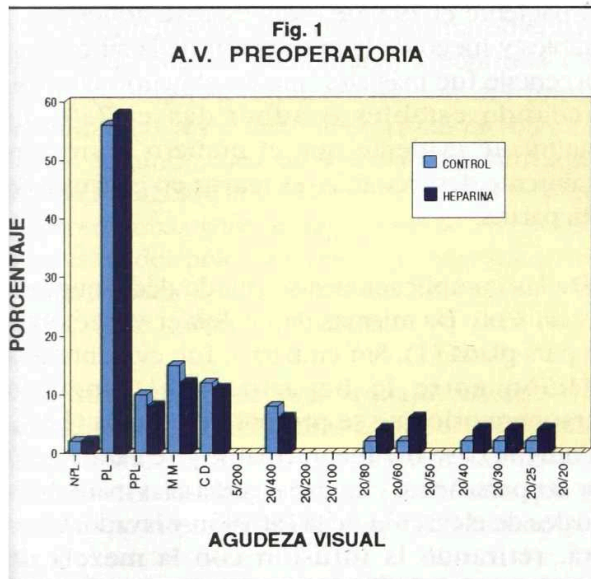
Como grupo control se seleccionaron los ojos intervenidos por los mismos cirujanos (G.A.E. y C.J.V.), con igual técnica, similares diagnósticos preoperatorios y posibles etiologías, encontrándose que 337 ojos cumplían estos requisitos. La técnica quirúrgica en los dos grupos es idéntica, exceptuando los casos tratados con heparina en los cuales mezclábamos ésta con el líquido de la infusión a concentración de 10 USP o unidades internacionales por mililitro, se llevaba a cabo el procedimiento con la mezcla definida durante un período máximo de 30 minutos, luego de lo cual se reconectaba la infusión sin la mezcla y la cirugía seguía su curso normal.

Se analizaron parámetros como la agudeza visual pre y postoperatoria, seguimiento, reintervenciones, intervalo entre las cirugías, éxito anatómico y complicaciones.

## Resultados

En los resultados observamos que los dos grupos son comparables en cuanto a su población en todos los parámetros analizados. En la gráfica se observa que en lo referente a las AV preoperatorias en los controles se parte de mejores visiones iniciales, pero esto no fue significativo. Tampoco se encontraron diferencias en tensiones oculares, ni como ya se explicó, en los diagnósticos preoperatorios (Fig. 1).

Antes de continuar con el análisis, observamos en la (Tabla 1) cómo ha sido el seguimiento de estos pacientes. Un gran porcentaje de los enfermos no regresan a control. El seguimiento de los pacientes fue muy similar en promedio, siendo mayor el rango en los controles, como es de suponer. El promedio en los tratados es de 15.9 semanas y el rango de 1 a 119 semanas. Referente a las reoperaciones, se encontró que se intervinieron el 29% de los casos tratados con heparina y el 34.1% de los controles. El número de



primeras reoperaciones es casi igual en ambos grupos; pero de allí en adelante en los tratados el porcentaje es menor, así como el número de

(Tabla 1)

PROMEDIO DE SEGUIMIENTO		
	CONTROL	HEPARINA
Mínimo:	1 sem.	1 sem.
Máximo:	295 sem.	119 sem.
Promedio:	18.6 sem.	15.9 sem.

reoperaciones necesarias por paciente, aunque los resultados no son estadísticamente significativos. El tiempo entre cirugías fue igualmente motivo de estudio. Los intervalos en el grupo control mostraron que el mínimo entre la primera y la segunda cirugía fue de 1.8 semanas, el máximo de 184, la media 31.9 y la desviación estandar de 27.5 semanas para un total de 78 cirugías. Se escogió 1.96, pues en el análisis se buscaba el 95% de confiabilidad en los resultados (Tabla 2). En el grupo tratado con heparina el intervalo entre la primera cirugía y la primera reoperación es mayor, siendo el mínimo de 3.7 semanas y el máximo de 72; la media es menor en el grupo de ojos tratados.

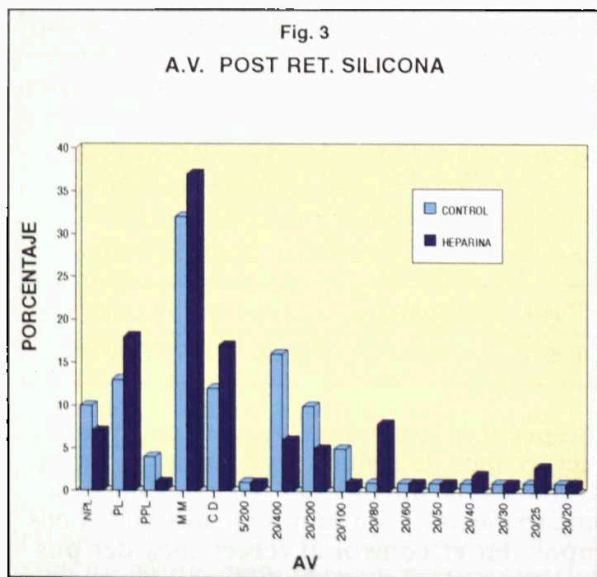
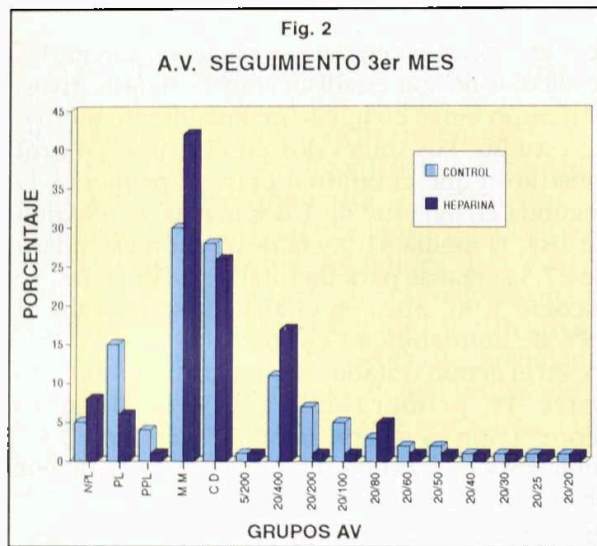
(Tabla 2)

REOPERACIONES	
CONTROL	HEPARINA
1 = 78 (23.1%)	1 = 12 (23.5%)
2 = 25 (7.4%)	2 = 2 (3.9%)
3 = 7 (2.07%)	3 = 1 (1.9%)
4 = 3 (0.89%)	
5 = 2 (0.5%)	
<b>Total: 115 (34.1%)</b>	<b>Total: 15 (29.4%)</b>
<b>T: EX. A. SIL: 142(30.8%)</b>	<b>T: EX. A. SIL.: 16 (31.3%)</b>

Respecto de las agudezas visuales, tenemos que al tercer mes de seguimiento, luego de la extracción de la silicona del interior ocular, los comportamientos son muy similares en los dos grupos. En el control al tercer mes del postoperatorio el número de NPL es ligeramente



mayor en los ojos tratados con heparina, pero luego de la extracción de la silicona son menores. Igualmente se debe recordar que los controles partieron de mejores visiones iniciales ( Figs. 2 y 3). El resultado anatómico postoperatorio de la retina se encuentra analizado en las (Tablas 3 y 4). En el grupo control se aprecia que en el último examen de estos pacientes, el 80.6% se hallaba con la retina adherida o anatómicamente estable y que



(Tabla 3)  
**ESTADO ANATOMICO POSOPERATORIO DE LA RETINA**

CONTROL	DRT	DRST CM	DRST SM	RET. AD
A. Ultimo Cont.	5.9%	4.8%	13.6%	67%
B. Post. Retiro A. Silicona	7%	12%	4%	63%
<b>Fondo No Visible: A: 8%, B: 12%</b>				

(Tabla 4)  
**ESTADO ANATOMICO POSOPERATORIO DE LA RETINA**

HEPARINA	DRT	DRST CM	DRST SM	RET. AD
A. Ultimo Cont.	4%	10.1%	18.4%	61%
B. Post. Retiro A. Silicona	18%	0%	6.2%	68.7%
<b>Fondo No Visible: A: 6.2%, B: 7%</b>				

luego de la extracción de la silicona el porcentaje se reduce al 67%. Por otra parte, en cuanto a los ojos tratados con heparina, en el último control del paciente el 79% de éstas estaban adheridas o estables y luego de la extracción de la silicona el porcentaje fue más alto que en el grupo control, quedando estables o adheridas el 74%. Es igualmente evidente que el número de retinas totalmente desprendidas es mayor en el grupo de la heparina.

De las complicaciones se puede decir que son básicamente las mismas de cualquier vitrectomía vía pars-plana (1). Sin embargo, fue evidente una relación entre la heparina y el sangrado intraoperatorio que se presentó en 6 ojos (12%). En ningún caso fue incontrolable y se caracterizó por ser persistente y en capa, cedía a las maniobras usuales de elevación de la infusión y lavado, claro está, retirando la infusión con la mezcla de heparina lo antes posible. Es importante en este punto resaltar que las hemorragias se presentaron siempre que se perfundió el ojo por más de 30 minutos con solución heparinizada.

## Conclusiones

Se ha presentado nuestra experiencia con el uso de la heparina en el manejo de casos complicados de cirugía vitreoretiniana en un intento de controlar farmacológicamente la proliferación vitreoretiniana postoperatoria.

Basados en los resultados iniciales de laboratorio, se diseñó un estudio por medio del cual se pretendía comprobar los hallazgos experimentales. Se realizó un estudio piloto en 12 ojos en el cual los resultados fueron alentadores, pues se usó únicamente en casos en los cuales, a criterio del cirujano, el pronóstico era reservado y se halló que por lo menos se comportaban durante el seguimiento de manera similar a otros con relativo mejor pronóstico. En el transcurso del estudio, sin embargo, se encontraron algunas diferencias y éstas se evidenciaban principalmente durante los primeros días del postoperatorio; pero con el tiempo los ojos se comportaban igual. Dichas diferencias fueron difíciles de evaluar en forma objetiva y algunas de ellas se comentarán a continuación: primero, una diferente coloración del fondo, atribuible tal vez a una mejor visualización de la retina. Segundo, una menor reacción fibrinolítica debido a la acción anti-fibrinolítica de la heparina. Y, tercero, una pronta desaparición de los pliegues residuales del polo posterior. Sin embargo, esta misma situación se observa en los casos en los cuales no se utiliza la heparina.

La conclusión de este trabajo, como ya se mencionó en los resultados, es que si bien los dos grupos son distintos, las diferencias no son significativas estadísticamente. Resultado que en realidad no nos sorprende por varias razones:

1. A medida que aumentan los conocimientos sobre la fisiopatología del PVR se ha determinado que su origen es probablemente multifactorial y podría ser que la fase que se está contrarrestando

con la heparina no sea la determinante para detener el proceso.

2. El tiempo de depuración de la heparina en el globo ocular no se ha determinado, por lo tanto es igualmente probable que el tiempo en el cual se encuentra la droga en contacto con las estructuras oculares no sea suficiente para contrarrestar definitivamente la enfermedad.

3. Relacionado con lo anterior, tenemos que la vía de administración de la heparina al interior ocular, igualmente estaría por determinarse, pues podrían ser más efectivos elementos colocados en el interior ocular que la contengan y libere de manera lenta y sostenida a la dosis necesaria, por el tiempo adecuado.

4. ¿Tendrá la enfermedad distintas fases dentro de su proceso fisiopatológico en algunas de las cuales sea más efectiva la heparina?

5. La heparina en sí, puede ser igualmente susceptible de variación, pues no es una sola, sino un grupo de sustancias con características similares. La heparina humana es sensiblemente diferente a la comercialmente disponible; la primera tiene un mayor peso molecular y escasamente un 30% de la capacidad anticoagulante de la comercial, así que es muy probable que el heparan sulfato como se conoce a la heparina humana-cumpliera una labor antiproliferante y fibrinolítica más efectiva.

La investigación en este campo debe continuar. Si bien creemos que la cirugía vítrea junto con los nuevos conocimientos en todas las áreas se dirigen al tratamiento y manejo de estos difíciles casos, pensamos que la profilaxis en medicina es mejor que cualquier tipo de tratamiento y es así como se decidió intentar la prevención de casos severos de proliferación vitreoretiniana. En el momento estamos llevando a cabo un estudio piloto, el cual se inició hace 18 meses, y hasta el momento se han tratado 31 ojos de manera profiláctica con

heparina. Se han escogido los casos que en concepto del cirujano presentan ya algún grado de PVR, o que por sus características clínicas suponen una mayor probabilidad de desarrollar estadios más severos de PVR en el postoperatorio. La técnica quirúrgica de la retinopexia convencional no varía y, ya ha sido presentada por nosotros (19). Se utiliza una solución heparinizada para restituir el tono ocular, luego del drenaje del líquido subretiniano en cambio de aire o de la solución intraocular. La mezcla se prepara a una concentración de 50 USP por ml, la cual se inyecta con aguja fina a través de la pars-plana a 3 ó 3.5 mm del limbo esclero-corneano. Hasta el momento

hay un seguimiento promedio de 20 semanas y, como ya se mencionó, 31 ojos tratados. Los resultados son muy alentadores, pues si bien se han escogido aquellos casos que en concepto del cirujano presentaban un mayor riesgo, el número de ojos que han desarrollado PVR es de 2, lo que equivale a un 6.5%, cifra muy diferente a la reportada por nosotros en 1991, que fue del 28% de reoperaciones por el PVR para este mismo grupo (19).

Continuaremos nuestro estudio, hasta alcanzar el tiempo de seguimiento y números de casos requeridos estadísticamente para entonces comunicarlos.

---

### Summary

---

The authors communicate the results of a prospective study about the intraocular use of heparin as antiproliferative agent in vitreoretinal surgery and silicone oil perform in 51 patients at Fundación Oftalmológica Nacional of Bogotá, Colombia, from 1990 to 1992. A comparison was made between the heparin group and the control group taking the following parameters: visual acuity, follow up, reinterventions, period of time between surgeries, anatomic success and complications. No statistical difference was found among both groups of patients.

---

---

### Bibliografía

---

1. Alvira, G.; Jaramillo, C.; Arévalo, F.; Mesa, V.: Estudio retrospectivo de ojos intervenidos con aceite de silicona en casos complicados de patología vitreoretiniana. Presentado durante el XIV Curso Anual de la Fundación Oftalmológica Nacional. Bogotá, Colombia, 4-6 de febrero de 1993.

2. Clarkson, J.G.; Green W.R.; Massof, D.A.: Histopathologic review of 168 cases of preretinal membrane. *Am. J. Ophthalmol.* 84: 1-17, 1977.

3. Green W.R.; Kenyon, K.R.; Michels, R.G.; Gilbert, H.D.; De la Cruz, Z.: Ultrastructure of epiretinal causing macular pucker after retinal reattachment surgery. *Trans Ophthalmol.* 99: 63-77, 1979.

4. Hiscott, P.S.; Grierson, I.; McLeod, D.: Retinal Pigment Epithelial Cells in Epiretinal Membranes: An Immunohistochemical Study. *Br. J. Ophthalmol.* 68: 708-715, 1984.

5. Hynes, R.O.; Yamada, K.M.: Fibronectins: Multifunctional modular glycoproteins. *J. Cell Biol.* 369 - 377, 1982.

6. Glaser, B.M.; Cardin, A.; Biscoe, B.: Proliferative Vitreoretinopathy: The mechanism of development of vitreoretinal traction. *Ophthalmology* 94: 327 - 332, 1989.

7. Glaser, B.M.; Lemor, M.: Pathobiology of proliferative vitreoretinopathy. In *Rysan's retina*, Vol. 3, The C.V. Mosby Company, St. Louis, Missouri, 1989.



8. Tano, Y.; Chandler, D.; Mc Cuen, B.W.: Glucocorticosteroid inhibition of intraocular proliferation after injury. *Am. J. Ophthalmol.* 91: 184 -189, 1981.

9. Radtke, N.D.; Tano, Y.; Chandler, D.; Machemer, R.: Simulation of massive periretinal proliferation by autotransplantation of retinal pigment epithelial cells in rabbits. *Am. J. Ophthalmol.* 91: 76, 1981.

10. Chandler, D.B.; Rozakis, G.; De Juan, E.; Machemer, R.: The effect of triamcinolone acetamide on a refined experimental model of proliferative vitreoretinopathy. *Am. J. Ophthalmol.* 99: 686-690, 1985.

11. Klebe, R.J.; Mock, P.J.: Effect of Glycosaminoglycans on Fibronectin mediated cell attachment. *J. Cell Biol.* 112: 5-9, 1982.

12. Akiyama, S.K.; Yamada, K.M.; Hayashi, M.: The structure of fibronectin and its role in cellular adhesion. *J. Supra Struc Biochem.* 16: 345-358, 1981.

13. Heparin, in Goodman and Gilman (EDTS), *The Pharmacological Basis of Therapeutics*, Seventh Edition, 1985. F. 1348-1352.

14. Pande, H.; Shirley, J.E.: NH<sub>2</sub> - Terminal sequences of DNA, Heparin and Gelation binding tryptic fragments

from Human Plasma Fibronectin. *Arch Biochem and Biophys.* 213 : 258 -265, 1982.

15. Stamatoglov, S.C.; Keller, J.M.: Correlation between cell substrate attachment in vitro and cell Surface Heparan Sulfate Affinity for Fibronectin and Collagen. *J. Cell Biol.* 96 (6): 1820-1823, 1983.

16. Alvira, G.; et al.: Heparin, a possible new approach to the treatment of proliferative vitreoretinopathy. In *Proliferative Vitreoretinopathy*. Ed. Heiman, K.; Weidemann, P. Kaden-Verlag. 268-271, 1989.

17. Van Bockxmeer, F.M.; Martin, C.E Measurement of cell proliferation and cell mediated contraction in 3-Dimensional Hydrated Collagen Matrices. *J. Tissue Culture Methods* 7: 163-167, 1982.

18. Ophir, A.; Blumenkranz, M.; Clafin, A.J.: Experimental intraocular proliferation and neovascularization. *Am. J. Ophthalmol.* 94: 450-457; 1982.

19. Alvira, G.; Jaramillo C.; Mendoza, S.: Desprendimiento regmatógeno de la retina. Cirugía convencional. Presentado durante el XII Curso anual de la Fundación Oftalmológica Nacional. Bogotá, Colombia, febrero 28 a marzo 2 de 1991.

# Cirugía convencional de desprendimiento de retina: Complicaciones

Ricardo Infante de Germán Ribón, MD  
J. Fernando Arévalo, MD

## Resumen

Los autores comunican los resultados y complicaciones de la cirugía convencional de desprendimiento de retina regmatógeno realizada en 177 ojos de 167 pacientes en la Fundación Oftalmológica Nacional de Bogotá, Colombia, desde 1985 a 1992. Encontramos que las complicaciones se presentaron en el 59.6% de las cirugías, pero no fueron obstáculo para el éxito anatómico de la cirugía en casi el 90% de los casos, las complicaciones ocurren con mayor frecuencia durante las primeras 6 semanas postoperatorias e incluyen el desprendimiento de retina residual y la hipertensión ocular.

## Introducción

Las complicaciones de la cirugía convencional de desprendimiento de retina son múltiples y potencialmente pueden hacer que la cirugía sea técnicamente más difícil y asimismo disminuir el éxito anatómico y funcional de nuestros casos.

Sin embargo, la mayoría de ellas no son lo suficientemente serias como para ser responsables de la falla en la reapiación de la retina que ocurre entre el 9% - 25% de los casos, según las series (1, 2, 3). Las complicaciones de este tipo de cirugía

han sido clasificadas en intraoperatorias, postoperatorias, tempranas y postoperatorias tardías, considerándose una complicación temprana a aquella que se presenta durante las primeras 6 semanas postoperatorias y tardía la de aparición posterior (4).

Entre las complicaciones descritas podemos mencionar:

### A) Intraoperatorias:

- Ruptura Retiniana
- Incarceración retiniana
- Incarceración vítrea
- Hemorragia retiniana
- Hemorragia vítrea
- Salida de vítreo
- Sutura perforante

\* Fundación Oftalmológica Nacional, Bogotá, Colombia.

\* Presentado durante el forum in XXV Aniversario de la Clinica Barraquer, Bogotá, Colombia, marzo 21-26, 1993

\* Correspondencia dirigirse al Dr. Ricardo Infante de German Ribón, Fundación Oftalmológica Nacional, Calle 50 No. 13-30, Santafé de Bogotá, Colombia.

- Desprendimiento coroideo
- Daño a vena vorticosa
- Avulsión de músculo extraocular.

#### B) Postoperatorias:

- Desprendimiento coroideo
- Endoftalmitis
- Infección del exoplante
- Extrusión del exoplante
- Intrusión del exoimplante
- Aumento de tensión intraocular (TIO)
- Proliferación Vitreorretiniana (PVR)
- Pucker macular
- Diplopía
- Simblefaron
- Error refractivo
- Dispersión del pigmento
- Edema macular cistoide
- Desprendimiento de retina (DR) residual y recidivante
- Desplazamiento del exoplante por dehiscencia de sutura.

Es entonces el objetivo de este trabajo realizar un análisis retrospectivo de las complicaciones de la cirugía convencional de desprendimiento de retina regmatógeno de los últimos 8 años y determinar cómo éstas afectan la tasa de éxito anatómico y funcional de nuestra técnica.

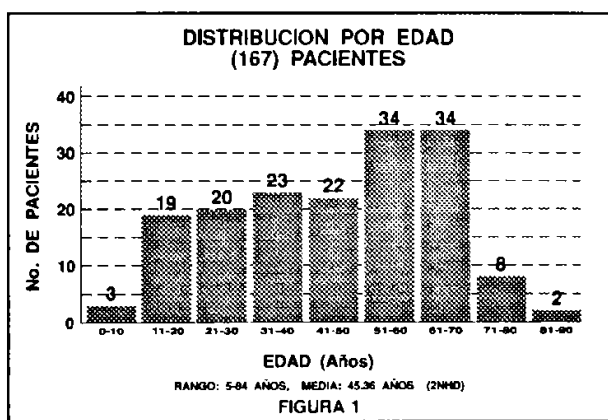
### Material y métodos

Se revisaron en forma retrospectiva las historias clínicas de 227 pacientes a los cuales se les realizó cirugía convencional de desprendimiento de retina regmatógeno desde enero de 1985 a diciembre de 1992 en la Fundación Oftalmológica Nacional de Bogotá, Colombia, y en la consulta privada de uno de los autores (RI):

Se excluyeron del estudio aquellos pacientes cuyas historias clínicas no llenaron los

requerimientos exigidos por nuestro protocolo y quedaron 177 ojos de 167 pacientes.

Asimismo, se incluyeron en nuestra estadística 14 reintervenciones (cirugía convencional) para un total de 191 cirugías realizadas. De esta casuística de 167 pacientes, el sexo predominante fue el masculino, con 115 pacientes, para un 68.8%, con una edad entre 5 y 84 años, y una media de 45.3 años (Fig. 1).



No encontramos diferencia en cuanto a la frecuencia de compromiso del ojo derecho o izquierdo y la incidencia de casos bilaterales fue del 5.6% (10 pacientes).

Por otra parte, 25 casos, para un 14.1%, tenían cirugía convencional de desprendimiento de retina previamente, en otra institución, con una media de 1.4 cirugías por ojo. Todos los casos fueron operados y seguidos por uno de los autores (RI) y la técnica quirúrgica empleada fue la siguiente:

- 1). Peritomía conjuntival en 360°.
- 2). Reparación de los 4 músculos con seda -0.
- 3). Localización del desgarro o ruptura retiniana por oftalmoscopia binocular indirecta.
- 4). Criocoagulación de los bordes de la ruptura retiniana.

- 5). Fijación de suturas de mersilene o dacrón 5-0, una por cuadrante, de acuerdo con la localización y tamaños de las rupturas retinianas, teniendo como referencia el patrón 1/3 anterior y 2/3 posteriores en relación con el borde posterior de la ruptura.
- 6). Fijación de esponja de silicón.
- 7). Drenaje del líquido subretiniano, previa decisión del sitio de drenaje.
- 8). Adición de elementos meridionales según el caso.
- 9). Afrontamiento de los extremos de la esponja distante de las rupturas y sitio de drenaje del líquido subretiniano.
- 10). Cierre de la peritomía conjuntival.
- 11). Inyección subconjuntival de esteroides y antibióticos. (Dexametasona y gentamicina).

Analizamos parámetros como la agudeza visual preoperatoria y postoperatoria, la tensión intraocular preoperatoria y postoperatoria, tiempo de evolución del desprendimiento, antecedentes, tipo y localización de las rupturas retinianas, hallazgos asociados, estado de la mácula, complicaciones intraoperatorias y postoperatorias (tempranas y tardías), seguimiento, éxito funcional y anatómico.

## Resultados


El desprendimiento de retina tuvo un tiempo de evolución al momento de la primera consulta de entre 1 día a 5 años, con una media de 4.5 meses.

Los antecedentes positivos más frecuentemente encontrados fueron: miopía (media: -7.7 D) con 44 ojos para un 24.8%, trauma y afaquia con 29 ojos cada uno, para un 16.3%; cirugía convencional previa en 25 ojos, para un 14.1%; pseudofaquia en 13 ojos, para un 7.3%, y una historia familiar de desprendimiento de retina en 7 pacientes para un 3.9% (Tabla 1).

El seguimiento de los 177 ojos operados estuvo entre 1 mes y 89 meses, con una media de 12.4 meses (Tabla 2).

La valoración preoperatoria de los casos nos muestra un promedio de 1.5 rupturas retinianas por caso, siendo las más frecuentes el desgarro retiniano en 119 ojos, para un 67.2%; diálisis retiniana en 33 ojos, para un 18.6%; agujeros retinianos en 19 ojos, para un 10.7%, y no se visualizó la ruptura en 6 ojos, para un 3.3%.

Por otra parte, la localización más frecuente de las diálisis retinianas fue en el cuadrante inferotemporal en el 91.4% de los casos, mientras la localización más frecuente de los agujeros y de los desgarros retinianos fue en los cuadrantes superiores en el 65.0% de los casos (Figura 2). La mácula estaba desprendida en 135 casos, es decir, en el 76.2%.



Los hallazgos asociados más frecuentes fueron: proliferación vitreoretiniana en 27 ojos, para un 15.2%; hemorragia vítrea en 6 ojos, para un 3.3%; degeneración lattice múltiple en 4 ojos, para un 2.2%; agujero macular en 3 ojos, para un 1.6%, y granuloma inflamatorio en 3 ojos, para un 1.6% (Tabla 3).

La agudeza visual preoperatoria fue de cuenta dedos o peor en el 67.2% de los casos, mientras que la agudeza visual postoperatoria fue de 20/200

TABLA 1

<b>ANTECEDENTES (177 OJOS)</b>		
	<b>No. OJOS</b>	<b>%</b>
NEGATIVOS	47	26.5%
MIOPIA (RANGO: -1 a -28 d, MEDIA: -7.7 D)	44	24.8%
TRAUMA	29	16.3%
AFAQUIA	29	16.3%
RETINOPEXIA	25	14.1%
PSEUDOFAQUIA	13	7.3%
A. FAMILIAR/ D.R.	7	3.9%
GLAUCOMA TX	3	1.6%
H VITREA	3	1.6%
GLAUCOMA DE ANGULO ABIERTO	2	1.1%
Sd. DE MARFAN	2	1.1%
DMNID	2	1.1%
VITRECTOMIA	2	1.1%
HTA	2	1.1%
IRIDOCICLITIS	2	1.1%
TOXOPLASMOSIS OCULAR	1	0.5%
TRABECULECTOMIA	1	0.5%
INFECCION DE EXOPLANTE	1	0.5%
RETIRO DE EXOPLANTE	1	0.5%
EXTRUSION DE EXOPLANTE	1	0.5%
LASER ARGON	1	0.5%
YAG LASER	1	0.5%
CRIOPEXIA	1	0.5%
ECEIO	1	0.5%
OVR	1	0.5%
QPP	1	0.5%
GRANULOMA	1	0.5%

A. familiar /D.R. = Antecedente familiar de desprendimiento de retina;  
D. = dioptría; TX = traumático, H. vítrea = hemorragia vítrea, SD. = síndrome,  
DMNID = Diabetes mellitus no insulino dependiente, HTA = Hipertensión arterial,  
ACEIO = Extracción de cuerpo extraño intraocular,  
OVR = Oclusión venosa de RAMA, QPP = Queratoplastia penetrante.

TABLA 2

<b>SEGUIMIENTO POSTOPERATORIO (177 OJOS)</b>		
RANGO: 1 - 89 MESES MEDIA: 12.4 MESES		
	<b>No. OJOS</b>	<b>%</b>
1 - < 3 MESES	57	32.2%
3 - 6 MESES	45	25.4%
> 6 MESES	75	42.3%

TABLA 3

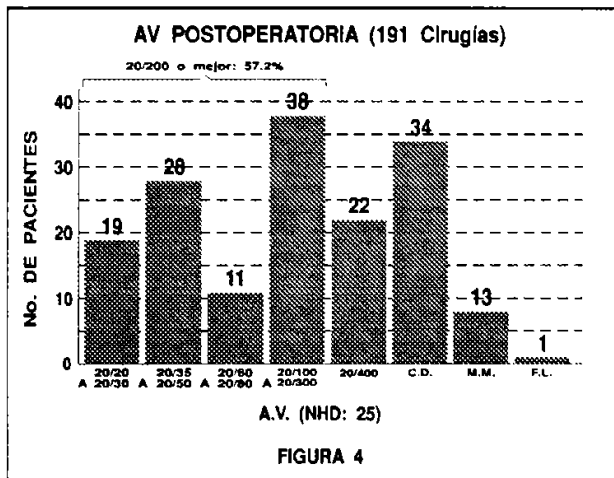
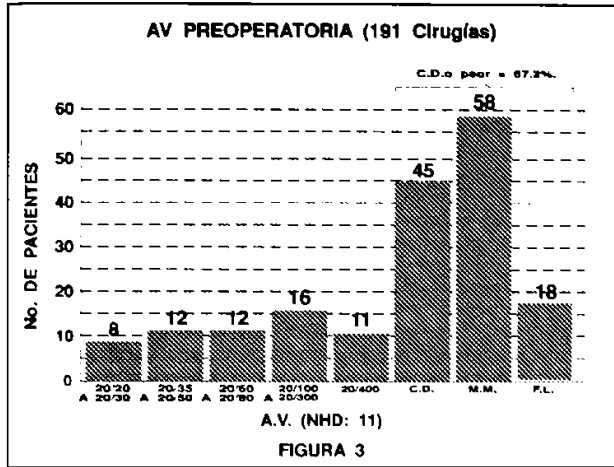
<b>HALLAZGOS ASOCIADOS AL D.R.- (177 OJOS)</b>		
	<b>No. OJOS</b>	<b>%</b>
PVR	27	15.2%
HV	6	3.3%
LATTICE	4	2.2%
AGUJERO MACULAR	3	1.6%
GRANULOMA	3	1.6%
QUISTE RETINIANO	2	1.1%
RETINOSQUISIS SENIL	2	1.1%
RC	2	1.1%
PARS PLANITIS	2	1.1%
DESPRENDIMIENTO DE LA ORA	1	0.5%
DC	1	0.5%
COMPLEJO MERIDIONAL	1	0.5%
PLIEGUE MERIDIONAL	1	0.5%
FLUIDO EXUDATIVO (SHIFITING FLUID)	1	0.5%
D.G.	1	0.5%
BUCKLING ALTO Y PERIFERICO	1	0.5%

PVR= Proliferación vítreo retiniana. H.V. = Hemorragia vítrea,

RC= Retinocoroiditis, DC= Desprendimiento coroideo, DG = Desgarro gigante.



o mejor en el 57.2% de los casos o lo que vale decir de éxito funcional (Figs. 3 y 4).



En resumen, la agudeza visual mejoró en 107 casos, para un 69.0%, se mantuvo igual en 27 casos, para un 17.4%, y empeoró en 21 casos, para un 13.5%.

La tensión intraocular preoperatoria tuvo un rango de 2 a 30 mm/hg y una media de 12.2 mm/hg, la cual fue 2.08 mm/hg menor que la media del ojo contralateral.

La tensión intraocular postoperatoria tuvo un rango de 7 a 50 mm/hg, con una media de 14.7 mm/hg. Las complicaciones de la cirugía se presentaron

en 114 de las 191 cirugías realizadas, para un 59.6%. Las complicaciones intraoperatorias ocurrieron en 43 casos, para un 22.5%, siendo las más frecuentes: sutura perforante 11 casos, para un 5.7%; hemorragia coroidea y subretiniana en 8 casos, para un 4.1%; bloqueo inadecuado de la ruptura en 7 casos, para un 3.6%; drenaje incompleto de líquido sobretiniano en 6 casos, para un 3.1%; hipotonía e incarceration vítreo en el sitio de drenaje en 5 casos, cada uno para un 2.6% (Tabla 4). Las complicaciones tempranas ocurrieron en 71 ocasiones, para un 37.1%, siendo las de mayor frecuencia: desprendimiento de retina residual en 33 casos, para un 17.2%, y el aumento de la tensión intraocular en 26 casos, para un 13.6% (Tabla 5). Las complicaciones tardías ocurrieron en 44 casos, para un 23%, y las que más frecuentemente se presentaron fueron: desprendimiento de retina recidivante en 17 casos, para 8.9%; extrusión del exoplante en 6 casos, para un 3.1%; pucker macular y miopización en 5 casos, cada uno para un 2.6%, esta última tuvo una media de -2 dioptrías (Tabla 6). De las 177 cirugías primarias realizadas se logró reimplantar la retina en 148 ojos, para un 83.6% de éxito anatómico con una cirugía. De los 29 ojos con fracaso anatómico, en 14 se realizó una nueva cirugía convencional de retina con éxito en 10 de ellos, para un total de 158 ojos con éxito anatómico (incluyendo las reintervenciones), para un 89.2%.

Del resto de los pacientes, 5 no regresaron para la nueva cirugía convencional y en los 10 ojos restantes se logró reimplantar la retina por medio de cirugía vitreoretiniana con aceite de silicón en 7 de ellos, para un 70%.

### Comentarios

Es de todas conocida la efectividad de la técnica descrita de cirugía convencional de desprendimiento de retina regmatógeno, la cual permite, como en nuestro estudio, un éxito anatómico de aproximadamente del 90%, pero llama la atención cómo esa efectividad se mantiene, a pesar de

TABLA 4

<b>COMPLICACIONES INTRAOPERATORIAS (191 CIRUGIAS)</b>		
	<b>OJOS</b>	<b>%</b>
SUTURA PERFORANTE	11	5.7%
HEMORRAGIA COROIDEA/SUBRET	8	4.1%
BLOQUEO INADECUADO	7	3.6%
DRE - LSR IMCOMPLETO	6	3.1%
HIPOTONIA	5	2.6%
INCARCERACION VITREA EN SITIO DRE-LSR	5	2.6%
HV	3	1.5%
INCARCERACION DE LA RETINA	3	1.5%
NECROSIS ESCLERAL POR CIR. PREVIA	3	1.5%
SALIDA DE VITREO POR SITIO DRE - LSR	2	1.0%
TRACCION VITREA SOBRE DH	1	0.5%
INCARCERACION UVEAL	1	0.5%
BOCA DE PESCADO	1	0.5%
RUPTURA RETINIANA AL DRE - LSR	1	0.5%
DC.	1	0.5%

SUBRET = Subretiniana, DR - LSR = drenaje del líquido subretiniano, HV = Hemorragia vítrea, Cir = cirugía, D.H = desgarro en herradura, DC = Desprendimiento coroideo.

demostrar que en un 59.6% de los casos se presentó algún tipo de complicación, la cual no fue obstáculo en la mayoría de las ocasiones para el éxito de la cirugía. Esto no debe interpretarse como un indicio a favor de menospreciar la presentación de dichas complicaciones sino como un fuerte apoyo a la premisa de que un buen manejo es la clave para un buen resultado.

Podemos correlacionar un éxito funcional de sólo un 57.2% con una casuística que acude a nuestra institución con desprendimiento de retina que tiene una media de 4.5 meses de evolución, y de las cuales el 76.2% tienen la mácula desprendida; por otra parte, recordemos cómo el 14.1% de los casos nos llegó durante este período con una media de 1.4 cirugías previas por ojo.

Los antecedentes más importantes coinciden con los más frecuentemente reportados en la literatura como son: miopía, trauma y afaquia<sup>(5, 6, 7, 8)</sup>.

Es de gran importancia diagnóstica y de tratamiento el determinar mediante nuestro estudio que el 67.2% de las rupturas retinianas, exceptuando las diálisis (91.4% ínfero temporales), se encuentran localizadas en los cuadrantes superiores.

En el 15.2% de los ojos el desprendimiento de la retina se acompañó de proliferación vitreoretiniana que en nuestro estudio no se clasificó pero que indiscutiblemente no era severa y sin embargo demuestran cómo un porcentaje de casos con

TABLA 5

COMPLICACIONES P.O. TEMPRANAS (191 CIR.)		
	No. OJOS	%
D.R. RESIDUAL	33	17.2%
HIPERTENSION OCULAR	26	13.6%
PUCKER MACULAR	7	3.6%
PVR	6	3.1%
DC	6	3.1%
HV Y FIBRINA	5	2.6%
MIGRACION DE PIGMENTO		
SUBRET EN POLO POST.	4	2.0%
MER (0)	3	1.5%
FLUIDO ATRAPADO ANT.	3	1.5%
EDEMA PALPEBRAL SEVERO	2	1.0%
EDEMA CORNEAL	2	1.0%
EXTRUSION DEL EXOPLANTE	2	1.0%
BOCA DE PESCADO	1	0.5%
EMC	1	0.5%
QUEMOSIS	1	0.5%
ASTIGMATISMO SEVERO	1	0.5%
HEMATOMA SUBCONJUNTIVAL	1	0.5%
KEP	1	0.5%
DEHISCENCIA DE SUTURA		
DE LAS ESPONJAS	1	0.5%
HEMORRAGIA SUBRET.	1	0.5%

Cir. = Cirugía, D.R = Desprendimiento de retina, PVR = Proliferación vitreoretiniana, DC = Desprendimiento coroideo, HV = Hemorragia vítrea, SUBRET. = Subretiniana, MER (0) = Membrana epirretiniana grado 0; ANT. = Anterior, EMC - Edema macular cistoide, KEP = Queratitis epitelial punctata.

proliferación vitreoretiniana de leve a moderada (probablemente hasta un grado de CP tipo 1 en un cuadrante) pudiera tratarse con éxito, utilizando un procedimiento convencional de desprendimiento de retina. Queremos resaltar que dentro de nuestras complicaciones encontramos una incidencia de PVR del 5.2% (excluyendo el pucker macular), la cual está dentro de las cifras reportadas por otros autores.

Quisimos comprobar la impresión clínica ya bien descrita de cómo la TIO es menor en el ojo con DR y la diferencia encontrada fue de 2.08 mm/hg, el tono normal se recupera al reaplicarse la retina quirúrgicamente. A pesar de que en nuestra técnica quirúrgica la utilización de la crioterapia es muy mesurada, encontramos 7 casos, para un 3.6%, con dispersión pigmentaria subretiniana al polo posterior, cifra que, por otra parte, está muy dejado

TABLA 6

<b>COMPLICACIONES TARDIAS (191 CIR.)</b>		
	<b>No. OJOS</b>	<b>%</b>
D.R. RECIDIVANTE	17	8.9%
EXTRUSION DE EXOPLANTE	6	3.1%
PUCKER MACULAR	5	2.6%
MIOPIZACION	5	2.6%
PVR	4	2.0%
MER (0)	4	2.0%
MIGRACION DE PIGMENTO		
SUBRET A POLO POST	3	1.5%
DEHISCENCIA DE SUTURA		
DE LA ESPONJA	3	1.5%
DIPLOPIA	2	1.0%
FLUIDO ATRAPADO ANTERIOR	2	1.0%
HIPERTENSION OCULAR	2	1.0%
NECROSIS ESCLERAL	2	1.0%
CICLITIS	1	0.5%
DC	1	0.5%
INFECCION DE EXOPLANTE	1	0.5%
EMC	1	0.5%
TRACCION VITREORRETINIANA		
EN DH BLOQUEADO	1	0.5%

D.R. = Desprendimiento de retina, PVR = Proliferación vítreo retiniana,  
 DC = Desprendimiento coroideo, SUBRET = Subretiniana,  
 MER (0) = Membrana epirretiniana grado 0, EMC = Edema macular cistoide,  
 DH = Desgarro en herradura.

de la reportada en otras series. Sin embargo, no fue un factor importante en detrimento del éxito funcional, ya que de 5 casos con éxito anatómico, el 100% tuvo una A.V. de 20/100 o mejor.

Las complicaciones relacionadas con la cirugía ocurren con mayor frecuencia en el postoperatorio

temprano, pero con un manejo adecuado, en la mayoría de los casos, no afectan el resultado. Finalmente el éxito anatómico aumenta con las reintervenciones, disminuyendo de esta manera la complicación más importante desde el punto de vista de resultados como es el desprendimiento de la retina residual o recidivante.

---

## Summary

---

The authors communicate the results and complications of righthematogenous retinal detachment surgery performed in 177 eyes of 167 patients at Fundación Oftalmológica Nacional of Bogotá, Colombia, from 1985 to 1992. We found that complications occurred in 59.6% of the cases but they were no obstacle to anatomic success which was achieved in almost 90% of the cases. Complications were present most frequently in the first 6 weeks postop and included residual retinal detachment and high intraocular pressure.

---



---

## Bibliografía

---

1. Chignell, A.H.; Fison, L. G.; Davies, E.W.G, et al: Failure in retinal detachment surgery. *Br. J. Ophthalmol.* 57:525, 1973.
2. Wilkinson, C.P.; and Bradford, R.H. Jr: Complications of draining subretinal fluid. *Retina* 4: 1, 1984.
3. Chan, C.K; Olk R.J.; Arribas, N.P.; et al: supplemental photocoagulation on the buckle for prevention of surgical revision after scleral buckling procedures. *Arch. Ophthalmol.* 105:490, 1987.
4. Michels, R.G.; Wilkinson, C.P.; and Rice, T.A.: Retinal detachment. St. Louis, The C.V. Mosby Company. 959-1057, 1990.
5. Benson, W.E.: Retinal detachment diagnosis and management. Philadelphia, J.B. Lippincott company. 33-52, 1988.
6. Hilton, G.F.; McLean, E.B.; Chuang, E.L: Retinal detachment. San Francisco. American Academy of Ophthalmology. 7-37, 1989.
7. Williams, G.A.; and Aaberg, T.M.: Techniques of scleral buckling. In Ryan, S.J *Retina*, Vol. 3, St. Louis, The C.V. Mosby Company. 111-149, 1989.
8. Schepens, C.L.: Retinal detachment and allied diseases, Vol 1, Philadelphia, W.B. Saunders Company, 23-67, 1983.
9. Bell, F.C.; Pruett, R.C.: Effects of cryotherapy upon extraocular muscle. *Ophthalmic Surgery*, Vol. 8, No. 1, 1977.
10. Eagle, R.C.; Yanoff, M. and Morse, P.H.: Anterior segment necrosis following scleral buckling in hemoglobin SC disease. *AM. J. Ophthalmol.* Vol. 75, No. 3, 426-433, 1973.
11. Wright, K.W.: The fat adherence syndrome and strabismus after retina surgery. *Ophthalmology* 93:411-415, 1986.
12. Lobes, L.A. and Grad, M.G.: Incidence of cystoid macular edema following scleral buckling procedure. *Arch. Ophthalmol.* 98:1230-1232, 1980.
13. Burton, T.C.: Irregular astigmatism following episcleral buckling procedure with the use of silicone rubber sponges. *Arch. Ophthalmol.* 90:447, 1973.
14. Portney, G.L.; Campbell, L.H. and Casebeer, J.C.: Acquired heterotropia following surgery for retinal detachment. *AM. J. Ophthalmol.* 73, No. 6: 985, 1972.

# Mechanical arcuate keratome for naturally occurring astigmatism

Dr. Kalil Hanna(\*)

Dr. Culbertson(\*\*)

---

## Abstract

To evaluate the usefulness of mechanical arcuate keratotomy for correction of astigmatism, we used a new system with a conical housing and two carrier-mounted micrometer diamond knives. The incision length, depth and location can be predetermined. Two series of patients with 2-7 D of naturally occurring astigmatism and postcorneal surgery were treated at two different institutions. A nomogram was used. Videokeratography documented corneal curvature changes. No overcorrection occurred in the initial series. Follow-up is not complete in the second series. Four eyes were  $\leq 1$  D of planned correction. The reduction of astigmatism varied from 43 to 91% with a mean of 70%. The achieved reduction decreased in the first month by 0.2 D or 6.8% with a maximum in one eye of 24%. The best uncorrected visual acuity increased in all patients. The nomogram used tends to induce undercorrection. Arcuate Keratotomy with this mechanical keratome permits deep, linear cuts with early stabilization of the achieved correction.


---

(\*) is affiliated with Hotel-Dieu Hospital, Paris, France and the Department of Ophthalmology, Emory University School of Medicine, Atlanta, Georgia.

(\*\*) is affiliated with Bascom Palmer Eye Institute, Miami, Florida.



# Queratomileusis miópica por congelación, 10 años de experiencia



ra. Iris Estrada Rodríguez (\*)

Se estudiaron los expedientes de 768 pacientes los que se les realizó Queratomileusis miópica por congelación, en un período comprendido de 1980 a 1991. El total de intervenciones quirúrgicas fue en 1.585 ojos, el 66.8% en pacientes del sexo femenino y 33.2% en el sexo masculino, con edades comprendidas de 18 a 38 años con una media de 27.7 años.

## Estudios pre-operatorios

El estudio pre-operatorio comprendió exploración oftalmológica completa: Agudeza visual, Refracción, Queratometría, Biomicroscopia, Tonometría, Exploración de fondo de ojo y Perimetría electrónica (calculada al 100% con G.H.).

Dioptrías por corregir tuvieron un rango de -1.00 a -24.00 con una media -12.50 y con astigmatismo de -0.50 a -6.00 Dp., queratometría de 40.00 la más plana y 48.00 la más curva.

## Resultados post-operatorios

Los resultados obtenidos son los siguientes:

Agudeza visual: 20/20 hasta 20/100  
con una media de 20/40

Refracción: -0.75 a -2.00 con una media de -2.75 Dp.

Queratometría: 34.50 la más plana y 45.75 la más curva.

Estabilidad post-operatoria:

Efecto regresivo	Temporalidad
1.12 Dp	1 mes - 6 meses
0.45 Dp	6 meses - 1 año
0.37 Dp	1 año - 2 años
0.12 Dp	2 años - 3 años
0.12 Dp	3 años - 4 años
0.12 Dp	4 años - 5 años
0.12 Dp	5 años - 10 años

## Complicaciones

Edema corneal, epitelización de la interfase, ectasia corneal, pérdida del lenticulo.

Con este trabajo concluimos que esta técnica es efectiva y estable para la corrección de Miopías elevadas.

# Epimacular proliferation

Steve Charles, M.D.

Results of the largest, consecutive, prospective, single surgeon series of vitreous surgery for epimacular membranes (EMM) will be reported. Pre-op visual acuity was better than 20/70 in a significant number of cases and 20/40 in many. Active patients, athletes, and selected professionals should not be subjected to the typical entrance criteria of 20/100 or worse utilized by many surgeons.

Removal of the vitreous was utilized only if the vitreous was abnormal. Clear vitreous can be maintained without difficulty after removal of epiretinal membranes, hopefully resulting in reduced detachment in cataract cases.

An "edge" was not a criteria for surgery as was thought to be by many surgeons. An incision was made through the epicenter of the epimacular membrane utilizing the MVR blade to initiate the process in most cases. This was followed by use of the microtipped, diamond-coated, end-opening forceps to grasp this internal interface created to allow circumlinear inside-out membrane peeling. In all cases, inside-out membrane peeling was utilized rather than typical pic outside-in membrane

peeling utilized by others. Especially adherent membranes were removed by scissors delamination.

The author has postulated that the high incidence of progressive nuclear sclerosis is because of lens heating (Joseph Terry) and UV exposure from the operating microscope. This would correlate with the high incidence of nuclear sclerosis reported after peripheral iridectomy, filtering procedures, and penetrating keratoplasty. It certainly raises an issue about longterm effects of keratorefractive surgery because of the exposure to the operating microscope. The heating of the lens was measured in cases and a small series was randomized to cooling the intraocular fluid and no cooling after an initial series of five consecutive years of cooling the infusion fluid.

The recurrence rate is approximately 2.5% but requires strict definition as there are healing findings in the internal limiting lamina of the vast majority of cases. Strict definition of a recurrence would include elevation of the fovea with initial increases vision followed by subsequent reduced vision not explainable by nuclear sclerosis.