

## CHRONIC EXTERNAL PROGRESSIVE OPHTHALMOPLÉGIA

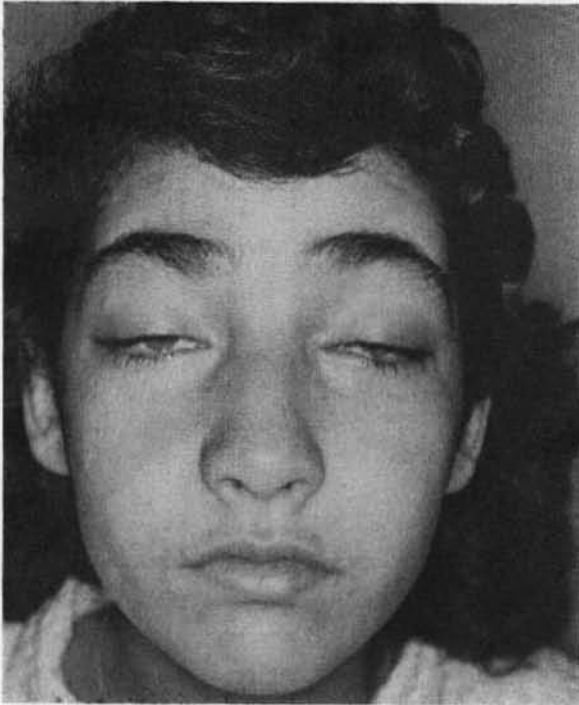
BY

GEORGES ASSIS M., M. D.

Cali, Colombia

Although external ophthalmoplegia occurs in many diseases, chronic external progressive ophthalmoplegia, best referred to as abiotrophic ophthalmoplegia, is a clinical condition accepted as a separate entity. It is characterized by gradual development of ophthalmoplegia and ptosis without involvement of the pupils and accommodation. Both eyes are involved but not necessarily to the same degree. It usually progresses toward total ophthalmoplegia, although there may remain limitation of the eyelids or the eyelids and the elevator muscles of the eyes. Rarely is it associated with other abiotrophic degeneration like retinitis pigmentosa and spinocellular atrophy. It attacks both sexes and can occur at any age. The more advanced the age of the patient, the more benign is its course, and there are more possibilities that it will not lead to complete ophthalmoplegia.

Investigators have recently been in agreement that the characteristic changes of this disease are of the type usually observed in the skeletal muscles in cases of progressive muscular dystrophy, and they agree that in chronic progressive ophthalmoplegia these changes are correlated with progressive muscular dystrophy and represent a special type of this disease, with predominance or predilection in the extraocular muscles. They sustain this in that some cases have presented themselves concomitantly with dystrophic changes in the skeletal muscles. 2, 3, 4, 5, 6, 7. Lapresle and Jarlot found evidence of progressive muscular dystrophy in three cases with biopsy of the extraocular muscles. 8. The Brumbacks note an additional case also proved by biopsy.



Inexpressive face. Photograph in primary position. The small palpebral fissure is due to contraction of the frontal muscles.

A patient with external progressive ophthalmoplegia in association with abiotrophic retinal degeneration was studied by Thorson and Bell. The muscular weakness and ptosis were attributed to external dystrophic ophthalmoplegia and were proved by electromyography and biopsy. 10. It is generally accepted that creatinuria is common in all classes of diseases that affect the general musculature and that it is particularly marked in muscular dystrophies. 11, 12, 13.

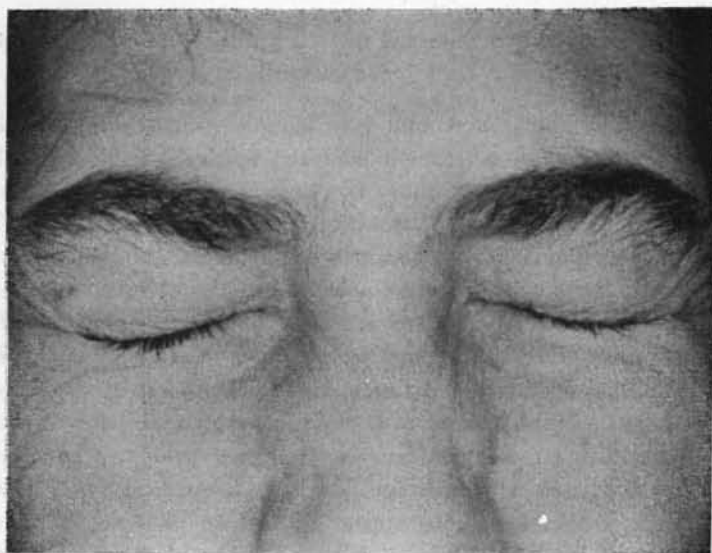The differential diagnosis is made especially with myasthenia gravis. Both conditions produce similar signs and symptoms. In abiotrophic ophthalmoplegia there is an absence of diurnal fluctuations, non-association with fatigue, and non-involvement of the limbs. The definite differentiation is made by the use of Neostigmine or with Tensilon chloride, which do not produce any favorable improvement in abiotrophic ophthalmoplegia but which are positive in cases of myasthenia gravis.

The exclusion of the pupil with paralysis of the third cranial pair is a characteristic of diabetic ophthalmoplegia. Investigators suggest that the persistence of normal pupillary reaction was due to the non-involvement of the circumferential

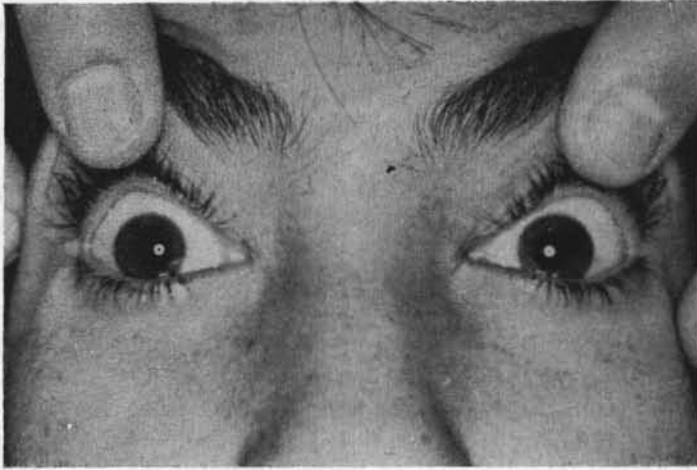
portion of the third nerve. 14. Jack E. Goldstein, M. D., and David G. Cogan, M. D., of Boston, in their study of 21 cases, found that this pupillary exclusion is present in the majority of cases, although in some cases various degrees of iridoplegia were encountered. This is contradictory to the non-diabetic cases and due to tumors or aneurysms where the pupil is usually involved. The course of the ophthalmoplegia is benign, gradually disappears in a few months, and is more characteristic in diabetic patients of poor control and of long duration. 15.

*Case presentation:* 16 years old, female, caucasian. Relates that she began to note falling of the superior eyelids four years ago, beginning with the left eye, and that it became progressively more severe, ending in complete ptosis for which she tried to compensate by contracting the frontal muscles and inclining the head toward the back. At the same time she experienced increasing difficulty in moving the eyes in any of the cardinal directions. She did not refer to night blindness, diplopia, or modification of the ptosis during the day. She is temperamentally unstable and not very sociable, has lack of appetite, and suffers frequent insomnia.

*Personal History:* At the age of one year she had a "Suppurative infection" in one ear which lasted for two years; the measles at three years of age; whooping cough at nine, smallpox at eleven, menarche ten months ago, and an irregular cy-



The orbicular muscles are normal.



The eyes are almost fixed in all cardinal positions.

cle very three to four months with a duration of three days. Intermittent tonsillitis.

*Family History:* Negative.

*Physical Examination:* B.P.: 110/70 T: 36.6°C. R :20.

On inspection the patient is observed to be longilineal, 16 years of age, bright, in fair state of nutrition, and does not appear ill.

*Head-eyes:* V.A.: 20 25/30 s. and c.c. complete bilateral ptosis with palpebral fissure of 5 mm. and permanent contraction of the frontal muscles which elevates the eyebrows somewhat above the superior orbital border. The eyes are able to close well with no sign of weakness of the orbital muscles. They were found to be in the primary position and their movement almost restrained. Complete paralysis of the superior rectus muscles and the oblique muscles, and incomplete paralysis of the other rectus muscles. Normal sensitiveness of the corneas; circular pupils of equal size and with normal reaction to light; direct and consensual. Pupillar reaction to accommodation and attempt at convergence normal. Accomodation present in both eyes and is normal; absence of convergence and of Bell's phenomenon and the face generally inexpressive (Hutchinson's facies) and the thin neck is consistant with her longilineal type. The muscles of the face, neck, trunk, and limbs appear normal on physical examination. An examination with a slit lamp did not show any signs of disease in the anterior portions of the ocular globes, including the vitreous humor.

PROGRESSIVE OPHTHALMOPLEGIA

*Ophthalmoscopy:* Choroidal ring around the papillae; generalized pigmentary disturbance which involves both macular regions, irregular without having predilection with the vessels; papillae slightly pale. The vascular system is found in general in good condition, although the arteries are diminished in caliber. (Ophthalmological picture of Retinitis Pigmentosa). She did not appear to have difficulty in adapting to darkness. Normal vitreous humor.

*Campimetry and perimetry:* Show visual fields peripherally contracted to 20 degrees.

*Schirmer test:* OD: 40 mm|5 minutes.

OI: 35 mm|5 minutes.

*Neostigmine test:* (1.5 mg.) = negative.

*Worth test:* Intermittant diplopia for both near and far vision.

*Ears and Neck:* Normal.

*Abdomen:* Negative.

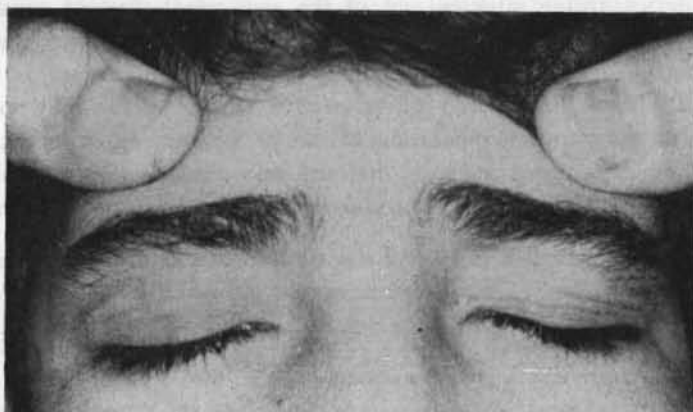*Heart and Lungs:* Negative.

*Genitales:* Negative.

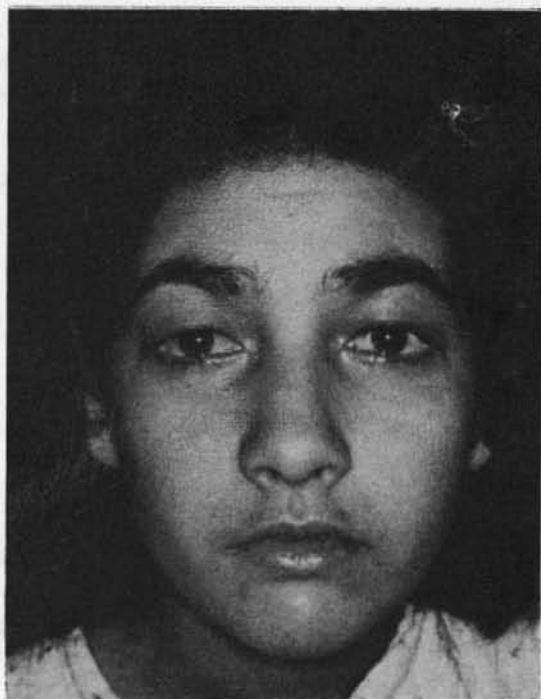*Neurologys* With the exception of the involvement of the extraocular muscles and ptosis, the neurological test was negative.

*Laboratory:* Urine: creatinine 45.5% — 466.3 mg.|24 hours; creatine 57.3% mg.|24 hours: (volume of urine 1.025 c.c.). Density; 1.009, yellow color.

Blood: Inorganic phosphorus 8.0 mg%; creatinine 1.36 mg%; creatine 2.71 mg%; total calcium 8.5 mg%; glucose 92 mg%; urea 23.1 mg%; uric nitrogen.



Complete ptosis when the eyebrow in normal position.



Photograph of patient after operation using Friedewald Guyton's Method.

10.8 mg%; hemoglobin 14; globular volume 43. Leukogram; bands 6, segmented 50; lymphocytes 35, monocytes 2; leukocytes 6,500. Serology negative. Basal metabolism normal. Photofluorography normal. A biopsy was taken of the left superior rectus muscles and of the sternocleidomastoid muscle, which were studied by the hematoxylin and eosin technique. In the superior rectus the following changes were found in different sections: difference in caliber of the muscular fibers, infiltration of connective tissue, hypertrophy and central localization of some nuclei, separation of the peripheral cap of the sarcolemma. The pathology department suggests that the said changes are common to dystrophic myopathy. The biopsy of the sternocleidomastoid muscle was negative.

*Comment:* The clinical history and the clinical and pathological findings indicate a case of progressive chronic ophthalmoplegia, sporadic type, associated with degenerative retinal abiotrophy (atypical retinitis pigmentosa). The excretion of creatinine and creatine in the urine was increased, corroborating the diagnosis.

The treatment followed in this case was limited to the correction of the ptosis by Friedewald Guyton's method and the results were satisfactory.

## PROGRESSIVE OPHTHALMOPLÉGIA

From the Division of Ophthalmology, Department of Surgery, and the Department of Pathology, Universidad del Valle, Medical School, Cali, Colombia, S. A.

### BIBLIOGRAPHY

1. DAVID G. COGAN, M. D.: *Neurology of the Ocular Muscles*: 37-51, 1956.
2. BECKETT, R. S., and NETSKY, M. G.: *Familial Ocular Myopathy and External Ophthalmoplegia*, A. M. A. Arch. Neurol. & Psychiat. 69: 64-72, 1953.
3. GARTNER, S., and BILLET, E.: *Progressive Muscular Dystrophy involving the Extraocular Muscles: Report of a case*, Arch. Ophth. 41: 334-340, 1949.
4. KILCH, L. G., and NEVIN, S.: *Progressive Dystrophy of the External Ocular Muscles (Ocular Myopathy)*, Brain 74: 115-143, 1951.
5. McAULEY, F. D.: *Progressive External Ophthalmoplegia*, Brit. J. Ophth. 40: 686-690, 1956.
6. SANDIFER, P. H.: *Chronic Progressive Ophthalmoplegia of Myopathic origin*, J. Neurol. Neurosurg. & Psychiat. 9: 81-83, 1946.
7. SCHWARDS, G. A., and LIU, C. N.: *Chronic Progressive External Ophthalmoplegia*, A. M. A. Arch. Neurol. & Psychiat. 71: 31-53, 1954.
8. LAPRESLE, J. and JARLOT, J.: *Ocular Myopathic: Contribution to the study of Progressive External Ophthalmoplegia*. Arch. Ophth. 19: 384-396, 1959.
9. BRUMBACK, J. E., and BRUMBACK, J. E., Jr.: *Nuclear Ophthalmoplegia with biopsy of extraocular muscle*, Maryland M. J. 8: 614-615, (Nov.), 1959.
10. THORSON, J. C., and BELL, W. E.: *Progressive Dystrophy External Ophthalmoplegia with Abiotrophic fungus changes*, A. M. A., Arch. Ophth. 62: 833-838, (Nov.), 1959.
11. MILHORAT, A. T.: *Creatine and Creatinine Metabolism and diseases of the Neuro-muscular System*, A. Res. Nern. & Ment. Dis. Proc. 32: 400-421, 1953.
12. VAN PILSUM, J. F., and WOLIN, E. A.: *Guanidinium Compounds in and Urine of Patients Suffering from Muscle Disorders*, J. Lab. & Clin. Med. 57: 219-233, 1958.
13. SHANK, R. E.; GILDER, H., and HOAGLAND, C. L.: *Studies on Diseases of the of Muscle: 1 Progressive Muscular Dystrophy; A Clinical review of 40 cases*, Arch. Neurol. & Psychiat. 52: 431-442, 1944.
14. DREYFUS, P. M.; HAKIM, S., and ADAMS, R. D.: *Diabetic Ophthalmoplegia* A. M. A. Arch. Neurol. & Psychiat. 77: 337-349, 1944.
15. JACK E. GOLDSTEIN, M. D., and DAVID G. COGAN, M. D., Boston: *Diabetic Ophthalmoplegia with special reference to the pupil*. A. M. A. Arch. Ophthalmology. 64: 594-600 (Oct.), 1960.