

DYNAMIC CHANGES OF VISUAL FIELDS AND SCOTOMATA BY TREATMENT OF OPTIC NERVES ATROPHY

BY

MOUSSABEKOVA UMNISSA, M.D.

Baku, U.S.S.R

Optic nerves atrophy is a frequent result of inflammatory and degenerative changes of optic nerves, optic chiasm and optic tracts. The disorder of different optic functions can be observed in such cases. The diminution of visual acuity isn't a specific symptom, and so it has little diagnostic significance. The changes of the visual fields limits and the character of scotomata are main diagnostic symptoms. Therefore the close study of them in the dynamics of process is necessary for clinical and topical diagnosis of the disease.

In the course of years under our observation there were 100 patients (178 eyes) with atrophy of optic nerves, men - 63, women - 37.

The causes of optic nerves atrophy were: chiasmatic arachnoiditis - 17 persons, optic encephalitis - 10 persons, arachnoiditis - 8 persons, brain arteriosclerosis - 14 persons, syphilis - 4 persons, poisoning (quinine, alcohol) - 4 persons, trauma - 6 persons, meningitis - 2 persons, hypertensive neuroretinopathy - 6 persons, disseminated sclerosis - 2 persons, unestablished aetiology - 27 persons.

The age of the patients:

10-20 years of old	- 16 persons,
21-30 "-"	- 29 "
31-40 "-"	- 26 "
41-50 "-"	- 9 "
51-60 "-"	- 7 "
over 60 "-"	- 13 "

The duration of the disease:

2-6 months	- 30 persons,
7 months-2 years	- 18 "
3-5 years	- 44 "
11-20 "	- 8 "

Atrophy of optic nerves was complete in 153 eyes and partial in 25.

All the patients with optic nerves atrophy got a complex therapy 2-3 times a year. It consisted of general and local treatment.

General treatment:

Intravenous infusions of 40% glucose alternating with a 40% solution of urotropine or a 10% solution of sodium chloride; after some interval a 10% solution of potassium iodine administered intravenously; on the whole 10 infusion each.

Hypodermic injections of vitamin B-1 5% - 30 injections and vitamin B-12 15 injections, then after a fortnight interval hypodermic injections of 1% nicotinic acid - 30 injections.

We include another kind of stimulating treatment into general therapy too: blood plasma 50.0 - 100.0 was infused intravenously twice a week in the course of treatment, on the whole 6 infusions made by drops. To a part of patients, instead of intravenous infusions of blood plasma, albumin hydrolyzate was administered hypodermically in quantity 50 - 100 grams by 70 drops a minute.

Local therapy

Injections of sodium nitrate were made daily (in turns) under the temple skin beginning with 0.5% up to 5% of solutions. The doses were 0.2 - 0.4 - 0.6, then the per cent of the medicine increased. The total number of injections 30-40 in the course of treatment.

At the same time the patients got daily diathermy on the eye, the dropping of 1% pilocarpine and vitamins and the subconjunctival injection of oxygen or a 1% salt solution (on the whole 10 injections).

In the course of treatment the patients underwent several investigations. Considerable changes in the limits of optic field, kind and size of scotomata were revealed. The data on concentric constricted visual fields in patients with optic nerves atrophy in the dynamics of process are seen in figure 1.

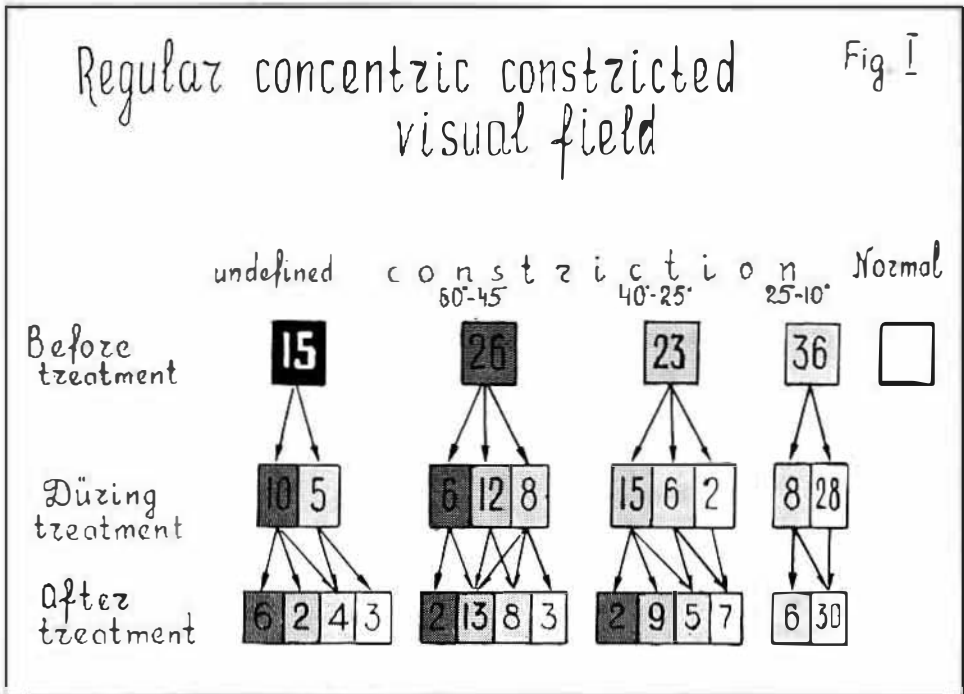


Fig. I.

As it is seen in the figure, the visual field wasn't defined in 15 cases (eyes) at the beginning of hospitalization. In the course of treatment it appeared, the constriction of limits being 40-60 degrees in 10 eyes, and 10-20 degrees in 5 eyes.

When the treatment was over in this subgroup of eyes, the visual field data were different: Only 6 persons had constriction of visual field by 40-60 degrees, 2 persons by 25-30 degrees, 3 eyes became normal.

In the second group of patients the constriction of visual field was not proportional (irregular). The dynamics of the change of the visual field limits in the course of treatment is illustrated in figure II.

In this group of patients the visual field wasn't defined in 8 cases at the time of hospitalization. In the course of treatment it appeared with some constriction, being 45-60 degrees in 6 eyes and 25-40 degrees in 2 cases. When the course of treatment in this subgroup was over, the constricted visual field remained by 45-60 degrees in 4 cases and by 25-40 degrees in 4 eyes too. The normal visual field was found in 14 eyes out of 55 eyes with some non-proportional (irregular) constriction.

The deterioration of the visual field limits by the end of treatment was observed in two cases, the visual field being constricted by 40-60 degrees. In spite of active treatment, the optic nerves atrophy progressed.

The third group of patients presented people with hemianopia, there being 10 of them.

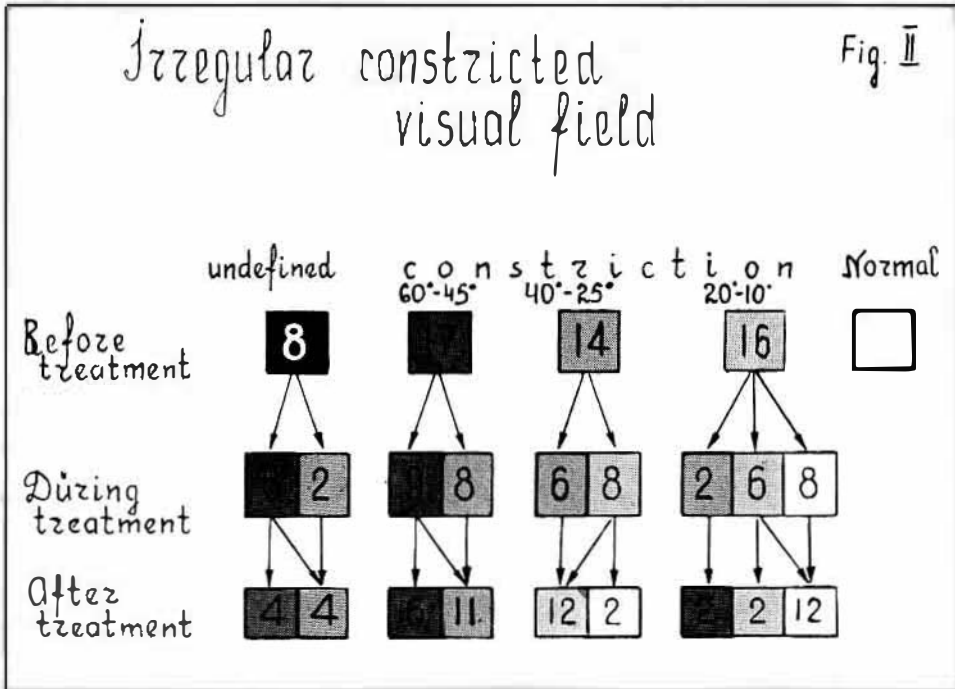


Fig. 2.

Hemianopsia:

- Right-hand homonymous hemianopia with the immunity of macular field 1 pers.
- Temporal loss of visual field and the blindness of the second eye 2 pers.
- Left-hand homonymous positive scotomata 1 pers.
- Bitemporal upper quadrantanopia with loss of macular field 2 pers.
- Bitemporal hemianopia with macular field for one eye 2 pers.
- Bitemporal lower positive scotomata 1 pers.
- Upper horizontal hemianopia with macular field 1 pers.

10 persons

VISUAL FIELDS

The causes of homonymous hemianopia may be optic tract diseases and injury of the central neuron or cortex. A number of symptoms are important for the topical diagnosis of hemianopia. According to the opinion of E. Tron, the combination of simple optic atrophy with homonymous hemianopia shows the localization of the focus of disease in the optic tract or in the chiasm. For the development of atrophy of optic nerves it is necessary a period no less than one year. Central hemianopia doesn't lead to atrophy of optic nerves.

The line of hemianopia demarcation isn't important for topical diagnosis of the process. The immunity of macular field in optic tract hemianopia was observed by H. Willbrand und A. Saenger, C. Behr, S. Henschen and oth. E. Tron marks this fact too. In wartime we observed too the immunity of the macular field in cases of hemianopia with the focus of disease in the optic tract.

In persons with optic nerve atrophy we observed homonymous hemianopia. That fact shows at the localization of the focus of disease in the back section of the optic chiasm. This is corroborated by another symptom, namely that the hemianopic defects of the visual field reached the extreme periphery of the visual field. Alongside with this, the defects of the visual field were unequal in extent.

As an illustration we state the following case: The patient A.S. 23 years old. Suffered chiasmatic arachnoiditis. The duration of the disease 6 years. At the time of hospitalization the vision of the right eye —0.02: temporal loss of the visual field without macular field. The left eye had inexact projection of light (figure III).

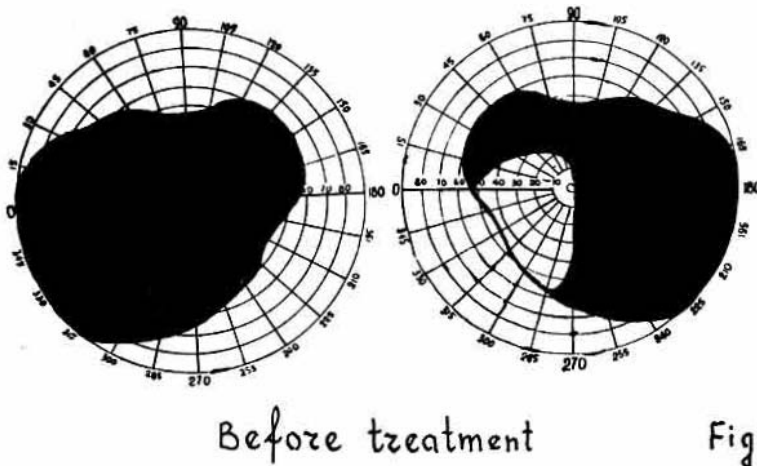
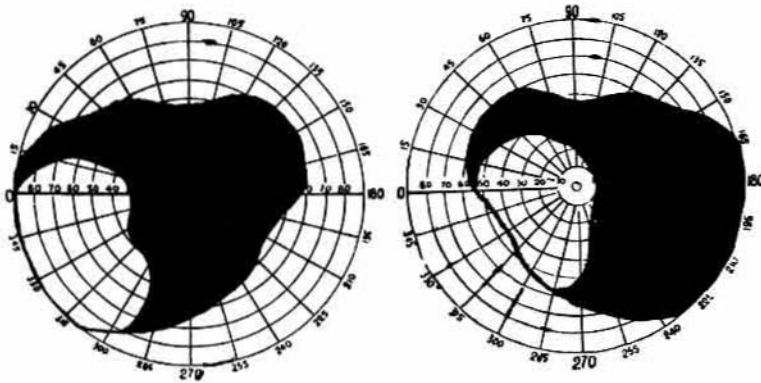


Fig. 3.

After treatment the vision of the right eye 0.6, the visual field extended by 25-33 degrees. Macular field loss. The vision of the left eye, former blind, was 0.07. In the outside half of the visual field there appeared a small sector without macular field. So we may say that after treatment the patient got a right - side homonymous hemianopia without macular field (figure IV).

According to E. Tron's opinion, the combination of blindness of one eye having nasal field loss with the temporal field loss of the other eye, that can see, is very characteristic. In those cases the focus of disease is on the lateral side of the optic tract. On the side where morbid symptoms appeared first we can state nasal field loss. It is caused by the affection of non crossing fibers. Later the process passes to the crossing fibers too, and temporal hemianopia develops.



After treatment

Fig IV

Fig. 4.

The course of the pathologic process can be imagined by figure V.

The following case is an example of heteronymous hemianopia with atrophy of optic nerves.

The patient M.Y. 16 years of old. Suffered chiasmatic arachnoiditis. The duration of disease 6 months. At the time of hospitalization vision of the both eyes 0.04. Upper bitemporal quadrantanopia without macular field. After treatment the vision of the right eye again 0.04, of the left eye 0.05. The visual field extended, but quadrantanopia remained (figures VI, VII).

Upper bitemporal quadrantanopia is connected with the focus of disease located medially below as far as the optic fibres going from the lower nasal part of the retina cross in the chiasm, nearer its lower surface.

VISUAL FIELDS

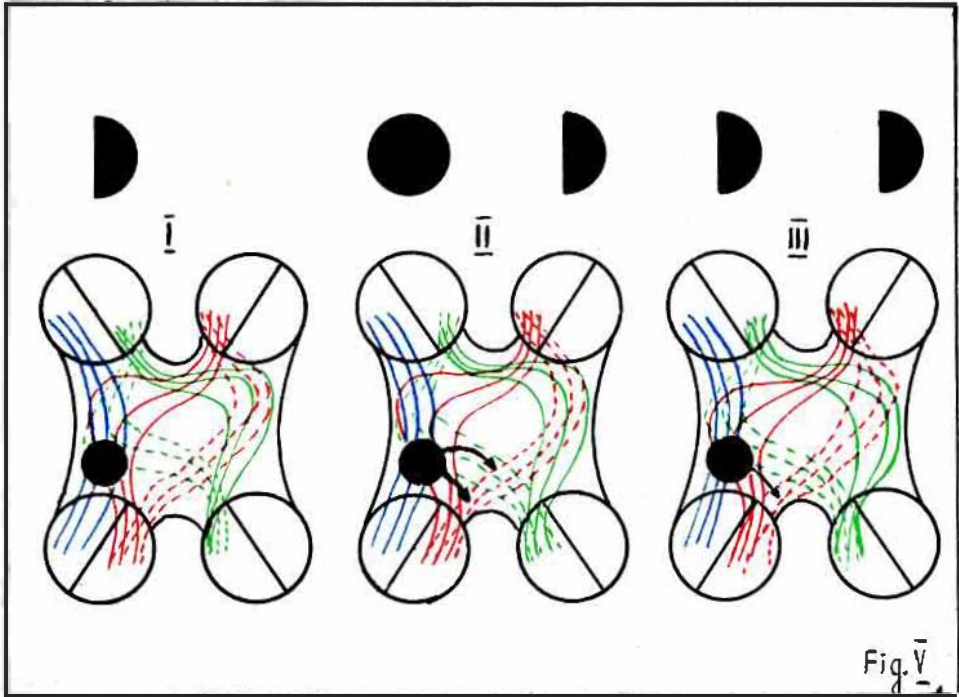
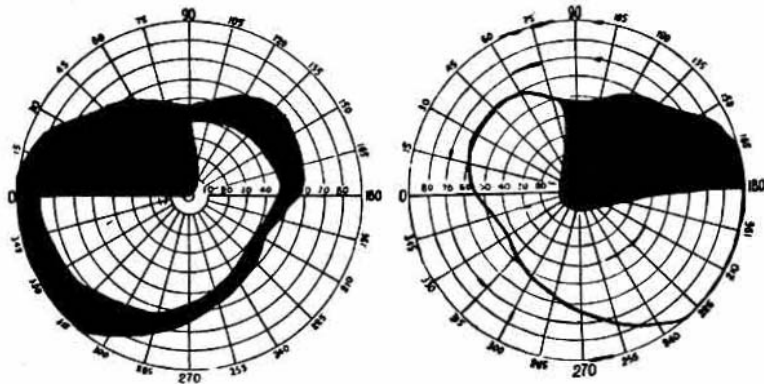


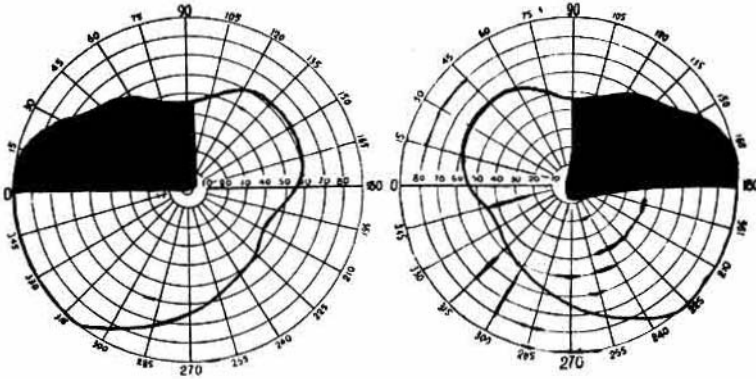
Fig. 5.



Before treatment

Fig. \bar{vi}

Fig. 6.



After treatment

Fig. VII

Fig. 7.

Bitemporal hemianopia was observed in one patient with disseminated sclerosis.

The patient A.K. 30 years old. The duration of the disease 2 months. At the time of hospitalization the vision of the right eye 0.9, of the left 0.2. Bitemporal hemianopia with macular field. After treatment the visual field extended, only bitemporal absolute positive scotoma remaining. The vision of the right eye 0.9, of the left 0.6.

Disseminated sclerosis leads to the changings of different parts of the visual pathways. H. Willbrand and A. Saenger, H. Openheim and H. Rönne point at the affection with disseminated sclerosis of the optic chiasm too. Our patient had neuritic atrophy of visual nerves with bitemporal hemianopia, what shows the process in the chiasm. At the period of the patient's being in the hospital the defects of his visual field changed their configuration and character. Absolute defects were revealed against the background of the relative loss of the visual field. H. Rönne observed mobile defects of the visual field of chiasmic type in cases of disseminated sclerosis.

They are explained by the peculiarities of the course of the disease and the localization of the process. The formation of new plaques were observed in its course. In some of them the desintegration of myelin sheaths is going on, in others- myelin can be restored.

Donald J. Lyle shows that plaques are very often formed in the optic nerve, the chiasm and the white matter around ventricles. In the same way they are formed in optic radiation too.

Sclerotic plaques are often formed in optic tracts, lateral geniculate bodies being involved in the process. The changes at the bottom of the fourth ventricle lead to nystagmus, the dissociation of the eyeballs' movement and to the motor paralysis. Disseminated sclerosis leads to demyelination of nervous fibers. As causes of disseminated sclerosis can be pointed out trauma, vascular lesions, allergy, hereditary factors and even enzymes. Optic disorders are the earliest symptoms of disseminated sclerosis. The visual field changes are various. One field of vision may be affected, or both. Retrobulbar neuritis gives a central scotoma, while the changes of the chiasm, the tract or optic radiation give different types of hemianopia.

Some temporary defects of the field of vision are known, which appear and disappear. The process of illness of our patient is rather typical for disseminated sclerosis.

Hemianopia, whether depending on the affection of centres or being cortical or subcortical, manifests itself in subjective sensations. R. Ring has found that the blind half of the field of vision is dark in cases of hemianopia of the optic tract. It is as if it were an absolute scotoma. Cortical or subcortical defect of the field of vision is as if it were a relative scotoma and not seldom they are revealed only in the process of perimetry.

Hemianopia with atrophy of optic nerves can be caused by different diseases of the central nervous system. One of the often causes is optic chiasmatic arachnoiditis. The defects of the field of vision in cases of hemianopia can be various. Their dynamics is known. Kleist believes that this dynamics can be observed in cases of fresh diseases. The reverse development of hemianopia caused by gunshot wounds of the cranium was observed by Kleist, E. Tron and others. The similar development of hemianopia in cases of cranial wounds was described by us too. However we observed the dynamics of hemianopia not only in fresh cases but in cases of long duration too. This dynamics is connected with the resolution of haemorrhages or oedema of the brain caused by trauma.

The dynamics of scotomata can be observed too in patient with atrophy of optic nerves. This fact is illustrated in figure VIII.

As it is seen from this figure, in 8 cases out of 49 scotomata escaped seeing before treatment. Later the vision of the patients improved and in 2 cases (eyes) there appeared absolute positive scotomata and in 2 cases relative positive ones. After treatment scotoma disappeared in 6 cases out of 49. In other cases scotomata changed their character and size. So in two cases scotomata remained absolute positive, in four cases absolute negative, in 15 cases - relative positive and in 22 cases - relative negative.

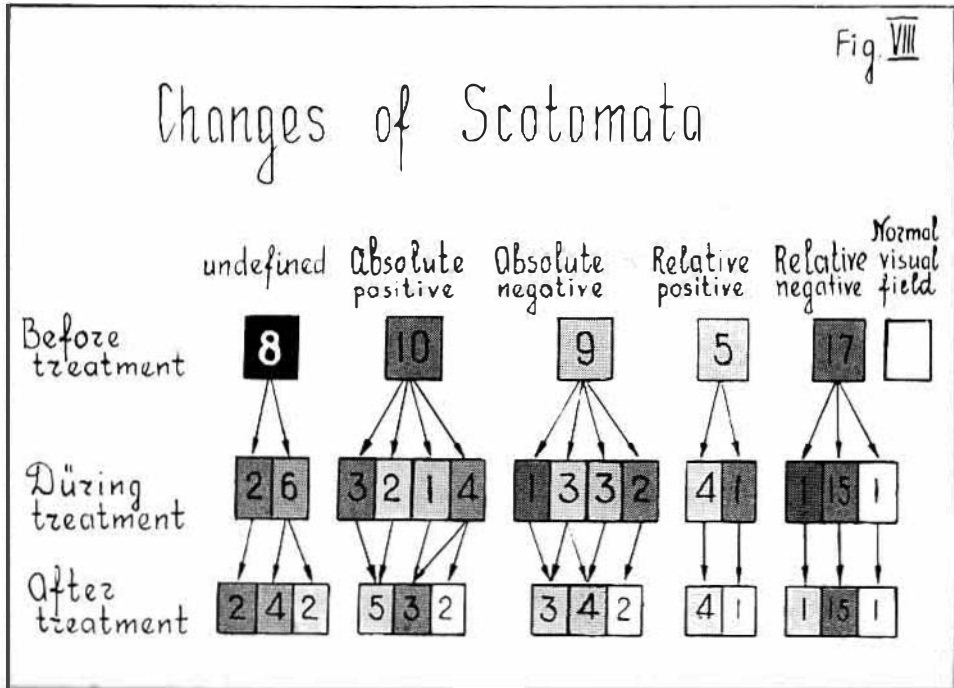


Fig. 8.

Naturally, treatment exerted influence on the visual acuity of eyes. The increase of acuity was observed in 106 eyes: in 65 eyes it doesn't change and only in 7 cases it decreased.

The degree of the raise of visual acuity in comparison with that before treatment was the following:

0.0.2 - 0.0.5	51 eyes
0.0.6 - 0.1	28 "
0.2 - 0.4	16 "
0.5 - 0.9	11 "

It is necessary to stress that treatment caused more favourable influence on the field of vision than on the acuity of vision.

In the course of treatment a part of patients with atrophy of optic nerves was investigated too from the point of view of the organ of sight. The investigation was carried out by the method of P. G. Snyakin suggested by him in the laboratory of the organs of senses at the Institute of Physiology by the Academy of Sciences of the USSR.

VISUAL FIELDS

It is known that the functional mobility of any organ of sense consists of alternate involvement of greater or lesser number of the receptors of that organ.

The number of active receptors of the organ of sight changes in dependency with the conditions of illumination of the surroundings. The reaction of only a part of receptors creates physiologic reserve. It is used when it needs. Adaptation mechanisms of the organ of sight is shown in this fact.

The study of functional mobility of the organ of sight in people with atrophy of optic nerves have displayed interesting data. It turned out that in treatment of atrophy of optic nerves the functional mobility of the organ of sight changes. Alongside with the improvement of vision and the extension of the visual field, it is marked the tendency to the normalization of response reactions to the change of the outer world illumination. The recovery of the function of the rods comes earlier than that of the cones. This phenomenon is explained by the fact that phylogenically the cones are much later formations than the rods.

SUMMARY

Complex therapy in cases of atrophy of optic nerves gives good results.

The effect of treatment is observed not seldom in cases of diseases of long duration too. Dynamic changes of visual functions take place in the process of treatment of optic nerves atrophy. Their study is necessary for the judgement about the efficacy of treatment. At the same time these investigations are important for the topical diagnosis of the focus of disease.

REFERENCES

- 1 — BEHR C. *Anatomie, Physiologie und Pathologie der Sehbahn*. Jena, 1935.
- 2 — BING R. *Gehirn und Auge*. München, 1923.
- 3 — DONALD J. *Lyle Neuro-Ophthalmology, USA, Illinois*, 1954.
- 4 — HENSCHEN S. E. *Handbuch des Neurologie*. Bd. I, Teil 2. Berlin, 1910.
- 5 — MOUSSABEKOVA U. *Izvestiya A. S. Azerbaijan*, 1945, № 5.
- 6 — OPPENHEIM H. *Lehrbuch der Nervenkrankheiten* 5 Aufl., Berlin 1908.
- 7 — RONNE H. *Über die Bedeutung der makulären Aussparung in hemianopischen Gesichtsfeld*. *Klin. M. Bl* Bd. 50, 1911.
- 8 — RONNE H. *Über klinische Perimetrie*. *Arch. Für Augenh.* 1921. 37.
- 9 — TRON E. *Zabolevaniya zritelnykh putei*. *Medgiz*, 1955.
- 10 — TRON E. *Voennaya Ophthalmonevrologiya*, Leningrad, 1945.
- 11 — WILLBRAND H. und SAENGER A. *Neurologie des Auges*. Bd. III, 1906.

Medical Institute Azerbaijan.