

## METASTATIC TUMOR IMPLANTS IN THE ANTERIOR CHAMBER

BY

GEORGE ASSIS - MASRI M.D.

EDUARDO REVEIZ R. M.D.

Cali - Colombia.

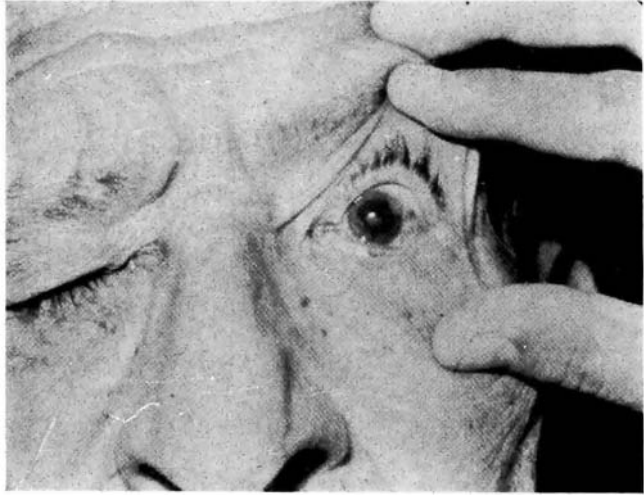
### *Case report:*

V.B. 78 years old, white male, came to the office complaining of pain, photophobia, lacrimation, blurred vision, and congested left eye for the last three days. He had lost 20 pounds in two months and noticed low back pain.

Examination revealed visual acuity of 20/25 in the right eye and 20/40 in the left eye with correction. Refraction: OD = +1.25 ; OS = +0.75.

The right eye was normal with incipient nuclear senil cataract. The left eye was tender to palpation and showed market injection mainly circumcorneally. The pupillary reaction was impaired and the pupil was miotic and slightly distorted to the lateral side where a white, coliflower-like, mass occupied part of the angle of the anterior chamber, mostly the lateral upper quadrant. This mass was avascular, well circumscribed and adherent to the adjacent iris. The aqueous was turbid, three plus Tyndall, and there were small keratic precipitates on the posterior surface of the cornea, composed of lymphocytes. The iris itself was edematous with loss of normal luster. There was absence of posterior or anterior synechiae at gonioscopic examination. Ophthalmoscopic examination was not done at this time. The intraocular pressure was 12 mm Hg. in the right eye and 17 mm Hgm in the left eye. The diagnosis was acute anterior uveitis, secondary to local necrosis of metastatic tumor in the anterior chamber. Few days. after treatment with local 2.5% Hydrocortisone every 2 hours and Atropine 1%

Fig. 1. Photograph showing the tumor in the upper lateral quadrant.



gtts twice a day, the uveitis subsided and the ophthalmoscopic examination with indirect ophthalmoscope was done. No tumor mass were seen up to the ora serrata. Transillumination was negative except at the side of the tumor mass. The vitreous showed moderate Tyndall of inflammatory cells and the optic disc and the posterior pole were normal. The visual acuity improved to 20/25 c.c. and the intraocular pressure dropped to 12 mm Hg.

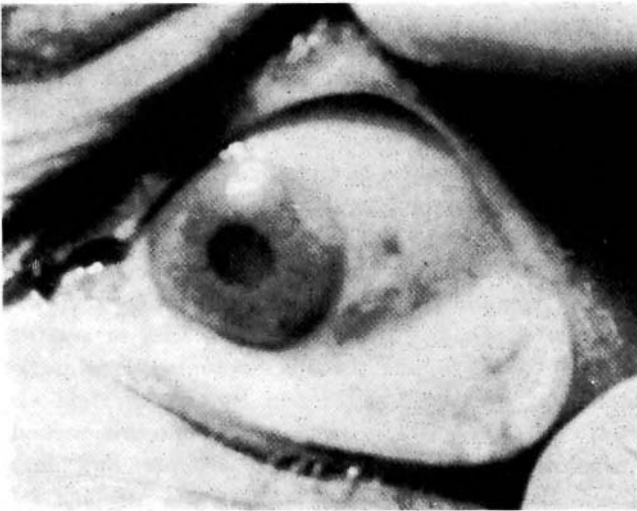


Fig. 2. Close view of the tumor mass.

#### METASTATIC TUMOR

General physical examination: The only positive findings were a nodule in the left lobe of the thyroid, hard, regular, non tender and mobile. There was a small, firm nodule in the left upper flank measuring  $1 \times 15$  cms. fixed to the skin. Rectal examination disclosed an enlarged but benign prostate to palpation.

Laboratory findings: The hemogram as well as the peripheral smear were normal. Bone marrow was also unremarkable. Chest films revealed a wide medias-

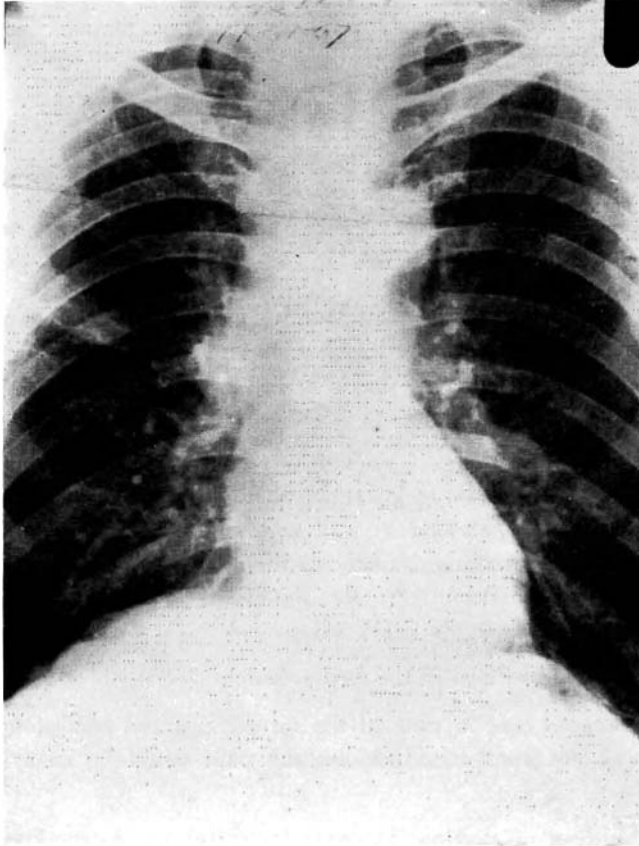
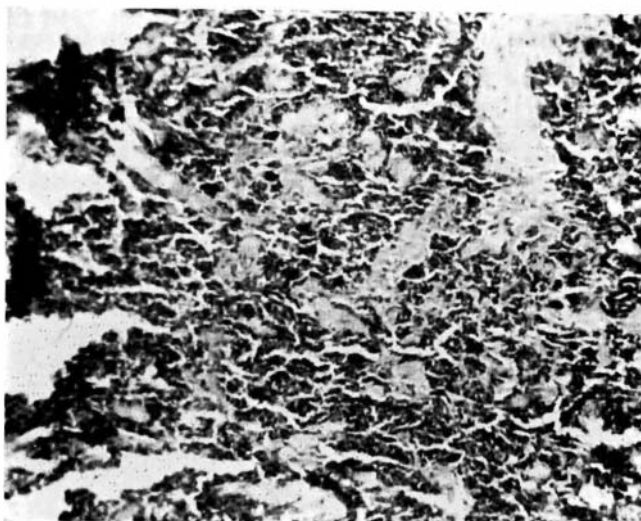


Fig. 3. X-ray of the chest. Wide mediastinum and prominent right hilum.

tinum with a nodule in the right hilum and a prominent aortic arch. Bronchoscopy and bronchograms were normal (there was no deformity of the main bronchi).

Biopsies were performed of the thyroid nodule and the abdominal wall nodule. Pathology reported nodular thyroid and in the abdominal wall nodule,

Fig. 4. Microscopic view of the abdominal nodule. Numerous atypic lymphocytes without any pattern of arrangement and a sarcomatous stroma.



many abnormal lymphocytes, with hyperchromatic nuclei, without arrangement and with a sarcomatous stroma. The diagnosis was lymphosarcoma, lymphocytic type. The patient was treated with Nitrogen Mustard, 0.2 mg  $\times$  Kg., divided in two dosis. The white blood count dropped to 3.000 but the drug was well tolerated.

Discussion: This is the case of a well demonstrated lymphocytic lymphosarcoma with metastasis to the left eye, abdominal wall and nodes. The probable mechanism of this anterior uvea metastasis is through the long ciliary arteries though typically they appear more frequently in the posterior choroid by way of the short posterior ciliary arteries.

The original tumor was probably located in the mediastinum.

We considered this an advanced case in view of the spread, age and condition of the patient. The eye was not enucleated because the pain could be easily controlled.

Nitrogen Mustard was the drug of election. In case of respiratory obstruction or hemoptysis, the mediastinum and the hilum of the right lung could be radiated.

Summary: This case showed that the eye is not infrequently the first site of malignant spread, and eye symptoms occasionally precede the diagnosis of the primary tumor.

*Univ. del Valle*